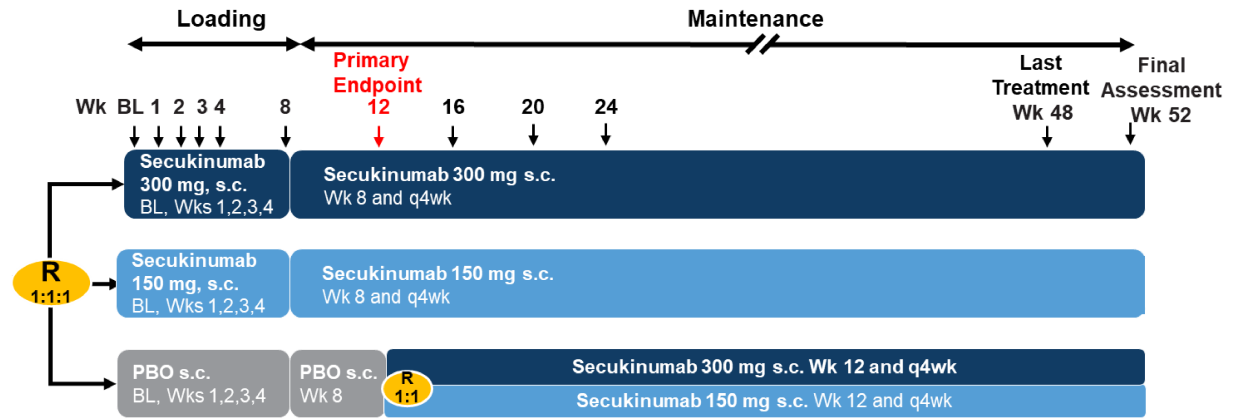
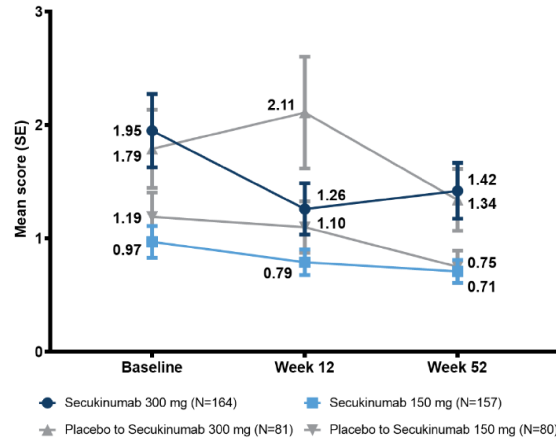
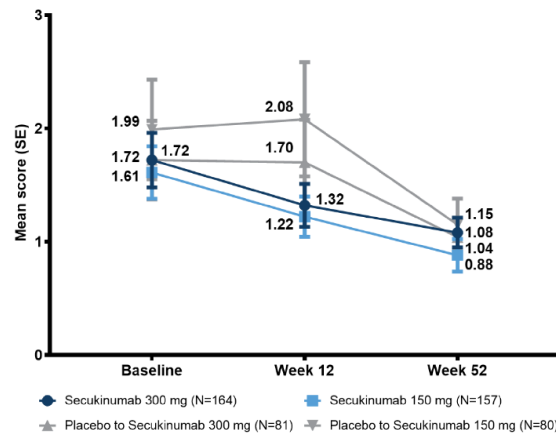


1 **Supplementary Material**2 **Supplementary figure S1. Study design**

3

4 BL, Baseline; PBO, placebo; q4wk, every 4 weeks; R, randomisation; s.c., subcutaneous; Wk,

5 week

6 **Supplementary figure S2. Total Berlin MRI score for the Entire Spine and SI Joints****Entire Spine****Sacroiliac Joints**7 **MRI, magnetic resonance imaging; SI, sacroiliac**

Number of evaluable patients		Secukinumab 300 mg	Secukinumab 150 mg	Placebo to Secukinumab 300 mg	Placebo to Secukinumab 150 mg
Entire Spine	Baseline	150	144	73	72
	Week 12	125	113	56	56
	Week 52	130	132	70	65
Sacroiliac Joints	Baseline	151	142	73	71
	Week 12	119	113	56	56
	Week 52	130	132	70	65

8 **Supplementary table S1. Axial Psoriatic Arthritis History – Baseline X-Ray data**

9

Variables	Secukinumab 300 mg s.c. (N = 167)	Secukinumab 150 mg s.c. (N = 165)	Placebo (N = 166)
Time since last X-ray of SIJ (months), mean (SD)	1.6 (2.97)	1.9 (2.53)	1.3 (1.87)
Grade of X-ray: Sacroiliitis on left side, n (%)^			
Grade 0	41 (34.2)	41 (33.9)	34 (30.9)
Grade 1-4	76 (63.3)	77 (63.6)	72 (65.5)
Missing	3 (2.5)	3 (2.5)	4 (3.6)
Grade of X-ray: Sacroiliitis on right side, n (%)^			
Grade 0	41 (34.2)	37 (30.6)	32 (29.1)
Grade 1-4	76 (63.3)	81 (66.9)	74 (67.3)
Missing	3 (2.5)	3 (2.5)	4 (3.6)
As reported by investigator based on available data at baseline for X-ray (Secukinumab 300 mg [n=120], 150 mg [n=121], and Placebo [n=110])			

10

11 **Supplementary Table S2. Correlation between Berlin MRI Score and ASAS 20/40 and**
 12 **BASDAI50 Response**

	Secukinumab 300 mg s.c. (N = 164)	Secukinumab 150 mg s.c (N = 157)	Placebo (N = 164)
ASAS20			
Responder (n/m)	Positive (58/90) Negative (37/60)	Positive (51/73) Negative (45/68)	Positive (26/96) Negative (14/51)
Odds ratio (95% CI)	1.1 (0.57, 2.22)	1.2 (0.58, 2.41)	1.0 (0.46, 2.10)
P-value	0.7295	0.6390	0.9619
ASAS40			
Responder (n/m)	Positive (38/90) Negative (31/60)	Positive (33/73) Negative (24/68)	Positive (11/96) Negative (6/51)
Odds ratio (95% CI)	0.7 (0.35, 1.32)	1.5 (0.77, 2.98)	1.0 (0.34, 2.80)
P-value	0.2564	0.2317	0.9558
BASDAI50			
Responder (n/m)	Positive (37/90) Negative (22/60)	Positive (27/73) Negative (21/69)	Positive (6/96) Negative (7/52)
Odds ratio (95% CI)	1.2 (0.62, 2.36)	1.3 (0.67, 2.70)	0.4 (0.14, 1.35)
P-value	0.5853	0.4100	0.1479
Odds Ratio, 95% CI and <i>P</i> -value for the comparison of positive and negative baseline Berlin MRI subgroups, for ASAS 20/40 and BASDAI50 response at Week 12. Missing observations were imputed using Last Observation Carried Forward (LOCF). N: number of patients in full analysis set in each treatment group; n: number of responders at Week 12 with corresponding Berlin MRI status at baseline; m: number of patients with positive/negative baseline Berlin MRI status.			

13

14 **Study dose administration**

15 Patients were required to self-administer secukinumab 300 mg (2 × 150 mg pre-filled syringe
16 [PFS]) or secukinumab 150 mg (1 × 150 mg PFS and 1 × placebo PFS) or placebo (2 × placebo
17 PFS) by s.c. injection of 1 mL each. The dosing frequency was either weekly or every 4 weeks in
18 accordance with the administration schedule described above. The last dose administration
19 occurred at Week 48.

20 **Magnetic Resonance Imaging**

21 Magnetic Resonance Imaging (MRI) of the spine and sacroiliac (SI) joints was implemented
22 using a standardized scanning procedure monitored by a central imaging service company to
23 minimize differences among MRI scanners at different imaging centres. The spine coil was used
24 for spine image acquisition and spinal coil in conjunction with the body/torso coil was used for
25 imaging of the SI joints. Depending on the specifics of the MRI scanner at each participating
26 MRI facility (1.5 T or 3 T), either two or three segment spine coverage as described below was
27 implemented:

28 MRI Protocol with Two-Segment Spine Coverage: 3-Plane Localizer(s), Sagittal 2D T1-w FSE
29 and Sagittal 2D STIR for upper and lower spine and 3-Plane Localizer(s), Oblique Coronal 2D
30 T1-w FSE and Oblique Coronal 2D STIR for SI joint

31 MRI Protocol with Three-Segment Spine Coverage: 3-Plane Localizer(s), Sagittal 2D T1-w FSE
32 and Sagittal 2D STIR for upper, MID and lower spine and 3-Plane Localizer(s), Oblique Coronal
33 2D T1-w FSE and Oblique Coronal 2D STIR for SI joint

34 Spine images were acquired in two overlapping segments (FOV-s) to achieve complete sagittal
35 coverage of the spine (from C1 to S1). For SI joints, 3-plane localizers were acquired to have a
36 true mid-sagittal slice showing the entire sacrum, based on which the centre of the joint space
37 between S1 and S2 vertebral bodies was identified and 18 slices were prescribed in oblique
38 coronal orientation.

39 **Protocol Deviations**

40 In treatment period 1 (up to week 12), a total 24/167 (14.4%), 25/165 (15.2%) and 31/166
41 (18.7%) patients had at least one protocol deviation in the secukinumab 300 mg, 150 mg and
42 placebo groups, respectively. A total of 116/498 (23.3%) of patients had at least one protocol
43 deviation over the entire duration of the study. The most common reasons for protocol deviation
44 were use of prohibited concomitant medication, not meeting inclusion criteria and treatment
45 deviations.

46 **Protocol Amendments**

47 The study protocol was amended once. Amendment 1 (dated 20-Jun-2016) was issued before the
48 first patient had been screened. The main purpose of the protocol amendment was to remove the
49 X-ray assessment of the spine and the related exploratory endpoint of reduction in the PsA
50 spondylitis radiology index score at week 52. Initially, it was planned to follow the structural
51 spine changes in patients with axial PsA during a period of 1 year followed potentially by a 2-
52 year duration in a separate extension trial. It was decided not to perform the X-ray assessments in
53 order to reduce the complexity of the study and to focus on the existing primary and secondary
54 objectives. Additionally, corrections of typographical errors, formatting errors and editorial
55 changes were performed to increase clarity and consistency of the text.