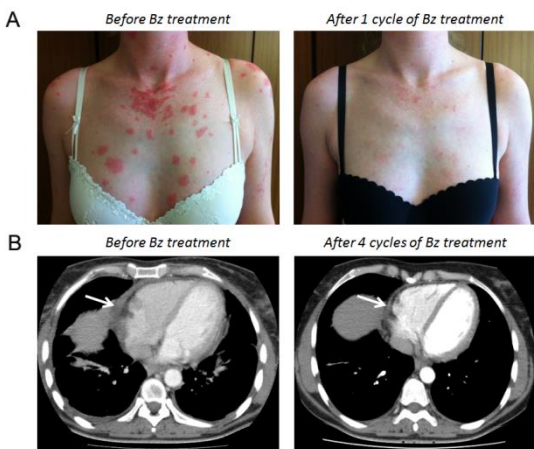
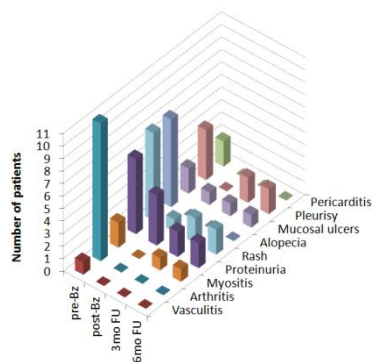


Online Supp. Figure 1: Marked improvement of skin manifestations and regression of pericardial effusions upon bortezomib treatment.

(A) Skin manifestations in one SLE patient (BE#6) before and after one cycle of bortezomib. With permission of the patient. **(B)** Computed tomography (CT) scans in one SLE patient (BE#3) demonstrating pericardial effusion (arrow) at baseline before, and after four cycles of bortezomib treatment.



Online Supp. Figure 2: Details of improvement in SLE manifestations upon bortezomib treatment. Based on individual SLEDAI scoring, number of patients displaying respective items are depicted at baseline before (pre-Bz), after the last bortezomib cycle (post Bz) and 3 months (3mo FU) and 6 months (6mo FU) following the last bortezomib cycle.



Online Supp. Figure 3: Reduction of serum antibodies directed against extractable antinuclear antigens (ENA) upon bortezomib treatment. Serum autoantibodies directed against nucleosomes, C1q and extractable nuclear antigens (ENAs), such as anti-Sm, anti-RNP/Sm and anti-Ro/SSA were analysed with ELISA (EUROIMMUN, Germany) in SLE patients (n=8) at baseline and during follow-up after bortezomib treatment (cut-off < 20 RE/ml for all antibody concentrations).

