

Supplemental Material

1 **Low uveitis rates in patients with axial spondyloarthritis**
2 **treated with bimekizumab: pooled results from phase**
3 **2b/3 trials**

4

5 Matthew A. Brown,^{1,2*} Martin Rudwaleit,^{3*} Floris A. van Gaalen,⁴ Nigil
6 Haroon,⁵ Lianne S. Gensler,⁶ Carmen Fleurinck,⁷ Alexander Marten,⁸ Ute
7 Massow,⁸ Natasha de Peyrecave,⁷ Thomas Vaux,⁹ Katy White,⁹ Atul
8 Deodhar,¹⁰ Irene E. van der Horst-Bruinsma¹¹

9

10 *MAB and MR are joint first authors and contributed equally.

11 ¹Genomics England, London, UK; ²Department of Medical and Molecular Genetics,

12 Faculty of Life Sciences and Medicine, King's College London, London, UK;

13 ³University of Bielefeld, Klinikum Bielefeld, Bielefeld, Germany; ⁴Leiden University

14 Medical Center, Department of Rheumatology, Leiden, The Netherlands; ⁵University

15 of Toronto, University Health Network, Schroeder Arthritis Institute, Department of

16 Medicine/Rheumatology, Toronto, Ontario, Canada; ⁶University of California, San

17 Francisco, Department of Medicine/Rheumatology, San Francisco, California, USA;

18 ⁷UCB Pharma, Brussels, Belgium; ⁸UCB Pharma, Monheim am Rhein, Germany; ⁹UCB

19 Pharma, Slough, UK; ¹⁰Oregon Health & Science University, Division of Arthritis &

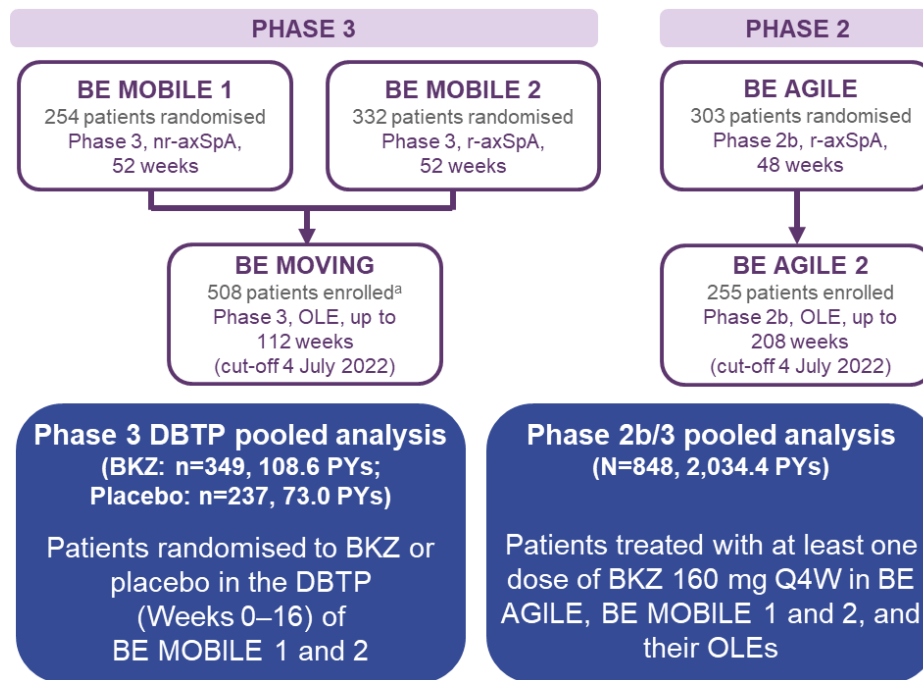
20 Rheumatic Diseases, Portland, Oregon, USA; ¹¹Radboud University Medical Centre,

21 Department of Rheumatology, Nijmegen, The Netherlands

22 **Correspondence to:** Matthew A. Brown (Genomics England, London, UK;

23 matt.brown@genomicsengland.co.uk)

Supplemental Material

1 **SUPPLEMENTARY DATA**2 **Figure S1. Pooling of data from the phase 3 BE MOBILE 1 and 2 and phase**3 **2 BE AGILE trials**

4

5 ^aTrial ongoing. BKZ: bimekizumab; DBTP: double-blind treatment period; nr-axSpA: non-radiographic
6 axial spondyloarthritis; OLE: open-label extension; PYs: patient-years; Q4W: every four weeks; r-axSpA:
7 radiographic axial spondyloarthritis.