

Rituximab for granulomatosis with polyangiitis in the pandemic of covid-19: lessons from a case with severe pneumonia

In the pandemic of severe acute respiratory syndrome coronavirus 2 (SARS-CoV-2) disease 2019 (covid-19),^{1,2} the preliminary experience reported by Monti S and colleagues³ suggests that patients with chronic arthritis (rheumatoid arthritis and spondyloarthritis) receiving bDMARDs (biologic disease-modifying anti-rheumatic drugs) or tsDMARDs (targeted synthetic DMARDs) may not exhibit an increased risk of severe covid-19. These data must be strengthened and confirmed at a larger scale, but remain positive in this drastic context. The authors rightly recommend a continuous surveillance of patients under immunosuppressants, especially since data are lacking in many systemic autoimmune/inflammatory diseases. Notably, anti-neutrophil cytoplasmic antibodies (ANCA)-associated vasculitis (AAV) is a group of vasculitides that can involve the respiratory tract (upper and lower airways) and the recent outbreak of covid-19 raises many specific questions concerning the severity of viral infection in AAV patients as well as the therapy with rituximab. Indeed, rituximab, a monoclonal antibody targeting CD20, has become the cornerstone of treatment in the last decade, but is responsible for long-lasting B-cell depletion and potentially severe infectious events (IE) independently from covid-19.⁴ A recent observation from our centre illustrates some specific issues with this drug.

A 52-year-old woman was followed for granulomatosis with polyangiitis since 1988 (ear, nose and throat (ENT), orbital, lung, joint and skin involvements, proteinase3 (PR3)-ANCA). She previously received cyclophosphamide (total cumulated dose=41 gr), anti-tumour-necrosis factor agents, mycophenolate mofetil, methotrexate, leflunomide, rituximab and glucocorticoids. Her main comorbidities were overweight (body mass index: 27.05 kg/m²) and hypertension treated with nebivolol. In September 2019, the vasculitis relapsed (arthralgias, ENT, intermittent haematuria and increased PR3-ANCA levels). Four infusions of rituximab (375 mg/m²) were weekly administered in October 2019. The patient improved, and a maintenance therapy with rituximab (500 mg) was administered on 5th March 2020, while she was still under prednisone 15 mg daily. On 6th March 2020 (Day #0), the patient had headaches and myalgias, followed by a 39°C fever and non-productive cough. She was admitted on Day #4 and covid-19 was diagnosed by reverse transcription (RT)-PCR from nasopharyngeal swab specimens. Typical bilateral interstitial pneumonia related to covid-19 was demonstrated on CT scan (figure 1). Other concomitant infections (including pneumocystosis) were excluded. While she remained highly febrile under broad-spectrum antibiotics, the oxygen requirement increased progressively and she presented sudden respiratory failure on Day #18, requiring endotracheal intubation and mechanical ventilation for acute respiratory distress syndrome. Several drugs were given for compassionate use: lopinavir/ritonavir for 3 days from Day #12 and then hydroxychloroquine (200 mg/8 hour) for 10 days from Day #19. The clinical condition improved rapidly, and the patient was extubated (Day #20) and oxygen support was withdrawn (Day #25). Nasopharyngeal RT-PCR were negative twice in the following days and the patient returned home on Day #29.

Until today, immunosuppressive drugs are supposed to be risk factors of severe forms of covid-19. Furthermore, although risk factors are not yet clearly established,⁵ our patient had two potential additional ones (overweight and hypertension),

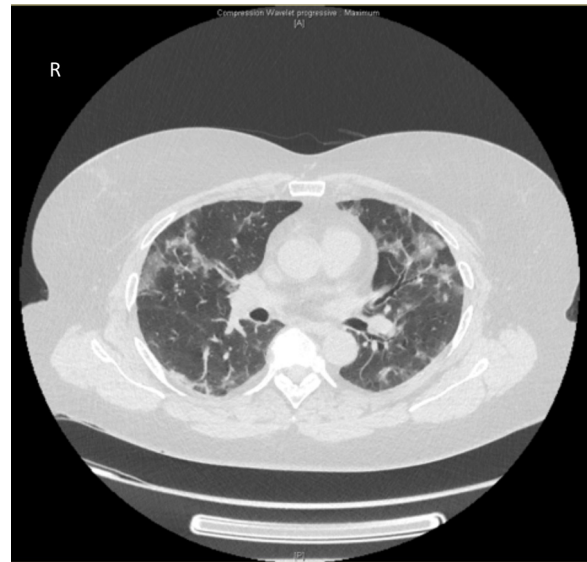



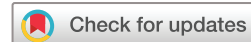Figure 1 CT scan disclosing ground glass opacities and condensations consistent with a mixed (central and subpleural) pattern of severe covid-19 pneumonia.

making her recovery unexpected. We report herein a severe and life-threatening form of covid-19 in a patient under immunosuppressant, though the worsening occurred more progressively than observed in most series. Both glucocorticoids and rituximab may have limited the cytokine storm and delayed the worsening and need for mechanical ventilation, as compared with previous reports.² However, as proposed by Monti and colleagues,³ we should consider these drugs with caution during the covid-19 pandemic.

Independently from covid-19, infectious events (IE) (mainly pyogenic) may occur in the 3 months following rituximab infusion. Classically, risk factors for infection in patients receiving rituximab include glucocorticoids, other immunosuppressive drugs, diabetes mellitus and age. We previously reported that severe IE were observed in about 25% of patients with autoimmune diseases, and some individuals experienced life-threatening, polymicrobial and opportunistic infections.⁴ This frequency was higher than in other studies,^{6,7} but this suggests that rituximab may not be as safe as usually supposed, probably depending on the subgroups of treated patients. During covid-19, which may generate an immunocompromised status (as illustrated by lymphopenia and opportunistic infections), the impact of rituximab treatment on IE remains to be clarified. Additionally, the B-cell depletion induced by rituximab reduces the immunogenicity of several vaccines, which encourages to perform vaccination before starting rituximab.⁸ Similarly, the immunological memory following SARS-CoV-2 infection will probably be impaired by this biologic, making patients sensitive to a reinfection.

Although we cannot draw any definitive conclusion from our observation, we agree with those who recommend avoiding withdrawal of drugs, because this may lead to relapses of inflammatory diseases. Nevertheless, the specific and long-lasting effects of rituximab make this issue even more delicate and warrant further studies concerning the impact of covid-19 in immunocompromised patients.

Philippe Guilpain,^{1,2} Clément Le Bihan,³ Vincent Foulongne,⁴ Patrice Taourel,⁵ Nathalie Pansu,³ Alexandre Thibault Jacques MARIA ,^{1,2} Boris Jung,^{6,7} Romaric Larcher,^{6,7} Kada Klouche,^{6,7} Vincent Le Moing³



¹Internal Medicine: Multi-Organic Diseases, Local Referral Center for systemic autoimmune diseases, Saint Eloi Hospital, Univ Montpellier, Medical School, Montpellier University Hospital, Montpellier cedex 5, France

²Univ Montpellier, IRMB, Univ Montpellier, INSERM, Montpellier, France

³Tropical and Infectious Diseases, Saint Eloi Hospital, Univ Montpellier, Medical School, Montpellier University Hospital, Montpellier cedex 5, France

⁴Pathogenesis and Control of Chronic Infections, Inserm, Université Montpellier 1 Faculté de Médecine Montpellier-Nîmes, Montpellier, Languedoc-Roussillon, France

⁵Osteoarticular Medical Imaging Section, Department of Medical Imaging, University Hospital Centre Montpellier, Montpellier, Languedoc-Roussillon, France

⁶Department of Intensive Care Medicine, Lapeyronie Hospital, Univ Montpellier, Medical School, Montpellier University Hospital, Montpellier, France

⁷Inserm, CNRS, PhyMedExp, Univ Montpellier, Montpellier, France

Correspondence to Dr Alexandre Thibault Jacques MARIA, Internal Medicine: Multi-Organic Diseases, Local Referral Center for systemic autoimmune diseases, Montpellier University Hospital, Univ Montpellier, Medical School, Montpellier cedex 5, France; a-maria@chu-montpellier.fr and Dr Philippe Guilpain, Internal Medicine: Multi-Organic Diseases, Local Referral Center for systemic autoimmune diseases, Montpellier University Hospital, Univ Montpellier, Medical School, Montpellier University Hospital, Montpellier, France; p-guilpain@chu-montpellier.fr

Contributors All authors have contributed to this manuscript and fulfil the requirements for authorship.

Funding The authors have not declared a specific grant for this research from any funding agency in the public, commercial or not-for-profit sectors.

Competing interests PG has been a medical expert for LFB (Laboratoire Français du Biofractionnement) and has received fees from Abbvie, Actelion, Boehringer Ingelheim France, Bouchara-Recordati, Novartis, Pfizer and Roche in the last 5 years. ATJM has received fees from Abbvie, Actelion, CSL Behring, Experf, Novartis and Shire and declares speaking fees from Astra-Zeneca and BMS in the last 5 years.

Patient and public involvement Patients and/or the public were not involved in the design, or conduct, or reporting or dissemination plans of this research.

Patient consent for publication Obtained.

Provenance and peer review Not commissioned; internally peer reviewed.

© Author(s) (or their employer(s)) 2020. No commercial re-use. See rights and permissions. Published by BMJ.

To cite Guilpain P, Le Bihan C, Foulongne V, *et al.* *Ann Rheum Dis* Epub ahead of print: [please include Day Month Year]. doi:10.1136/annrheumdis-2020-217549

Received 8 April 2020

Accepted 9 April 2020

Ann Rheum Dis 2020;**0**:1–2. doi:10.1136/annrheumdis-2020-217549

ORCID iD

Alexandre Thibault Jacques MARIA <http://orcid.org/0000-0002-0868-5804>

REFERENCES

- 1 Guan W-jie, Ni Z-yi, Hu Y, *et al.* Clinical characteristics of coronavirus disease 2019 in China. *N Engl J Med Overseas Ed.* doi:10.1056/NEJMoa2002032. [Epub ahead of print: 28 Feb 2020].
- 2 Bouadma L, Lescure F-X, Lucet J-C, *et al.* Severe SARS-CoV-2 infections: practical considerations and management strategy for intensivists. *Intensive Care Med* 2020;46:579–82.
- 3 Monti S, Balduzzi S, Delvino P, *et al.* Clinical course of COVID-19 in a series of patients with chronic arthritis treated with immunosuppressive targeted therapies. *Ann Rheum Dis* 2020. doi:10.1136/annrheumdis-2020-217424. [Epub ahead of print: 2 Apr 2020].
- 4 Tudesq J-J, Cartron G, Rivière S, *et al.* Clinical and microbiological characteristics of the infections in patients treated with rituximab for autoimmune and/or malignant hematological disorders. *Autoimmun Rev* 2018;17:115–24.
- 5 Jordan RE, Adab P, Cheng KK. Covid-19: risk factors for severe disease and death. *BMJ* 2020;368:m1198.
- 6 Tony H-P, Burmester G, Schulze-Koops H, *et al.* Safety and clinical outcomes of rituximab therapy in patients with different autoimmune diseases: experience from a national registry (GRAID). *Arthritis Res Ther* 2011;13:R75.
- 7 Marco H, Smith RM, Jones RB, *et al.* The effect of rituximab therapy on immunoglobulin levels in patients with multisystem autoimmune disease. *BMC Musculoskelet Disord* 2014;15:178.
- 8 Rondaan C, Furer V, Heijstek MW, *et al.* Efficacy, immunogenicity and safety of vaccination in adult patients with autoimmune inflammatory rheumatic diseases: a systematic literature review for the 2019 update of EULAR recommendations. *RMD Open* 2019;5:e001035.