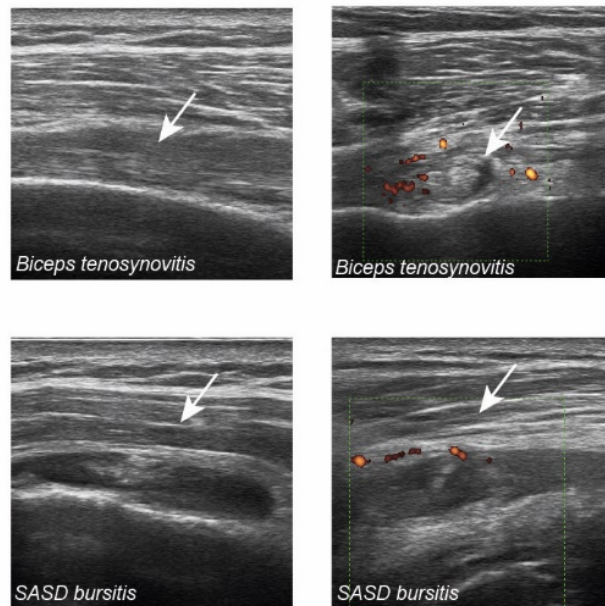
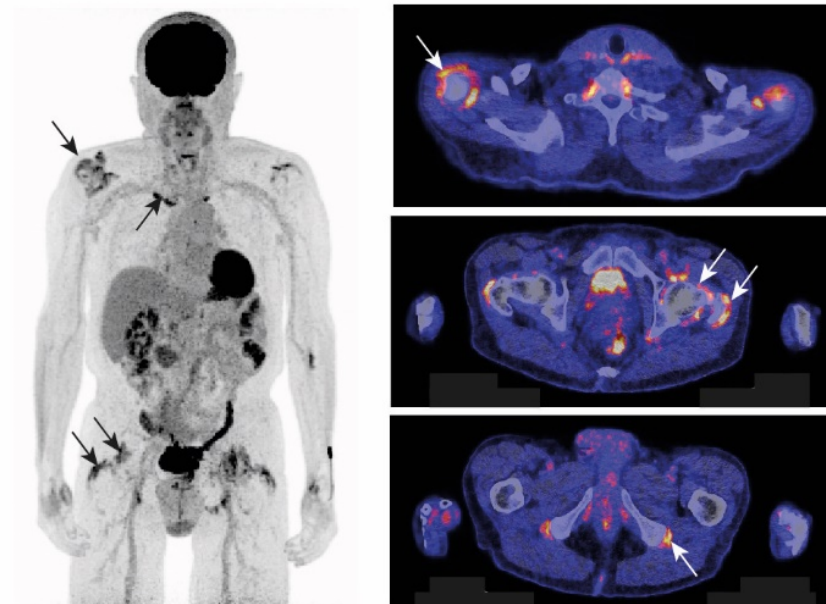


**Supplemental Table 1. Characteristics of patients with ICI-PMR.** Abbreviations: Adeno = adenocarcinoma. ANA = anti-nuclear antibodies (normal < 1:40 titre). ANCA = antineutrophil cytoplasmic antibodies. CCP = anti-CCP antibodies (normal 0-10 U/mL). CRP = C-reactive protein (normal < 5 mg/L). ENA = anti-extractable nuclear antigen antibodies (normal 0.0-1.0 ratio). ESR = erythrocyte sedimentation rate (normal < 30 mm/hr in females, < 20 mm/hr in males). ICI = immune checkpoint inhibitor. irAE = immune related adverse effect. Neg = negative. Renal cell = renal cell carcinoma. RF = rheumatoid factor (normal 0-5 IU/L). SASD = subacromial subdeltoid. Squamous = squamous cell carcinoma. Urothelial = urothelial cell carcinoma. US = ultrasound.

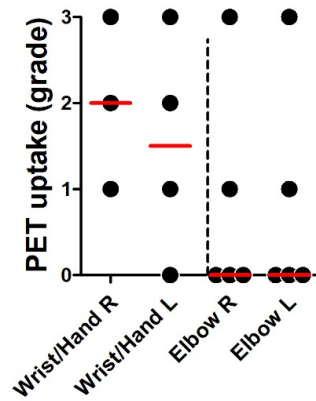
Characteristic	Patient 1	Patient 2	Patient 3	Patient 4	Patient 5	Patient 6
<i>Age and sex</i>	83, male	73, male	74, male	59, female	72, male	63, female
<i>Malignancy</i>	urothelial - bladder	squamous - lung	adeno - lung	adeno - lung	renal cell - kidney	adeno - lung
<i>ICI name</i>	pembrolizumab	nivolumab	pembrolizumab	pembrolizumab	nivolumab	nivolumab
<i>ICI response</i>	near-complete	near-complete	near-complete	partial	partial	partial
<i>Non-PMR irAE</i>	colitis	none	none	none	none	hypophysitis
<i>PMR onset, days since 1st ICI infusion</i>	63	77	1	84	86	28
<i>PMR diagnosis, days since 1st ICI infusion</i>	197	176	40	142	120	118
<i>Shoulder pain</i>	bilateral	bilateral	bilateral	bilateral	bilateral	bilateral
<i>Hip pain or limited range of motion</i>	bilateral	bilateral	bilateral	bilateral	unilateral	bilateral
<i>Neck or back pain</i>	present	absent	present	present	absent	absent
<i>Morning stiffness</i>	present	present	present	present	present	present
<i>CRP (mg/L) / ESR (mm/hr)</i>	1.9 / 38	2.1 / not done	45 / not done	7 / not done	33 / 34	51 / not done
<i>RF / CCP</i>	neg / neg	neg / neg	neg / neg	neg / neg	neg / neg	7.4 (U/L) / neg
<i>ANA / ENA</i>	neg / not done	1:40 / not done	neg	1:160 / neg	neg	1:320 / neg
<i>ANCA</i>	neg	neg	neg	neg	neg	neg
<i>US biceps tenosynovitis</i>	unilateral	unilateral	bilateral	absent	bilateral	bilateral
<i>US SASD bursitis</i>	absent	bilateral	unilateral	unilateral	absent	absent
<i>US glenohumeral synovitis</i>	absent	absent	absent	absent	absent	absent
<i>US hip synovitis</i>	not done	not done	not done	absent	absent	absent
<i>US trochanteric bursitis</i>	not done	not done	not done	absent	absent	absent

**Supplemental Figure 1. Imaging findings in patients with ICI-PMR.** Representative imaging findings in patients with ICI-PMR. (A) Biceps tenosynovitis (upper row) and subacromial subdeltoid (SASD) bursitis (lower row) on ultrasonography of patients with ICI-PMR. Ultrasound was performed with an Esaote MyLab Twice machine and LA435 probe (6-18 MHz). (B) Maximum intensity projection (MIP) of the PET scan (left panel) and FDG-PET/CT images (right panel) of a patient with ICI-PMR. Enhanced FDG uptake is visible at the shoulders, sternoclavicular joints, hip joints, greater trochanters, and ischial tuberosities. The FDG-PET/CT scan was performed with a Biograph mCT (Siemens Medical Systems). After fasting for at least 6 hours, patients received a weight-based injection of intravenous FDG (3 MBq/kg). The PET emission scan was performed 60 minutes after tracer administration. A low-dose CT scan was performed immediately before the PET scan, and was used for attenuation correction and anatomic location of the PET.

**A****B**

**Supplemental Figure 2. Grading of PET uptake at additional sites in patients with ICI-PMR.** PET uptake was graded at the wrists/hands (n=4) and elbows (n=5). Grading was performed as previously described [9]: 0, no uptake; 1, uptake lower than liver; 2 uptake equal to liver; 3, uptake higher than liver.

### At diagnosis ICI-PMR



**Supplemental Figure 3. Maximum intensity projection (MIP) of the PET scan at diagnosis of ICI-PMR and prior to initiation of ICI therapy.**

