

## Correspondence on 'Points to consider for the treatment of immune-mediated inflammatory diseases with Janus kinase inhibitors: a consensus statement'

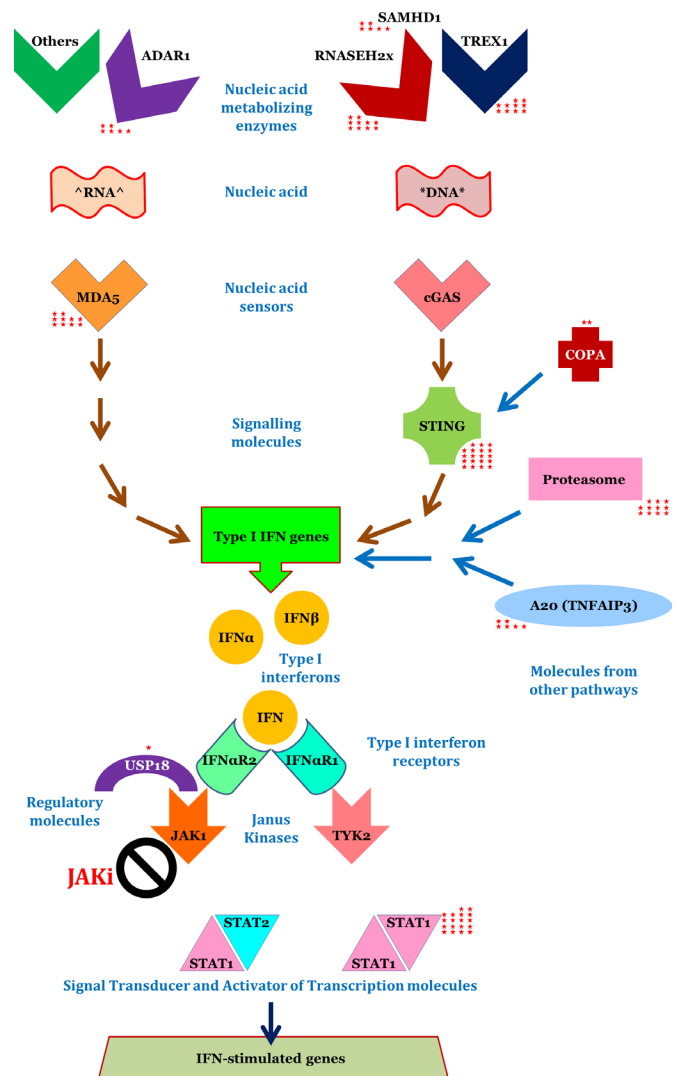
We read with interest the recent article by Nash *et al*, wherein authors have exhaustively reviewed the role of Janus kinase inhibitors (JAKis) in several inflammatory and autoimmune diseases.<sup>1</sup> These drugs have also emerged as an important therapeutic option for several monogenic type I interferonopathies—inborn errors of immunity (IEIs) characterised by abnormal activation of type I interferon pathway (figure 1). In this context, the authors have referred to reference number 43; however, the said reference does not cover this aspect in detail.<sup>12</sup> We briefly review the efficacy, safety and dosing of JAKis in monogenic interferonopathies—a distinctive group of disorders that often present in children wherein data on safety, efficacy and appropriate dosing of JAKis are limited.<sup>3</sup>

Systemic inflammation and skin lesions in patients with stimulator of interferon genes (STING)-associated vasculopathy of infancy (SAVI) have been shown to respond to ruxolitinib therapy (maximum weight-based dose of 1.25 mg/kg/day (young children)),<sup>3–9</sup> often with improvement in lung inflammation and stabilisation of lung fibrosis.<sup>4–6</sup> Severe viral infections, BK viraemia and intracranial hypertension have been the reported adverse events.<sup>4</sup> Baricitinib has also been found to be beneficial in the stabilisation of lung fibrosis (with improvement of lung functions), with marked improvement in skin disease and near-normalisation of interferon signature (maximum doses used: 4 mg/day (<20 kg), 6 mg/day (20–40 kg) or 10 mg/day (>40 kg)). During a mean treatment duration of 2¼ years, infections (pneumonia, osteomyelitis and BK viraemia) were the most important adverse events.<sup>7</sup> Baricitinib has been found to be useful in a child who did not initially respond to ruxolitinib.<sup>8</sup> In a recent report describing the largest cohort of SAVI, two out of eight patients treated with ruxolitinib needed to be switched over to tofacitinib or baricitinib because of adverse events.<sup>6</sup> Tofacitinib has also been shown to improve interferon signature in SAVI; however, data on long-term clinical efficacy and safety are limited.<sup>9</sup>

Baricitinib has been used for the treatment of proteasome-associated autoinflammatory syndrome (dosing similar to SAVI). Steroids were tapered in most patients and complete response was noted in approximately half.<sup>7</sup> After a mean treatment duration of 3.6 years, the most notable adverse events were severe infections (herpes zoster, BK viraemia, pneumonia, influenza, *Hemophilus* bacteraemia and *Clostridium difficile* colitis). Baricitinib therapy was discontinued in one patient with a suspicion of BK virus nephropathy.<sup>7</sup> Improvement in joint contractures, resolution of organomegaly, lymphadenopathy and hyperinflammation has been reported in one patient with a novel mutation in proteasome assembly gene *PSMG2*.<sup>10</sup>

Baricitinib (6 mg/day) and ruxolitinib (30 mg/day) have been used in two adolescent girls with coatmer subunit alpha (COPA) syndrome with joint and lung predominant disease, respectively.<sup>11 12</sup> Significant clinical improvement was noted within 2 months of therapy; however, near-normalisation of interferon signature took ~1 year. Stabilisation of restrictive lung disease was noted in both.<sup>11 12</sup>

Patients with *TREX1* deficiency manifesting as chilblain lupus with arthritis have been reported to respond to ruxolitinib (maximum 15 mg/day) and baricitinib.<sup>13 14</sup> Ruxolitinib (maximum 20 mg/day)



**Figure 1** Schematic representation of the type I IFN pathway. Monogenic interferonopathies where JAKis have been used are marked by red stars. The number of red stars indicates the approximate number of patients (to date) treated with JAKis. IFN, interferon; JAKi, Janus kinase inhibitor.

has also been used successfully in few children with *MDA5* (*IFIH1*) gain-of-function (GOF) mutations with improvement in neurological manifestations, fever and interferon score. No significant adverse events were reported during follow-up of 2.5 years.<sup>15 16</sup> Recently, Vanderver *et al*<sup>17</sup> reported treatment with baricitinib in a large cohort of patients with Aicardi-Goutières syndrome (gene defects (number of patients)—*IFIH1* (8) *RNASEH2B* (8) *TREX1* (6) *ADAR1* (6) *SAMHD1* (5) *RNASEH2A* (1) and *RNASEH2C* (1)). Reduction in interferon scores was noted in the majority and significant improvement in the skin disease was seen in approximately half. One-third of the cohort attained >1 new milestone, with better results being noted at higher doses. During a mean treatment duration of ~1.5 years, adverse events (BK viraemia, anaemia and thrombocytosis) led to dose decrement in one-tenth of the cohort.<sup>17</sup>

Patients with treatment-refractory A20 haploinsufficiency have been shown to have elevated type I interferon signature. Therapy with tofacitinib (5–10 mg/day) or baricitinib has resulted in improvement of clinical, radiological and laboratory parameters in these patients. No significant adverse effects were noted during follow-up of 2 years.<sup>18 19</sup> Promising results have been noted with JAKi therapy in several patients with signal transducer and activator

of transcription 1 (STAT1) GOF—an IEI characterised by chronic mucocutaneous candidiasis, autoimmunity and elevated type I interferon signature.<sup>20</sup> Forbes *et al* used ruxolitinib (maximum dose 40 mg/day (adults)) for management of treatment-refractory autoimmune manifestations, including cytopenia, hepatitis, lupus-like manifestations and enteropathy in 11 patients with STAT1 GOF. During 4–34 months of JAKi therapy, improvement was noted in ~80%. The adverse events reported were herpes zoster (requiring antiviral drugs and temporary cessation of ruxolitinib), mild pancreatitis and mild cytopenia.<sup>21</sup> Recently, baricitinib (maximum 20 mg/day) has been reported to result in improvement of pulmonary, cutaneous and neurological manifestations in a young child with USP18 deficiency.<sup>22</sup>

To conclude, JAKis have emerged as targeted therapy for several monogenic type I interferonopathies, though the data are still not plenitude.

**Aaqib Zaffar Banday** , **Ankur Kumar Jindal**, **Surjit Singh**

Allergy Immunology Unit, Department of Pediatrics, Post Graduate Institute of Medical Education and Research, Chandigarh, India

**Correspondence to** Dr Ankur Kumar Jindal, Allergy Immunology Unit, Department of Pediatrics, Post Graduate Institute of Medical Education and Research, Chandigarh, India; ankurjindal11@gmail.com

**Contributors** AZB: writing of the initial draft of the manuscript, review of literature, editing and revision of the manuscript at all stages of its production and final approval. AKJ: inception of idea, evaluation and critical revision of the manuscript at all stages of production and final approval. SS: critical revision of the manuscript at all stages of production and final approval.

**Funding** The authors have not declared a specific grant for this research from any funding agency in the public, commercial or not-for-profit sectors.

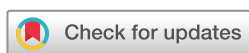**Competing interests** None declared.

**Patient and public involvement** Patients and/or the public were not involved in the design, or conduct, or reporting, or dissemination plans of this research.

**Patient consent for publication** Not required.

**Provenance and peer review** Not commissioned; internally peer reviewed.

© Author(s) (or their employer(s)) 2023. No commercial re-use. See rights and permissions. Published by BMJ.



**To cite** Banday AZ, Jindal AK, Singh S. *Ann Rheum Dis* 2023;**82**:e104.

Received 12 January 2021

Accepted 15 January 2021

Published Online First 4 March 2021



► <http://dx.doi.org/10.1136/annrheumdis-2021-219919>

*Ann Rheum Dis* 2023;**82**:e104. doi:10.1136/annrheumdis-2021-219890

#### ORCID iD

Aaqib Zaffar Banday <http://orcid.org/0000-0001-5486-4267>

#### REFERENCES

- Nash P, Kerschbaumer A, Dörner T, *et al*. Points to consider for the treatment of immune-mediated inflammatory diseases with Janus kinase inhibitors: a consensus statement. *Ann Rheum Dis* 2021;**80**:71–87.
- Kerschbaumer A, Smolen JS, Nash P, *et al*. Points to consider for the treatment of immune-mediated inflammatory diseases with Janus kinase inhibitors: a systematic literature research. *RMD Open* 2020;**6**:e001374.
- Kim H, Brooks KM, Tang CC, *et al*. Pharmacokinetics, pharmacodynamics, and proposed dosing of the oral JAK1 and JAK2 inhibitor Baricitinib in pediatric and young adult celiac and SAVI patients. *Clin Pharmacol Ther* 2018;**104**:364–73.
- Volpi S, Insalaco A, Caorsi R, *et al*. Efficacy and adverse events during Janus kinase inhibitor treatment of SAVI syndrome. *J Clin Immunol* 2019;**39**:476–85.
- Frémont M-L, Rodero MP, Jeremiah N, *et al*. Efficacy of the Janus kinase 1/2 inhibitor ruxolitinib in the treatment of vasculopathy associated with *TMEM173*-activating mutations in 3 children. *J Allergy Clin Immunol* 2016;**138**:1752–5.
- Frémont M-L, Hadchouel A, Berteloot L, *et al*. Overview of STING-Associated vasculopathy with onset in infancy (SAVI) among 21 patients. *J Allergy Clin Immunol Pract* 2020;**3**:1226–5 (Epub ahead of print: 2020 Nov 18).
- Sanchez GAM, Reinhardt A, Ramsey S, *et al*. JAK1/2 inhibition with baricitinib in the treatment of autoinflammatory interferonopathies. *J Clin Invest* 2018;**128**:3041–52.
- Balci S, Ekinci RMK, de Jesus AA, *et al*. Baricitinib experience on STING-associated vasculopathy with onset in infancy: a representative case from turkey. *Clin Immunol* 2020;**212**:108273.
- König N, Fiehn C, Wolf C, *et al*. Familial chilblain lupus due to a gain-of-function mutation in *sting*. *Ann Rheum Dis* 2017;**76**:468–72.
- de Jesus AA, Brehm A, VanTries R, *et al*. Novel proteasome assembly chaperone mutations in *PSMG2/PAC2* cause the autoinflammatory interferonopathy CANDLE/PRAAS4. *J Allergy Clin Immunol* 2019;**143**:1939–43.
- Krutzke S, Rietschel C, Horneff G. Baricitinib in therapy of CopA syndrome in a 15-year-old girl. *Eur J Rheumatol* 2019;**7**:1–4.
- Frémont M-L, Legendre M, Fayon M, *et al*. Use of ruxolitinib in CopA syndrome manifesting as life-threatening alveolar haemorrhage. *Thorax* 2020;**75**:92–5.
- Briand C, Frémont M-L, Bessis D, *et al*. Efficacy of JAK1/2 inhibition in the treatment of chilblain lupus due to *TREX1* deficiency. *Ann Rheum Dis* 2019;**78**:431–3.
- Zimmermann N, Wolf C, Schwenke R, *et al*. Assessment of Clinical Response to Janus Kinase Inhibition in Patients With Familial Chilblain Lupus and *TREX1* Mutation. *JAMA Dermatol* 2019;**155**:342–6.
- Kothur K, Bandodkar S, Chu S, *et al*. An open-label trial of JAK 1/2 blockade in progressive *IFIH1*-associated neuroinflammation. *Neurology* 2018;**90**:289–91.
- McLellan KE, Martin N, Davidson JE, *et al*. Jak 1/2 blockade in MDA5 gain-of-function. *J Clin Immunol* 2018;**38**:844–6.
- Vanderver A, Adang L, Gavazzi F, *et al*. Janus kinase inhibition in the Aicardi-Goutières syndrome. *N Engl J Med* 2020;**383**:986–9.
- Schwartz DM, Blackstone SA, Sampaio-Moura N, *et al*. Type I interferon signature predicts response to JAK inhibition in haploinsufficiency of *A20*. *Ann Rheum Dis* 2020;**79**:429–31.
- Mulhern CM, Hong Y, Omyoinmi E, *et al*. Janus kinase 1/2 inhibition for the treatment of autoinflammation associated with heterozygous *TNFAIP3* mutation. *J Allergy Clin Immunol* 2019;**144**:863–6.
- Okada S, Asano T, Moriya K, *et al*. Human STAT1 gain-of-function heterozygous mutations: chronic mucocutaneous candidiasis and type I Interferonopathy. *J Clin Immunol* 2020;**40**:1065–81.
- Forbes LR, Vogel TP, Cooper MA, *et al*. Jakinibs for the treatment of immune dysregulation in patients with gain-of-function signal transducer and activator of transcription 1 (*STAT1*) or *STAT3* mutations. *J Allergy Clin Immunol* 2018;**142**:1665–9.
- Alshime F, Martin-Fernandez M, Tamsah M-H, *et al*. Jak inhibitor therapy in a child with inherited USP18 deficiency. *N Engl J Med* 2020;**382**:256–65.