

Ultrasonographic damages of major salivary glands are associated with cryoglobulinemic vasculitis and lymphoma in primary Sjogren's syndrome: are the ultrasonographic features of the salivary glands new prognostic markers in Sjogren's syndrome?

We read with great interest the new ultrasound scoring system of salivary glands for primary Sjogren's syndrome (pSS) developed by Outcome Measures in Rheumatology (OMERACT) and recently reported by Jousse-Joulin *et al.*¹ The salivary gland ultrasound (SGUS) is a simple, non-irradiating, non-expensive and accessible assessment tool. Several previous SGUS scoring systems have been proposed so far, but not all of them take into account every pathological features, especially in the parotid gland (such as hyperechoic bands) for the diagnosis of pSS. The lack of consensus between each of these SGUS scoring systems also had a negative impact on the reproducibility of the examination so far. By offering an updated consensual classification, the OMERACT initiative therefore constitutes an undeniable progress for the diagnosis of pSS.

Recently, in a multicentre prospective study of 97 patients referred for clinical sicca syndrome (39 pSS and 22 secondary Sjogren's syndrome (sSS) according to American-European Consensus Group (AECG) criteria in comparison with 36 controls), we reported good performances of various SGUS scoring systems for the diagnosis of pSS or sSS (area under the curve between 0.885–0.915 (pSS) and 0.808–0.851 (sSS) according to the used ultrasound scores, respectively).² After the diagnosis of SS, patients are considered at high risk of B lymphoma, a classical and severe complication of SS. The progressive continuum of glandular B lymphocyte hyperactivity, initially polyclonal and then oligoclonal, with the presence of abnormal germinative centres, production of rheumatoid factor, deposition of immune complexes characterised by the consumption of the complement and the presence of cryoglobulinemic vasculitis which may subsequently lead to monoclonal B lymphocyte expansion and low-grade marginal area B lymphoma, is now well accepted and requires specific monitoring of patients with pSS.³

In this correspondence, we would like to draw attention on the association between SGUS characteristics and systemic complications of pSS, with a focus on cryoglobulinemic vasculitis (a well-known risk factor for progression to B lymphoma)

Table 1 Characteristics of the 97 patients with sicca syndrome included in the study

	pSS, n (%)	sSS, n (%)	Controls, n (%)	P value*
n	39	22	36	
Age (±SD)	59.1±13.4	55.3±15.0	55.8±11.9	ns
Women	36 (92.3)	22 (100)	34 (94.4)	ns
Non-specific autoimmune disease associated				
None (n=62)	39 (100)	0	23 (63.9)	<0.05†‡§
Rheumatoid arthritis (n=14)	0	9 (41.0)	5 (13.9)	<0.05†
Systemic lupus (n=16)	0	9 (41.0)	7 (19.4)	<0.05†‡
Others¶ (n=7)	0	4 (18.0)	3 (12.0)	ns
Clinical sicca syndrome				
Duration of sicca syndrome <5 years	12 (30.8)	6 (27.3)	17 (47.2)	ns
Schirmer test (±SD)	5.36±7.10	1.27±1.83	9.32±9.31	0.001‡§
Schirmer test <5 mm	28 (71.8)	22 (100)	14 (38.9)	<0.05‡
Unstimulated salivary flow (±SD)	1.3±1.26	1.2±0.96	2.1±1.50	0.02‡§
Unstimulated salivary flow <0.5 mL/5 min	14 (35.9)	9 (40.9)	0	<0.05‡§
Biology				
ANA ≥1/320	31 (79.5)	19 (86.4)	11 (30.6)	<0.05‡§
SSA antibodies	30 (76.9)	11 (50.0)	9 (25.0)	<0.05†‡§
Rheumatoid factor	22 (56.4)	13 (59.1)	8 (22.2)	ns
Hypergammaglobulinemia >16 g/L	19 (48.7)	4 (18.2)	4 (11.1)	<0.05†‡
Salivary gland involvement				
Focus score (±SD)	2.57±4.42	1.91±1.53	0.72±1.82	<0.05‡§
Focus score=1/4 mm ²	34 (97.1)	19 (90.5)	5 (17.2)	<0.05‡§
Pathological salivary glands in ultrasound	24 (61.5)	13 (33.3)	2 (5.1)	<0.05‡§
Systemic complications				
Lymphoma	3 (7.7)	0	0	ns
Cryoglobulinemic vasculitis	3 (7.7)	2 (9.0)	1 (2.8)	ns
Severe systemic complications (composite index)**	7 (17.9)	8 (36.4)	3 (8.3)	<0.05†‡

*Difference between two groups according to χ^2 test adjusted by Bonferroni's method for qualitative variables or by ANOVA for quantitative variables. Univariate analyses, all preformed with SPSS.

†pSS versus sSS.

‡pSS versus controls.

§sSS versus control.



¶Others non-specific autoimmune diseases associated: systemic sclerosis (n=4), mixed connective tissue disease (n=3).

**Composite index: interstitial lung disease, proliferative glomerulonephritis, central nervous system involvement, cryoglobulinemic vasculitis or lymphoma.

ANA, anti-nuclear antibodies; pSS, primary Sjogren's syndrome; sSS, secondary Sjogren's syndrome.

and lymphoma itself. The characteristics of our population are shown in table 1.³ There were three B lymphomas in our population, all found in the pSS group (prevalence of 7.7% in the pSS group). Cryoglobulinemic vasculitis was present in 3 (7.7%), 2 (9.0%) and 1 (2.8%) of the pSS, sSS and control group, respectively. Factors associated with lymphomas were severe salivary dryness defined by an unstimulated salivary flow <0.5 g/5 min and pathological SGUS (regardless of the classification used) (observed in all patients with lymphoma, $p < 0.01$). Pathological SGUS was also associated with the presence of cryoglobulinemic vasculitis (OR=44.0 (3.26–583), $p < 0.001$). No lymphoma or cryoglobulinemic vasculitis was found in patients with normal SGUS. In all patient with lymphoma or cryoglobulinemic vasculitis, the salivary glands were all extremely pathological in ultrasound and characterised by a heterogeneous parenchyma containing either numerous cystic lesions with no healthy parenchyma left or significant fibrosis attested by the presence of numerous hyperechoic bands. All these cases fulfilled the definition of a stage 3 of the new OMERACT classification.¹

These results confirm the data reported by Thender *et al*⁴ on the association between morphological SGUS damages (particularly of the parotid glands), usual associated-risk factors for progression to lymphoma (CD4 lymphopenia, cryoglobulinemic vasculitis, germinative centre on accessory salivary gland biopsy) and the existence or occurrence of lymphoma. Nevertheless, our cross-sectional data do not allow to conclude on the prognostic value of SGUS for lymphoma occurrence in pSS. These results nonetheless support the use of this tool in daily practice and its systematic inclusion in the assessment of prospective cohorts of pSS, which would allow the evaluation of the relevance of SGUS features as predictive markers for lymphoma. In the end, the prospective evaluation of SGUS results will help to precise the place of SGUS examination in the global follow-up and management of patients with pSS, beyond diagnosis.

Guillaume Coiffier , ¹ **Amélie Martel**,² **Jean-David Albert**,¹ **Alain Lescoat** ,³ **Aurore Bleuzen**,⁴ **Aleth Perdriger**,⁵ **Michel De Bandt**,⁶ **François Maillot**²

¹Rheumatology Department, CHU Rennes, Rennes, France

²Internal Medicine, CHRU Tours, Tours, France

³Internal Medicine, CHU South Hospital, Rennes, France

⁴Medical Imaging, CHRU Tours, Tours, France

⁵Rhumatologie, Centre Hospitalier, Rennes, France

⁶Rheumatology Department, University Hospital Martinique, Fort de France, France

Correspondence to Dr Guillaume Coiffier, Rhumatologie, CHU de RENNES, 35000 Rennes, France; guillaume.coiffier@chu-rennes.fr

Acknowledgements All authors would like to thank the patients who participated in this study.

Contributors GC included patients, conducted inclusion visits, performed ultrasound examinations, analysed results and statistics and wrote the manuscript. AM included patients, conducted inclusion visits, analysed results and statistics and wrote the manuscript. J-DA and AL analysed results and statistics and wrote the manuscript. AB performed ultrasound examinations, analysed results and wrote the manuscript. AP, MDB and FM included patients, analysed results and wrote the manuscript.

Competing interests None declared.

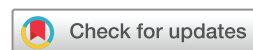Patient consent for publication Not required.

Ethics approval All patients were informed of the objectives and procedure of the study and gave their consent. The study was approved by the ethics committee of Rennes university hospital (Avis n°16.75, May 2016).

Provenance and peer review Not commissioned; internally peer reviewed.

Data availability statement The cohort database is supervised by GC and AM. Data are available upon reasonable request. All data relevant to the study are included in the article.

© Author(s) (or their employer(s)) 2021. No commercial re-use. See rights and permissions. Published by BMJ.



To cite Coiffier G, Martel A, Albert J-D, *et al.* *Ann Rheum Dis* 2021;**80**:e111.

Received 2 August 2019

Accepted 3 August 2019

Published Online First 16 August 2019



► <http://dx.doi.org/10.1136/annrheumdis-2019-216327>

Ann Rheum Dis 2021;**80**:e111. doi:10.1136/annrheumdis-2019-216122

ORCID iDs

Guillaume Coiffier <http://orcid.org/0000-0003-3560-128X>

Alain Lescoat <http://orcid.org/0000-0003-2081-8558>

REFERENCES

- Jousse-Joulin S, D'Agostino MA, Nicolas C, *et al.* Video clip assessment of a salivary gland ultrasound scoring system in Sjögren's syndrome using consensual definitions: an OMERACT ultrasound working group reliability exercise. *Ann Rheum Dis* 2019;**78**:967–73.
- Martel A, Coiffier G, Bleuzen A, *et al.* What is the best salivary gland ultrasonography scoring methods for the diagnosis of primary or secondary Sjögren's syndromes? *Joint Bone Spine* 2019;**86**:211–7.
- Goules AV, Tzioufas AG. Lymphomagenesis in Sjögren's syndrome: predictive biomarkers towards precision medicine. *Autoimmun Rev* 2019;**18**:137–43.
- Theander E, Mandl T. Primary Sjögren's syndrome: diagnostic and prognostic value of salivary gland ultrasonography using a simplified scoring system. *Arthritis Care Res* 2014;**66**:1102–7.