

Interleukin-6 receptor blockade with subcutaneous tocilizumab in severe COVID-19 pneumonia and hyperinflammation: a case-control study

Many patients with severe COVID-19 rapidly progress to critical disease with refractory hypoxemia requiring invasive mechanical ventilation (IMV).¹ Elevated levels of C reactive protein (CRP) and interleukin-6 (IL-6), reflecting an hyperinflammatory response, identify patients at risk of progression to refractory hypoxemia and death.² Recent evidences suggested that high-dose intravenous tocilizumab (TCZ), a humanised anti-IL-6 receptor antibody, may rapidly reduce fever and inflammatory markers, and improve oxygenation in severe to critical COVID-19.³⁻⁵ Data on the safety and efficacy of subcutaneous TCZ, already approved for the treatment of rheumatoid arthritis, are limited. The aim of this study was to compare the clinical course and outcomes of patients treated with subcutaneous TCZ on top of standard of care (SOC) with those of patients receiving SOC only.

In this retrospective case-control study, we treated with TCZ 324 mg, given as two concomitant subcutaneous injections, all consecutive patients at Pescara General Hospital, Italy between 28 March and 21 April 2020, with laboratory-confirmed COVID-19 pneumonia (involving $\geq 20\%$ of lung parenchyma on chest CT), hyperinflammation (CRP ≥ 20 mg/dL), hypoxemia (oxygen saturation $< 90\%$ on room air) requiring supplemental oxygen through nasal cannulas or mask, who had no contraindications to treatment such as bacterial or fungal infection, neutropenia or liver injury. Patients signed an informed consent for the off-label use of TCZ. We reviewed all patients hospitalised for COVID-19 pneumonia when TCZ was not available in our centre and identified those matching the same treatment criteria: 40 subjects matched for sex and age were selected as SOC group (online supplementary table 1).

Clinical data were available for all patients until discharge or death, and for those discharged prior to day 35, additional clinical information was obtained by phone contact. Data are presented as median and IQR. Within-group changes were compared using the Wilcoxon test for paired analysis, and between-groups

differences were analysed using the Mann-Whitney U test for unpaired test. Log-rank (Mantel-Cox) analysis was used to compare event-free survival between the two groups.

Treatment with TCZ was well tolerated, with no serious or clinically relevant adverse events. None of the patients experienced neutropenia (absolute neutrophil count $< 1000/\text{mm}^3$), one (2.5%) developed bacterial pneumonia while on IMV, as compared with three (7.5%) in the SOC group, and one (2.5%) had transient moderate liver injury (elevation in alanine aminotransferase five times above the upper limit of normal value), as compared with none in the SOC group (online supplementary table 2).

Treatment with TCZ resulted in an improvement of oxygenation, as assessed by the ratio of partial pressure of oxygen to fraction of inspired oxygen (P/F), which increased at day 1 (+8%, IQR -9 to +25; $p=0.005$ for within-group and $p<0.006$ for between-group comparisons) and day 3 (+25%, IQR +10 to +52; $p<0.001$ for within-group and $p<0.001$ for between-group comparisons), whereas it continued to worsen in the SOC group ($p<0.001$, online supplementary figure S1).

When compared with SOC-treated patients, fewer TCZ-treated patients had disease progression, defined as requirement of IMV or death (2 (5%) vs 12 (30%), $p=0.003$), or died (2 (5%) vs 11 (27.5%), $p=0.006$) (figure 1). Online supplementary

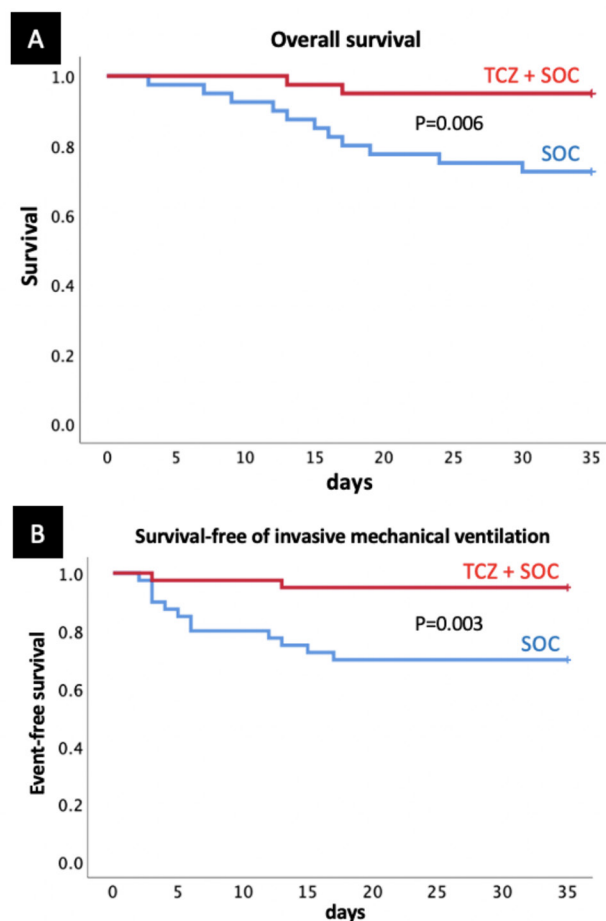


Figure 1 Survival and survival-free of invasive mechanical ventilation. Patients receiving tocilizumab (TCZ) on top of standard of care (SOC) were significantly less likely to die (A), or need invasive mechanical ventilation or die (B) than patients treated with SOC only matched for sex, age and severity of illness (log-rank Mantel-Cox χ^2 7.418, $p=0.006$ and χ^2 8.605, $p=0.003$ for panels A and B, respectively).

table 3 shows the WHO Ordinal Scale for Improvement for the two groups.

TCZ was associated with a reduction in CRP at day 1 (−32%, IQR −18 to −60) and day 3 (−83%, IQR −63 to −83; $p < 0.001$ for within-group changes), whereas it increased in the SOC group ($p < 0.001$ for between-group comparisons at both time points; online supplementary figure 2).

Our findings suggest that IL-6 receptor blockade with subcutaneous TCZ may reduce the risk of progression from severe to critical COVID-19 and mortality when administered on top of SOC. Infection from SARS-CoV viruses results in an inflammasome-mediated response characterised by elevated levels of interleukin-1 β ,⁶ which trigger IL-6 release, promoting lung injury. TCZ is often provided intravenously on a compassionate-use basis to patients with COVID-19 with refractory hypoxemia on IMV. Randomised controlled trials are under way with IL-6 blockers. Nevertheless, many patients with COVID-19 are hospitalised with hypoxemia not requiring IMV. Hyperinflammation may promote disease progression as indicated by higher levels of inflammatory biomarkers being associated with increased risk for dire outcomes.² We herein report on the innovative use of early subcutaneous TCZ in a subgroup of patients with severe COVID-19 pneumonia who are at risk for progression to IMV and death. While limited by the small number of patients included and the non-random nature of the comparisons, data appear reassuring in terms of safety, and encouraging when compared with those of patients treated with SOC in our centre or other published cohorts.^{1,3–5}

Nicola Potere,^{1,2} Marcello Di Nisio,^{3,4} Donatella Cibelli,⁵ Rosa Scurti,⁶ Antonella Frattari,⁷ Ettore Porreca,¹ Antonio Abbate,² Giustino Parruti⁵

¹Department of Medical, Oral and Biotechnological Sciences, "G D'Annunzio" University, Chieti, Italy

²VCU Pauley Heart Center, Virginia Commonwealth University, Richmond, Virginia, USA

³Department of Medicine and Ageing Sciences, "G' D'Annunzio" University, Chieti-Pescara, Italy

⁴Department of Vascular Medicine, Amsterdam Medical Center, Amsterdam, The Netherlands

⁵Infectious Diseases Unit, Pescara General Hospital, Pescara, Italy

⁶Geriatric Medicine Unit, Pescara General Hospital, Pescara, Italy

⁷Intensive Care Unit, Pescara General Hospital, Pescara, Italy

Correspondence to Dr Giustino Parruti, Infectious Diseases Unit, Pescara Hospital, Pescara 65124, Italy; parrutig@gmail.com

Handling editor Josef S Smolen

Acknowledgements We thank Giulia Rizzo, Matteo La Vella and Leonardo Pieramati for their appreciable help in data collection. We thank all patients who agreed to participate to the study, and our first-line colleagues who incessantly worked to contain the COVID-19 pandemic.

Contributors The corresponding author had full access to all the data in the study, and takes responsibility for the integrity of the data and the accuracy of the data analysis. Study conception and design: NP, AA, GP. Statistical analysis: NP, AA, GP. Interpretation of the data: NP, AA, GP. Drafting of the manuscript: NP, MDN, AA. Critical revision of the manuscript for important intellectual content: all authors. Final approval of the manuscript: all authors.

Funding The authors have not declared a specific grant for this research from any funding agency in the public, commercial or not-for-profit sectors.

Competing interests MDN has received personal fees from Bayer, Daiichi Sankyo, Sanofi, Pfizer, Leo Pharma and Aspen, outside of the submitted work. AA has received research support from Novartis, Olatec and Swedish Orphan Biovitrum, outside of the submitted work.

Patient and public involvement Patients and/or the public were not involved in the design, or conduct, or reporting, or dissemination plans of this research.

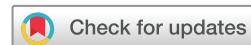Patient consent for publication Not required.

Provenance and peer review Not commissioned; externally peer reviewed.

This article is made freely available for use in accordance with BMJ's website terms and conditions for the duration of the covid-19 pandemic or until otherwise determined by BMJ. You may use, download and print the article for any lawful, non-commercial purpose (including text and data mining) provided that all copyright notices and trade marks are retained.

© Author(s) (or their employer(s)) 2021. No commercial re-use. See rights and permissions. Published by BMJ.

► Additional material is published online only. To view please visit the journal online (<http://dx.doi.org/10.1136/annrheumdis-2020-218243>).



To cite Potere N, Di Nisio M, Cibelli D, et al. *Ann Rheum Dis* 2021;**80**:271–272.

Received 5 June 2020

Revised 28 June 2020

Accepted 29 June 2020

Published Online First 9 July 2020

Ann Rheum Dis 2021;**80**:271–272. doi:10.1136/annrheumdis-2020-218243

ORCID iD

Giustino Parruti <http://orcid.org/0000-0003-3483-8170>

REFERENCES

- Potere N, Valeriani E, Candeloro M, et al. Acute complications and mortality in hospitalized patients with coronavirus disease 2019: a systematic review and meta-analysis. *Crit Care* 2020;24:389.
- Wu C, Chen X, Cai Y, et al. Risk factors associated with acute respiratory distress syndrome and death in patients with coronavirus disease 2019 pneumonia in Wuhan, China. *JAMA Intern Med* 2020. doi:10.1001/jamainternmed.2020.0994. [Epub ahead of print: 13 Mar 2020].
- Xu X, Han M, Li T, et al. Effective treatment of severe COVID-19 patients with tocilizumab. *Proc Natl Acad Sci U S A* 2020;117:10970–5.
- Toniati P, Piva S, Cattalini M, et al. Tocilizumab for the treatment of severe COVID-19 pneumonia with hyperinflammatory syndrome and acute respiratory failure: a single center study of 100 patients in Brescia, Italy. *Autoimmun Rev* 2020;19:102568.
- Campochiaro C, Della Torre E, Cavalli G, et al. Efficacy and safety of tocilizumab in severe COVID-19 patients: a single-center retrospective cohort study. *Eur J Int Med* 2020.
- Siu K-L, Yuen K-S, Castaño-Rodríguez C, et al. Severe acute respiratory syndrome coronavirus ORF3a protein activates the NLRP3 inflammasome by promoting TRAF3-dependent ubiquitination of ASC. *Faseb J* 2019;33:8865–77.