OPEN ACCESS

CONCISE REPORT

# Analysis of distribution and severity of inflammation in patients with osteoarthritis compared to rheumatoid arthritis by ICG-enhanced fluorescence optical imaging and musculoskeletal ultrasound: a pilot study

A-M Glimm, S G Werner, G R Burmester, M Backhaus, S Ohrndorf

**Handling editor** Tore K Kvien

▶ Additional material is published online only. To view please visit the journal online (http://dx.doi.org/10.1136/annrheumdis-2015-207345).

Department of Rheumatology and Clinical Immunology, Charité Universitätsmedizin Berlin, Berlin, Germany

**Correspondence to**
Dr Sarah Ohrndorf, Department of Rheumatology and Clinical Immunology, Charité Universitätsmedizin Berlin, Charitéplatz 1, Berlin 10117, Germany; sarah.ohrndorf@charite.de

Received 22 January 2015
Revised 24 June 2015
Accepted 14 July 2015
Published Online First 26 August 2015

Open Access
Scan to access more free content

▶ http://dx.doi.org/10.1136/annrheumdis-2015-207315
▶ http://dx.doi.org/10.1136/annrheumdis-2015-208399
▶ http://dx.doi.org/10.1136/annrheumdis-2015-208661

**To cite:** Glimm A-M, Werner SG, Burmester GR, *et al*. *Ann Rheum Dis* 2016;**75**:566–570.

## ABSTRACT

**Background** In rheumatoid arthritis (RA), hand synovitis appears especially in wrist, metacarpophalangeal (MCP) and proximal interphalangeal (PIP) joints. In hand osteoarthritis (OA), potential inflammatory changes are mainly present in PIP and distal interphalangeal (DIP) joints. Joint inflammation can be visualised by fluorescence optical imaging (FOI) and musculoskeletal ultrasound (US).

**Objective** Comparison of the amount and distribution of inflammatory signs in wrist and finger joints of the clinically dominant hand in patients with OA and RA by FOI and gray-scale (GSUS) and power Doppler US (PDUS).

**Methods** FOI and GSUS/PDUS were performed in 1.170 joints (wrists, MCP, PIP, DIP) in 90 patients (67 RA, 23 OA). Joint inflammation was graded by a semiquantitative score (0–3) for each imaging method.

**Results** GSUS/PDUS showed wrist and MCP joints mostly affected in RA. DIP joints were graded higher in OA. In FOI, RA and OA featured inflammatory changes in the respective joint groups depending on the phase of fluorescence dye flooding.

**Conclusions** US and FOI detected inflammation in both RA and OA highlighting the inflammatory component in the course of OA. The different inflammatory patterns and various shapes of fluorescence enhancement in FOI may offer opportunities to distinguish and determine the inflammatory status in both diseases.

## INTRODUCTION

Novel effective therapies in rheumatology enable us to control the progressive process of chronic inflammatory joint disease[1] providing new information on the topic of remission,[2] which lead to new requirements for imaging methods in terms of early diagnoses, assessing therapeutic efficiency and prognosis in follow-up examinations.[2 3]

A distinction between rheumatoid arthritis (RA) and other arthritic and degenerative diseases needs to be drawn when a diagnosis is made.[4] Osteoarthritis (OA) is currently not thought to be a primary inflammatory joint disease, although inflammatory alterations of so-called 'activated joints' often occur in flares[5] and correlate with pain.[6 7] Thus, imaging techniques are used in order to differentiate between various diagnoses,[8] for example, between an activated or erosive OA and RA or psoriatic arthritis.

For the last two decades, musculoskeletal ultrasound (US) has been widely applied as an imaging modality in rheumatology, permitting the simultaneous detection of soft tissue and erosive bone lesion early in the disease course.[9] Thus, synovitis and tenosynovitis as morphological features of an inflammatory process are shown in a more sensitive manner than by clinical examination.[10 11] In addition, good correlations have been demonstrated between US and MRI in the detection of inflammation.[11–13] Moreover, joint changes in OA, including bone abnormalities (osteophytes, erosions and cartilage damage), synovial and periarticular inflammation can be visualised via US[14–16] affirming the diagnosis and informing about the inflammatory status for the treatment decision.[14]

Indocyanine green (ICG)-based fluorescence optical imaging (FOI) has been shown to be capable of detecting inflammatory arthritis in humans.[3 17–19] Recently, Werner *et al*[3 18] demonstrated that FOI is able to differentiate between healthy and inflammatory joints revealing a good agreement with data from clinical examinations, MRI and power Doppler US (PDUS).[3]

It is thereby possible that flares of inflammation could be detected in OA as well.

This study addresses the investigation of hand-OA—a previously neglected rheumatic joint disease—in comparison to RA as an important differential diagnosis made available by the use of visualised techniques (US and FOI). To this end, the amount of inflammation (grades 0–3) and the distribution of inflamed joints in both diseases were analysed, depending on the US mode (gray-scale/power Doppler) and on the phase of fluorescence dye flooding in FOI (grades 1–3, Prima Vista-Mode (PVM)).

## PATIENTS AND METHODS

### Patients

Patients with RA and OA were recruited for this study. All patients included fulfilled the European League Against Rheumatism/American College of Rheumatology criteria.[20 21]



Ann Rheum Dis: first published as 10.1136/annrheumdis-2015-207345 on 26 August 2015. Downloaded from http://ard.bmj.com/ on April 18, 2024 by guest. Protected by copyright.

### Clinical and laboratory examination

In both patient groups, clinical[22] and laboratory examinations were performed (see online supplementary text for detail).

### Musculoskeletal US

Ultrasonographic examination of the wrist (WR; midline, radial, ulnar), the metacarpophalangeal (MCP), proximal (PIP) and distal interphalangeal (DIP) joints (fingers II to V; palmar and dorsal) of the clinically dominant hand (for tenderness and/or swelling) was performed in neutral position by gray-scale US (GSUS) and PDUS following standardised procedures.[23] Settings for GSUS were as follows (Mylab twice, Esaote, Genua; Italy): frequency 16 MHz and length of scanner 42 mm. The gain depended on joint regions and patients and was nearly 50%. Settings for PDUS were as follows: frequency 9.1 MHz, Pulse Repitition Frequency (PRF) 750 Hz, PD-gain depending on joint regions and patients was nearly 50%; wall filter was three. Synovitis and tenosynovitis were evaluated for their severity, graded by a semiquantitative score (0–3).[10 24]

### Fluorescence optical imaging

The FOI System Xiralite X4 (Mivenion) was used following a standardised procedure (a detailed description is given in the online supplementary text).

To evaluate the distribution of ICG, the image sequence in the film modus and the automatically generated composite image in the PVM were analysed.[3 18] For the image sequence, three phases in position to the fingertips were defined regarding development of signal intensities depending on the phase of fluorescence dye flooding and individual perfusion.[18] Phase 1 (p1) includes the period between starting the investigation, application of the dye and increased signal intensities in the fingertips.[18] When the dye leaves the fingertips from distal to proximal in WR direction, phase 2 (p2) begins as the period of persisting high signal intensities in the fingertips.[18] It can be identified by the red colour in the fingertips. Phase 3 (p3) starts when no signal intensity can be determined in the fingertips.[18]

ICG distribution was assessed for the joint regions of the identical hand that had been examined by US. The evaluation of the signal intensity included colour intensity, planar size and shape of enhancement[18] (figure 1). For analysing joint activity by FOI, a semiquantitative grading system 'FOI activity score' (FOIAS) including grades 0–3 was used[3 18] (see online supplementary text).

### Statistical analyses

For statistical analyses, the percentage of frequencies of the score grades 1–3 were calculated in both cohorts for GSUS, PDUS and all phases of FOI (p1–3 and PVM) and then compared with each other (see online supplementary text for detailed description).

## RESULTS

### Demographic, clinical and laboratory data

Ninety patients were recruited for this study (67 patients with RA and 23 patients with OA).

The results of the demographic, clinical and laboratory features of the study population are shown in online supplementary table S1.

### Frequency distribution of inflammatory joints for US and FOI

Figure 2A–F illustrates the frequencies of grades 1–3 per joint in US and FOI for the RA (black graphs) versus OA cohort (red graphs; additionally see online supplementary figures S1A–D).

#### Gray-scale US

A comparison of the two cohorts with regard to frequency distributions of grades 1–3 in GSUS showed that the PIP and DIP joints of the patients with OA revealed score degrees of 1–3 more often compared with the respective joints in the RA cohort. In contrast, more WR and MCP joints of patients with RA showed inflammatory changes in comparison with those of patients with OA (figure 2A).

#### Power Doppler US

In PDUS, score degrees of 1–3 were generally less present in comparison with GSUS (figure 2B). Patients with RA featured more inflammatory changes in terms of synovitis and tenosynovitis in PDUS (figure 3B) when compared with patients with OA, except for DIP joints in OA. In OA cohort, grade 2 was most commonly found in the PIP joints, while none of the joint groups had a value of grade 3 (figure 3D).

#### Fluorescence optical imaging

The highest frequencies of grades 1–3 in all joints were demonstrated in phase 2 in both cohorts.

##### *Phase 1*

In phase 1 (figure 2C), grades 1–3 were present more frequently in the RA cohort in comparison with the OA group. Moreover, the WR was the leading joint in both cohorts.

In the OA cohort, grade 1 as the major grade level in phase 1 was evident mostly in the WRs.

##### *Phase 2*

Viewing phase 2 in figure 2D, the leading joint group in both cohorts was the group of the WRs with the same total amount in both groups. The joints with the lowest percentage rates were the MCP joints; here, there was a higher percentage in the RA cohort than in the OA cohort (figure 3A). In comparison with patients with RA, the frequencies of grades 1–3 in DIP joints of patients with OA reached a higher proportion (figure 3C).

##### *Phase 3*

The WR and PIP joints were in the lead in phase 3 with higher levels in the OA cohort (figure 2E). Among these, the WR was the joint with the highest percentage.

It should be noted that the PIP joints of patients with OA attained the highest level of grade 1 for all joints in both cohorts in this phase.

##### *PVM*

PVM revealed practically the same pattern of the total percentage rates among the joints as was described for phase 2 (figure 2F). Leading joint groups in this FOI mode were the WRs and PIP joints. Higher percentage rates in PIP and DIP could be detected in patients with OA.

## DISCUSSION

Up to now, FOI has been shown to be capable of detecting inflammatory changes in human arthritic joints[17] in good agreement with clinical examination, MRI and PDUS.[3 18]



Ann Rheum Dis: first published as 10.1136/annrheumdis-2015-207345 on 26 August 2015. Downloaded from http://ard.bmj.com/ on April 18, 2024 by guest. Protected by copyright.

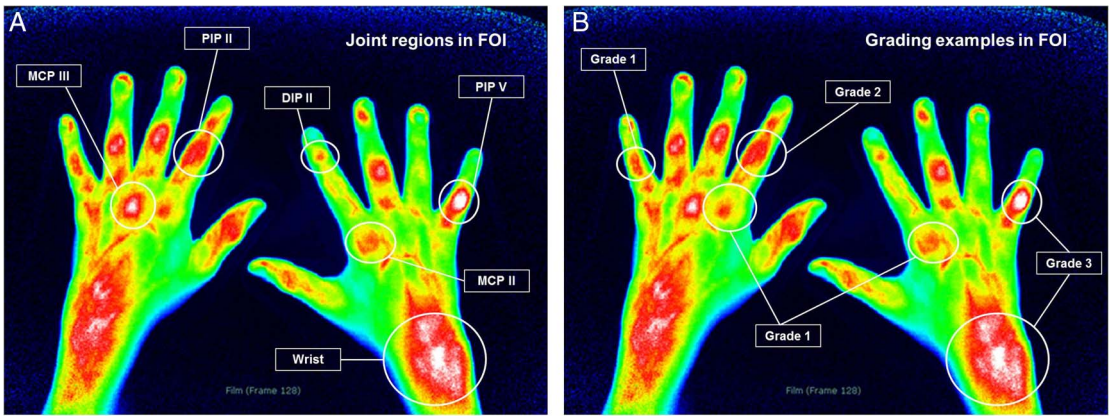


**Figure 1** (A and B) Examples for joint regions and grades 1–3 in fluorescence optical imaging. DIP, distal interphalangeal; FOI, fluorescence optical imaging; MCP, metacarpophalangeal; PIP, proximal interphalangeal.

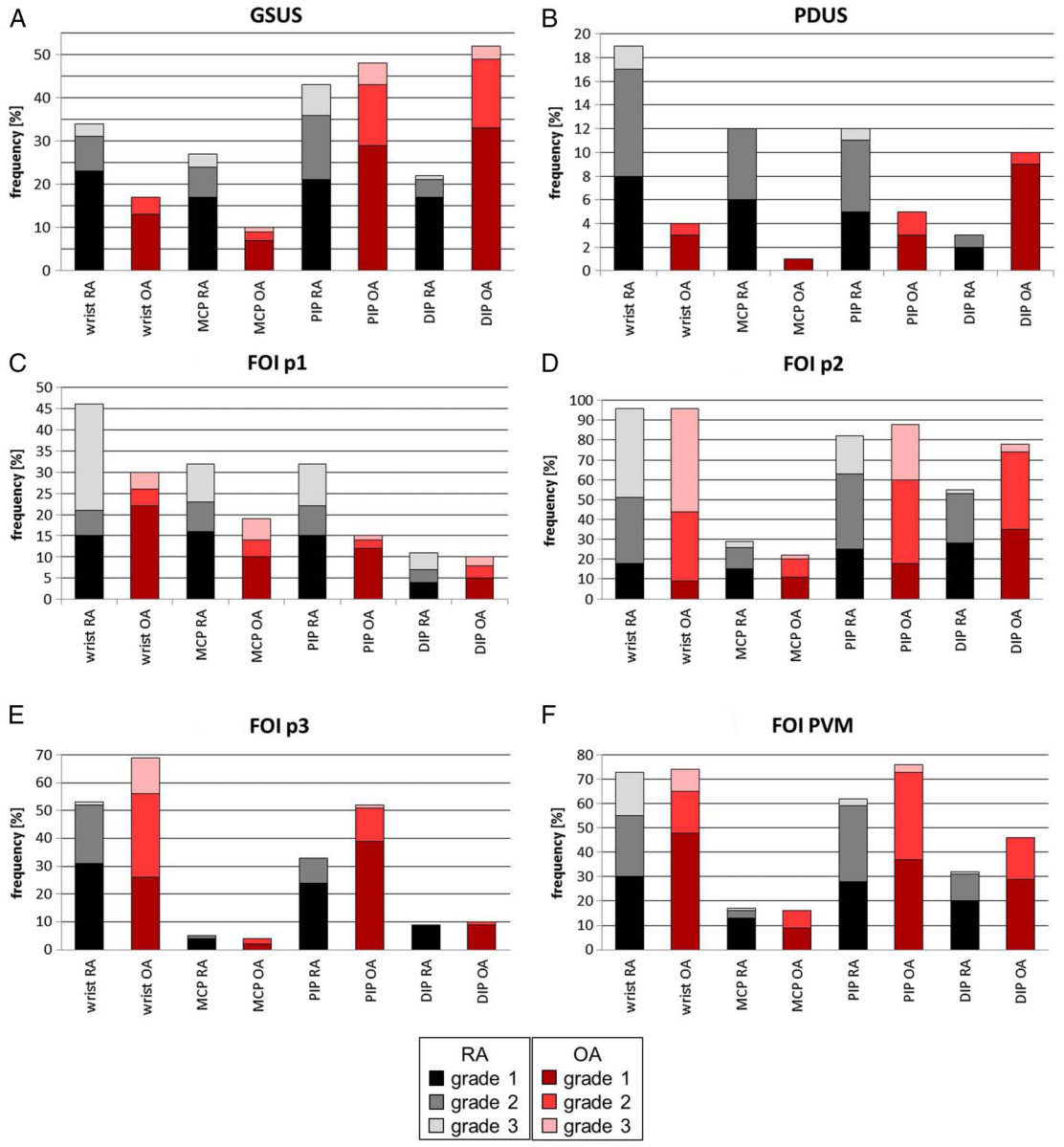


**Figure 2** (A–F) Score frequencies for grade 1–3 per joint in total for synovitis and tenosynovitis, dorsal and palmar side in ultrasound and fluorescence optical imaging for rheumatoid arthritis (RA) vs osteoarthritis (OA) cohort. DIP, distal interphalangeal; FOI, fluorescence optical imaging; GSUS, gray-scale US; MCP, metacarpophalangeal; p1, phase 1; p2, phase 2; p3, phase 3; PDUS, power Doppler US; PIP, proximal interphalangeal; PVM, Prima Vista-Mode.



Ann Rheum Dis: first published as 10.1136/annrheumdis-2015-207345 on 26 August 2015. Downloaded from http://ard.bmj.com/ on April 18, 2024 by guest. Protected by copyright.

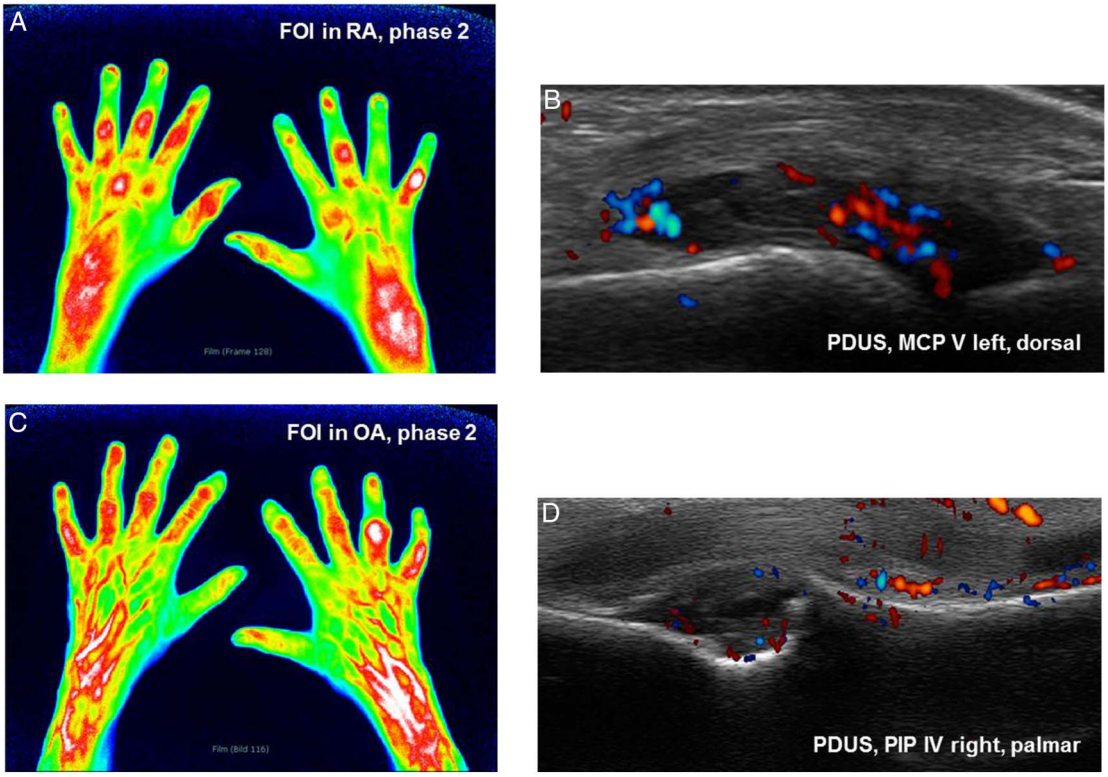


**Figure 3** (A and B) Phase 2 in fluorescence optical imaging (FOI) and the corresponding power Doppler US (PDUS) image of metacarpophalangeal (MCP) V left dorsal in patient with rheumatoid arthritis (RA). (A) Phase 2 shows planar signals in proximal interphalangeal (PIP), MCP and wrists in both hands. (B) PDUS activity grade 2 as a sign for active synovitis in left MCP V. (C and D) Phase 2 in FOI and corresponding PDUS of PIP IV right palmar in patient with osteoarthritis (OA). (C) Streaky FOI signals in DIP and PIP joints as degenerative signs as well as planar signal in PIP IV in token of an active inflammatory joint. FOI signals of higher level in right wrist compared to the left side. (D) PDUS of same right PIP joint shows synovitis and PDUS activity as well as osteophyte.

To our knowledge, this study is the first one using FOI (phases 1–3, PVM) for the examination of potential inflammation in OA. On that account, we compared the distribution of inflammation in WR and finger joints of OA with RA patients by FOI and US (GSUS/PDUS).

Regarding the frequency distributions of inflammation in the individual joints, the inflammatory patterns of affected joints in both US modes confirmed our expectations. Thus, higher percentage rates of RA joints in PDUS as a sign of active inflammation were found. Considering FOI results, inflammatory changes can be visualised in patients with RA and also clearly in patients with OA.

As far as we know, increased blood volumes as well as the formation of new microvessels as seen by dysregulated microcirculation and angiogenic activity in the early course of RA[25 26] cause an enrichment of ICG in the inflammatory tissue.[17] A transition of ICG into the interstitial space and interactions with endothelial components has been considered.[17 27] Phase 1 appears to symbolise the flooding in of the dye, phase 2 may visualise the distribution and persistence of ICG and phase 3 may show the washing out of the dye, as well as those ICG molecules remaining within the inflamed tissue. Especially the flooding in and the washing out of the dye ICG may depend on an increased and dysregulated microcirculation leading to the assumption that phase 1 visualises active inflammation and phase 3 reveals capillary leakage (see online supplementary figure S2 and S3).[18] In reference to our results, the frequency rates showed higher grading levels in phase 1 for RA, connoting active inflammation. Interestingly, the grading of signal intensities in WRs and PIP joints in phase 3 in the OA cohort attained higher percentage levels. Therefore, FOI may underline the findings of previous studies that inflammation plays an important role in the disease course of OA.[5–7 14 16] Confirming the inflammatory component in the pathogenesis of hand OA, synovitis in GSUS and activity in PDUS have recently been shown to predict radiographic progression of hand OA.[28]

In FOI, score frequency patterns for phase 2 (WR and PIP joints) and PVM (WR and MCP joints) were similar for both diseases. Werner *et al*[18] had already stated that phase 2 may reflect potential subclinical inflammation.

During the course of evaluating signal intensities, we have recognised various shapes and manifestations of the signals detected, with the consequence that upon further analysis of these, various diagnoses can be made (figure 3C). This is a very new and interesting aspect; however, future investigation must follow to confirm this hypothesis.

In summary, US as well as FOI were able to detect active inflammation in OA. Thus, an inflammatory component in the course of OA should not be underestimated. Moreover, this could lead to the clinical usage of FOI in patients with OA in the future to visualise inflammation, make a therapeutic decision, be of help in clinical trials and make use of the opportunity for follow-up investigations.

**Acknowledgements** We thank Gabriela Schmittat for technical assistance. Furthermore, we thank Dr Bernd Schicke for assistance with the statistical calculation. One of the technical devices (FOI) was provided via an unrestricted educational grant by Pfizer Company, Berlin, Germany.

**Contributors** All authors were involved in drafting the article or revising it critically for important intellectual content, and all authors approved the final version to be



Ann Rheum Dis: first published as 10.1136/annrheumdis-2015-207345 on 26 August 2015. Downloaded from http://ard.bmj.com/ on April 18, 2024 by guest. Protected by copyright.

published. No medical writer was involved in the preparation of the manuscript. A-MG, SGW, SO and MB had full access to all of the data in the study and take responsibility for the integrity of the data and the accuracy of the data analysis. Study conception and design: A-MG, SGW, GRB, MB and SO. Acquisition of data: A-MG, SGW, MB and SO. Analysis and interpretation of data: A-MG, SGW, GRB, MB and SO. Manuscript preparation: A-MG, SGW, GRB, MB and SO. Statistical analysis: A-MG, SGW, MB, SO and Schicke (see acknowledgements).

**Funding** This work was supported by the BMBF project 'ArthroMark', subproject no. 7 'Clinical study on Biomarkers and Imaging'.

**Competing interests** None declared.

**Patient consent** Obtained.

**Ethics approval** The approval of the study was granted by the ethics committee of the Charité—Universitätsmedizin Berlin, Germany.

**Provenance and peer review** Not commissioned; externally peer reviewed.

**Open Access** This is an Open Access article distributed in accordance with the Creative Commons Attribution Non Commercial (CC BY-NC 4.0) license, which permits others to distribute, remix, adapt, build upon this work non-commercially, and license their derivative works on different terms, provided the original work is properly cited and the use is non-commercial. See: http://creativecommons.org/licenses/by-nc/4.0/

## REFERENCES


1. Combe B, Landewe R, Lukas C, *et al*. EULAR recommendations for the management of early arthritis: report of a task force of the European Standing Committee for International Clinical Studies Including Therapeutics (ESCISIT). *Ann Rheum Dis* 2007;66:34–45.
2. Smolen JS, Landewe R, Breedveld FC, *et al*. EULAR recommendations for the management of rheumatoid arthritis with synthetic and biological disease-modifying antirheumatic drugs. *Ann Rheum Dis* 2010;69:964–75.
3. Werner SG, Langer HE, Ohrndorf S, *et al*. Inflammation assessment in patients with arthritis using a novel in vivo fluorescence optical imaging technology. *Ann Rheum Dis* 2012;71:504–10.
4. Szkudlarek M, Wakefield RJ, Backhaus M, *et al*. The discriminatory capacity of ultrasound in rheumatoid arthritis: active vs inactive, early vs advanced, and more. *Rheumatology* 2012;51(Suppl 7):vii6–9.
5. Iagnocco A. Ultrasound in osteoarthritis. *Clin Exp Rheumatol* 2014;32(1 Suppl 80): S48–52.
6. Keen HI, Wakefield RJ, Grainger AJ, *et al*. An ultrasonographic study of osteoarthritis of the hand: synovitis and its relationship to structural pathology and symptoms. *Arthritis Rheum* 2008;59:1756–63.
7. Kortekaas MC, Kwok WY, Reijnierse M, *et al*. Pain in hand osteoarthritis is associated with inflammation: the value of ultrasound. *Ann Rheum Dis* 2010;69:1367–9.
8. Kellner H. Arthrosonographie: Von der Aussenseitermethode zum standardisierten und integrierten Bestandteil der bildgebenden Diagnostik in der Rheumatologie. *Z Rheumatol* 2001;60:137–8.
9. Ohrndorf S, Backhaus M. Advances in sonographic scoring of rheumatoid arthritis. *Ann Rheum Dis* 2013;72(Suppl 2):ii69–75.
10. Szkudlarek M, Court-Payen M, Jacobsen S, *et al*. Interobserver agreement in ultrasonography of the finger and toe joints in rheumatoid arthritis. *Arthritis Rheum* 2003;48:955–62.
11. Backhaus M, Kamradt T, Sandrock D, *et al*. Arthritis of the finger joints: a comprehensive approach comparing conventional radiography, scintigraphy, ultrasound, and contrast-enhanced magnetic resonance imaging. *Arthritis Rheum* 1999;42:1232–45.
12. Scheel AK, Hermann KG, Ohrndorf S, *et al*. Prospective 7 year follow up imaging study comparing radiography, ultrasonography, and magnetic resonance imaging in rheumatoid arthritis finger joints. *Ann Rheum Dis* 2006;65:595–600.
13. Wakefield RJ, Gibbon WW, Conaghan PG, *et al*. The value of sonography in the detection of bone erosions in patients with rheumatoid arthritis: a comparison with conventional radiography. *Arthritis Rheum* 2000;43:2762–70.
14. Haugen IK, Hammer HB. Role of modern imaging techniques in hand osteoarthritis research and clinical practice. *Curr Rheumatol Rep* 2014;16:399.
15. Iagnocco A, Naredo E. Osteoarthritis: research update and clinical applications. *Rheumatology* 2012;51(Suppl 7):vii2–5.
16. Vlychou M, Koutroumpas A, Malizos K, *et al*. Ultrasonographic evidence of inflammation is frequent in hands of patients with erosive osteoarthritis. *Osteoarthritis Cartilage* 2009;17:1283–7.
17. Fischer T, Ebert B, Voigt J, *et al*. Detection of Rheumatoid Arthritis Using Non-Specific Contrast Enhanced Fluorescence Imaging. *Acad Radiol* 2010;17:375–81.
18. Werner SG, Langer HE, Schott P, *et al*. Indocyanine green-enhanced fluorescence optical imaging in patients with early and very early arthritis: a comparative study with magnetic resonance imaging. *Arthritis Rheum* 2013;65:3036–44.
19. Meier R, Thurmel K, Moog P, *et al*. Detection of synovitis in the hands of patients with rheumatologic disorders: diagnostic performance of optical imaging in comparison with magnetic resonance imaging. *Arthritis Rheum* 2012;64:2489–98.
20. Aletaha D, Neogi T, Silman AJ, *et al*. 2010 rheumatoid arthritis classification criteria: an American College of Rheumatology/European League Against Rheumatism collaborative initiative. *Ann Rheum Dis* 2010;69:1580–8.
21. Altman R, Alarcon G, Appelrouth D, *et al*. The American College of Rheumatology criteria for the classification and reporting of osteoarthritis of the hand. *Arthritis Rheum* 1990;33:1601–10.
22. Prevoo ML, van't Hof MA, Kuper HH, *et al*. Modified disease activity scores that include twenty-eight-joint counts. Development and validation in a prospective longitudinal study of patients with rheumatoid arthritis. *Arthritis Rheum* 1995;38:44–8.
23. Backhaus M, Burmester GR, Gerber T, *et al*. Guidelines for musculoskeletal ultrasound in rheumatology. *Ann Rheum Dis* 2001;60:641–9.
24. Scheel AK, Hermann KG, Kahler E, *et al*. A novel ultrasonographic synovitis scoring system suitable for analyzing finger joint inflammation in rheumatoid arthritis. *Arthritis Rheum* 2005;52:733–43.
25. Kennedy A, Ng CT, Biniecka M, *et al*. Angiogenesis and blood vessel stability in inflammatory arthritis. *Arthritis Rheum* 2010;62:711–21.
26. Andersson SE, Johansson A, Lexmuller K, *et al*. Physiological characterization of mBSA antigen induced arthritis in the rat. II. Joint blood flow, glucose metabolism, and cell proliferation. *J Rheumatol* 1998;25:1778–84.
27. Mordon S, Devoisselle JM, Soulie-Begu S, *et al*. Indocyanine green: physicochemical factors affecting its fluorescence in vivo. *Microvasc Res* 1998;55:146–52.
28. Mathiessen A, Slatkowsky-Christensen B, Kvien TK, *et al*. Ultrasound-detected inflammation predicts radiographic progression in hand osteoarthritis after 5 years. *Ann Rheum Dis* 2015. Published Online First: 1 Apr 2015. doi:10.1136/annrheumdis-2015-207241


Ann Rheum Dis: first published as 10.1136/annrheumdis-2015-207345 on 26 August 2015. Downloaded from http://ard.bmj.com/ on April 18, 2024 by guest. Protected by copyright.

## Supplementary files

The approval of the study was granted by the ethics committee of the Charité – Universitätsmedizin Berlin, Germany. All study participants were informed about the examination process, risks and potential side effects of the fluorescence dye in oral and written form and signed the consent form. Clinical, musculoskeletal US and FOI examinations were performed on the same day. The study patients were recruited from the rheumatologic outpatient clinic of the Charité Universitätsmedizin – Berlin, Germany.

### Clinical and laboratory examination

In both patient groups, the presence of swollen (SJC) and tender (TJC) joints out of a 28-joint count were ascertained using a qualitative (dichotomous) score (0/1). In addition, the current disease activity was determined by observing the patient's visual analogue scale (VAS). Morning stiffness was recorded in minutes. Laboratory analysis included the erythrocyte sedimentation rate (ESR; normal <20 mm/h), C-reactive protein (CRP; normal <5 mg/l), rheumatoid factor (IgM-RF; normal <20 U/l) and antibodies to citrullinated peptide antigens (ACPA; normal <20 U/l). The DAS28 (Disease Activity Score, 28 joints) ─ including TJC, SJC, ESR and patient's visual analog scale (VAS) ─ was calculated for RA patients[22].

### Musculoskeletal ultrasound

Ultrasonographic examination of the clinically dominant hand for tenderness and/or swelling was performed in neutral position by greyscale (GSUS) and power Doppler (PDUS) ultrasound with a linear 10-18 MHz transducer. The wrist (WR; midline, radial, ulnar), the metacarpophalangeal (MCP), proximal (PIP) and distal interphalangeal (DIP) joints of the fingers II to V were examined from the palmar and dorsal view. The same machine (Mylab twice, Esaote, Genua; Italy) was used for every patient during the study in order to reduce any possible variance between different machines.

### Fluorescence optical imaging (FOI)

The FOI system Xiralite X4 (Mivenion) was utilized following a standardized procedure with an examination time of six minutes, recording one image per second and adding up to a cluster of 360 images[3,18]. A bolus of indocyanine green (ICG) as intravenous dye with a dose of 0.1mg/kg body weight was injected ten seconds after beginning image acquirement [3,18]. The enhancement in projection on the joint area was evaluated on the basis of the intensity of the affected joint area as well as on the shape and color. On this account, the semiquantitative grading system 'fluorescence optical imaging activity score' (FOIAS) was used as follows: 0 = no signal enhancement, 1 = low signal enhancement (≤25% of affected joint area), 2 = moderate signal enhancement (>25%, ≤50% of affected joint area), 3 = strong

signal enhancement (>50% of affected joint area)[3,18]. Based on the shape, signal intensities in projection on the joint area with planar, streaky and bone related shapes were evaluated (see discussion section and **Figure 1, 3**). In reference to the color, for grade 1 the enhancement varies from red with yellow spots to red signals while for grade 2 the signal intensity shows strong red color intensity in 25-50 % of the joint area. Red and white signal intensity in over 50% of the affected joint area denote grade 3 (**Figure 1**). To determine a grade, all of the described characteristics were considered[18].

### Statistical analyses

For ensuring the comparability to FOI which visualizes the wrist in its entirety, the three different plains of the wrist (midline, radial, ulnar) in US were summed up and considered on a percentage basis in regard to the three score grades. For this pilot-study, we evaluated the sum of inflammatory enhancement in the joint region in FOI and compared it to synovitis and tenosynovitis, taken together as inflammatory changes in ultrasound. On this account and to insure the comparability between the two imaging techniques anon, the frequencies per joint were totalized for synovitis and tenosynovitis as well as for the dorsal and palmar side in US.

## Results

### Demographic, clinical and laboratory data

Ninety patients were recruited for this study (67 patients with RA and 23 patients with OA). Patients were predominantly female with 79% in the RA cohort and 87% in the OA cohort. The mean age of RA patients amounted to 53 years (± 11.4, range 27-75) while the patients with OA averaged 60 years (± 9.6 range 35-72). Both cohorts showed a mean symptom duration of approximately 7 years in the RA cohort (7.1 ± 8.2, range 0.3-41.2) and in the OA cohort (7.7 ± 7.5, range 0.5-25.3). 59% of the RA patients were rheumatoid factor-positive (>20 U/ml) and 63% were ACPA-positive (>20 U/ml). On the average, the DAS28 value was 4.2 in the RA cohort (median= 4.3).

The results of the demographic, clinical and laboratory features of the study population are shown in the supplemental **Table S1**.

## Limitation of the study

We are aware of some limitations in our investigation. The cohort of RA included patients with long disease durations. At this moment, a statement to any possible secondary osteoarthritis caused by the inflammatory process of RA cannot be made. Therefore, a clear differentiation between RA patients with the appearance of osteoarthritis as a secondary degenerative process and less active RA and patients with idiopathic OA is difficult. However, the pattern of inflammatory joint distribution in the both cohorts by GSUS and

PDUS may allow a distinction. Moreover, we examined the clinically more affected hand in US and FOI independently from the patient‘s handedness. It is conceivable that tenosynovitis and degenerative changes occur more frequently in the dominant hand based on daily usage. Another limitation may be the differences of the groups in the number of patients. Additionally, the cohort size of 90 patients may be considered small and it is feasible that the study is underpowered. However, the study aimed to be a pilot project investigating OA patients in comparison to RA by fluorescence optical imaging.

At this point, we want to elaborate limitations of FOI. The considered imaging method is an invasive procedure. In our study we combined the intravenous injection of FOI with the routine blood collection. Supplementary, typical side effects of ICG which have to be considered include circulatory problems, allergy e.g. iodine allergy as well as discoloration of urine and stool. A good function of liver and kidneys should be contemplated before starting the investigation. To our experience, most side effects are caused by the intravenous needle and manifest themselves as circulatory problems. Furthermore, at this moment, only the dorsal side of the hands can be investigated by FOI leading to the assumption that anatomic structures with overlay may influence the detection of inflammation on the palmar side of the hands. Additional diodes and cameras may resolve this issue[18].

The invasive procedure is faced with the advantages of FOI obtaining an overall view of all finger joints and both wrists in six minutes. It gives the opportunity to objectify arthralgia. FOI can further be performed by assisting staff under medical supervision.

**Table S1** **Demographic, clinical and laboratory data of study population**

| | RA (n = 67) | | | | | OA (n = 23) | | | | |
|---|---|---|---|---|---|---|---|---|---|---|
| | n/% | mean ±SD | | median (range) | | n/% | mean ±SD | | median (range) | |
| **Gender** | | | | | | | | | | |
| **female** | 53 / 79 | | | | | 20 / 87 | | | | |
| **male** | 14 / 21 | | | | | 3 / 13 | | | | |
| **Age (years)** | | 53 | ± 11.4 | 54 | (27-75) | | 60 | ± 9.6 | 61 | (35-72) |
| **Symptom duration (years)** | | 7.1 | ± 8.2 | 4.8 | (0.3-41.2) | | 7.7 | ± 7.5 | 4.0 | (0.5-25.3) |
| **DAS28** | | 4.2 | ± 1.3 | 4.3 | (1.4-7.4) | | | | | |
| **positive RF (U/ml)** | 39 / 59 | | | 58.9 | | | | | | |
| **positive ACPA (U/ml)** | 42 / 63 | | | 51.6 | | | | | | |
| **ESR (mm/h)** | | 25 | ± 22.6 | 17 | (1-98) | | 14.9 | ± 16.0 | 9 | (1-56) |
| **CRP (mg/l)** | | 8.7 | ± 14.2 | 4.0 | (0.3-77.9) | | 1.9 | ± 2.4 | 0.9 | (0.3-10.8) |
| **TJC (0-28)** | | 5.5 | ± 5.6 | 4 | (0-22) | | 2.7 | ± 2.7 | 2 | (0-9) |
| **SJC (0-28)** | | 3.7 | ± 4.0 | 3 | (0-20) | | 1.1 | ± 1.6 | 0 | (0-5) |
| **Patient VAS (0-100mm)** | | 51.9 | ± 22.3 | 50 | (5-100) | | 40.3 | ± 19.4 | 40 | (0-70) |
| **Morning stiffness (min)** | | 59.1 | ± 117.1 | 30.0 | (0-720) | | 48.9 | ± 145.7 | 10.0 | (0-720) |

* RA = Rheumatoid Arthritis; OA = Osteoarthritis; DAS28 = Disease Activity Score of 28-joint assessment; RF = rheumatoid factor (positive titer ≥ 20 U/ml); ACPA = Anti-citrullinated protein antibodies (positive titer ≥ 20 U/ml); ESR = erythrocyte sedimentation rate (positive ≥ 20mm/h); CRP = C-reactive protein (positive ≥ 5mg/l); TJC = tender joint count; SJC = swollen joint count; Patient VAS = patients' visual analog scale

Figure S1a-d: Frequency grades 1-3 for RA and OA in US and FOI per joint group. The graphs show MCP joints for RA and DIP joints for OA in the lead in both imaging methods considering inflammatory changes. For wrist and PIP joints differences can be seen on closer examination.

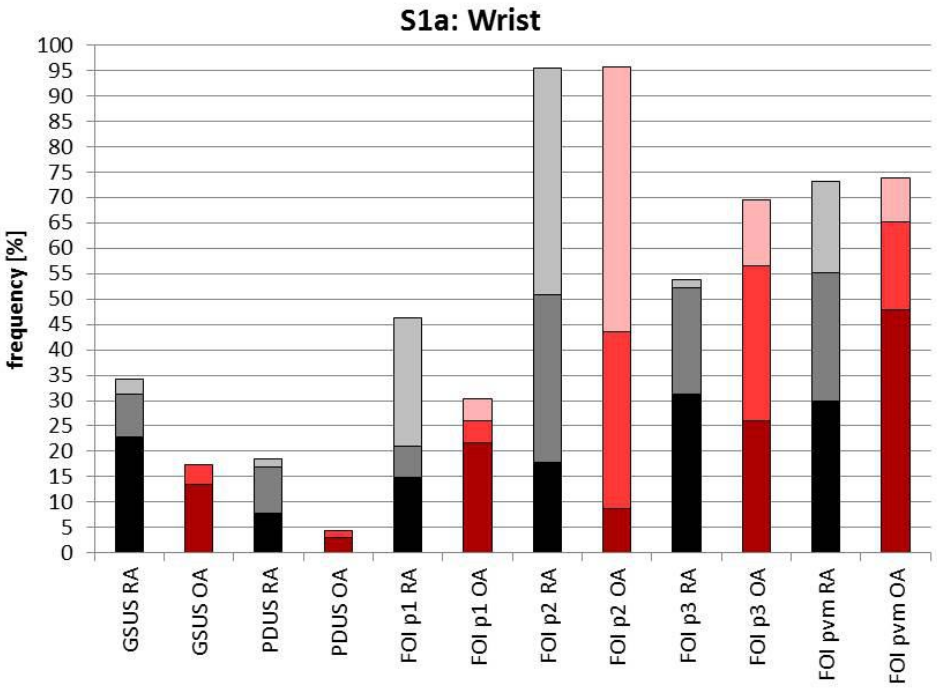


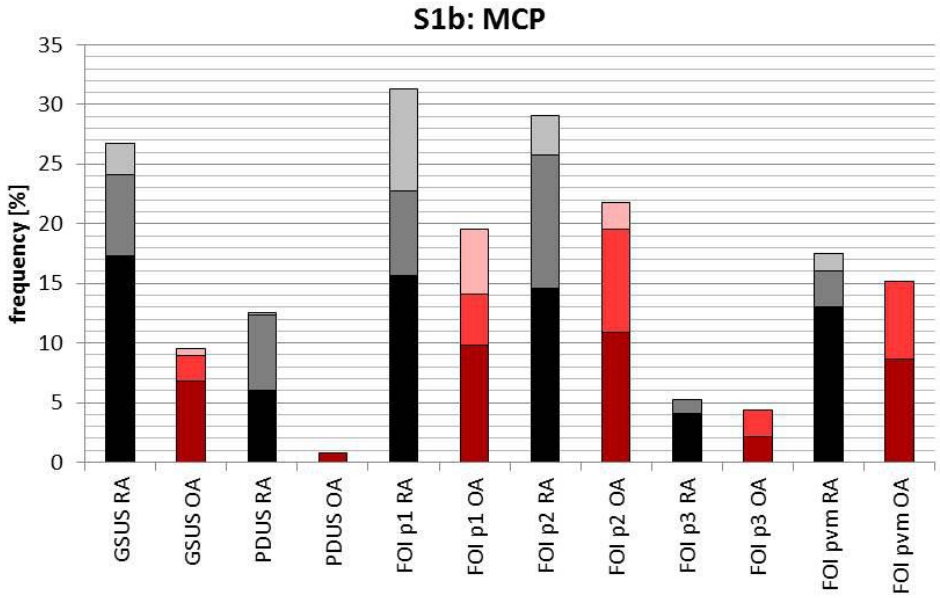

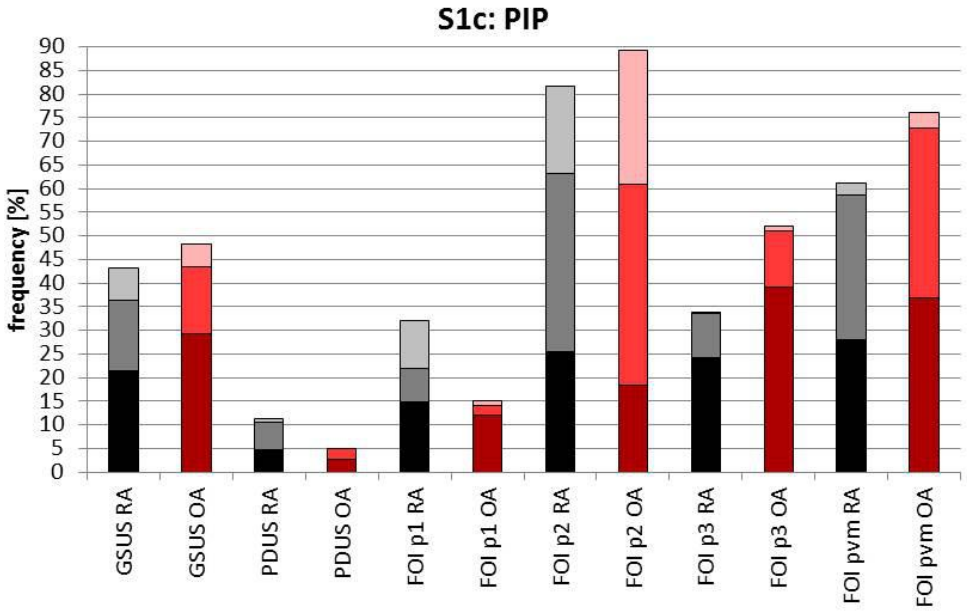
S1c: PIP
frequency [%]
90
85
80
75
70
65
60
55
50
45
40
35
30
25
20
15
10
5
0
GSUS RA
GSUS OA
PDUS RA
PDUS OA
FOI p1 RA
FOI p1 OA
FOI p2 RA
FOI p2 OA
FOI p3 RA
FOI p3 OA
FOI pvm RA
FOI pvm OA

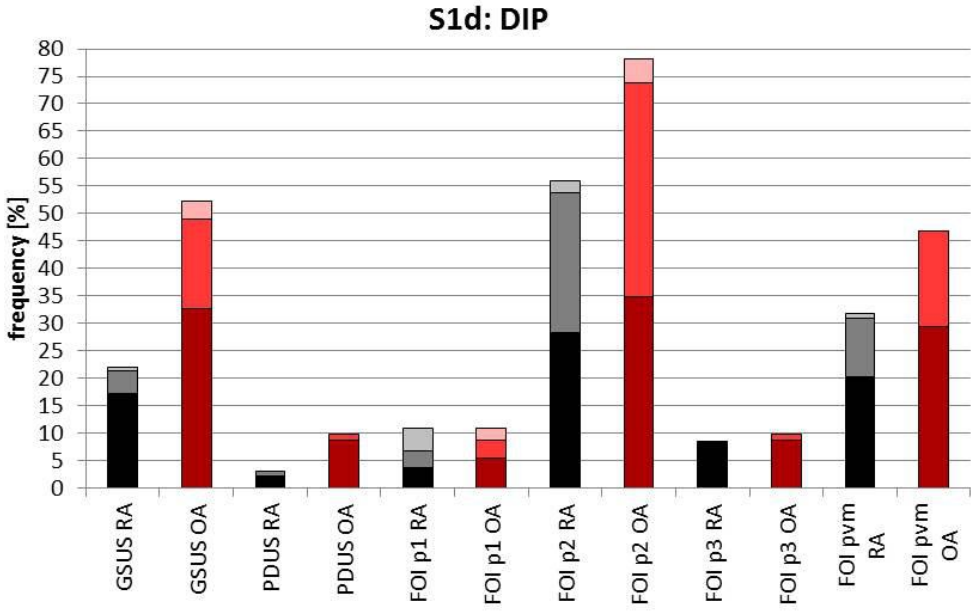
S1d: DIP
frequency [%]
80
75
70
65
60
55
50
45
40
35
30
25
20
15
10
5
0
GSUS RA
GSUS OA
PDUS RA
PDUS OA
FOI p1 RA
FOI p1 OA
FOI p2 RA
FOI p2 OA
FOI p3 RA
FOI p3 OA
FOI pvm RA
FOI pvm OA

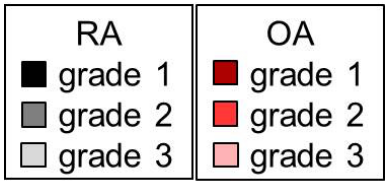
RA
grade 1
grade 2
grade 3
OA
grade 1
grade 2
grade 3

Figure S2a-b: Phase 1 in FOI. a) FOI shows high signal intensities in PIP, MCP and wrist in both hands early in phase 1 imprinting high inflammation in RA. b) Early and planar signal in right PIP IV denoting active inflammation in OA.

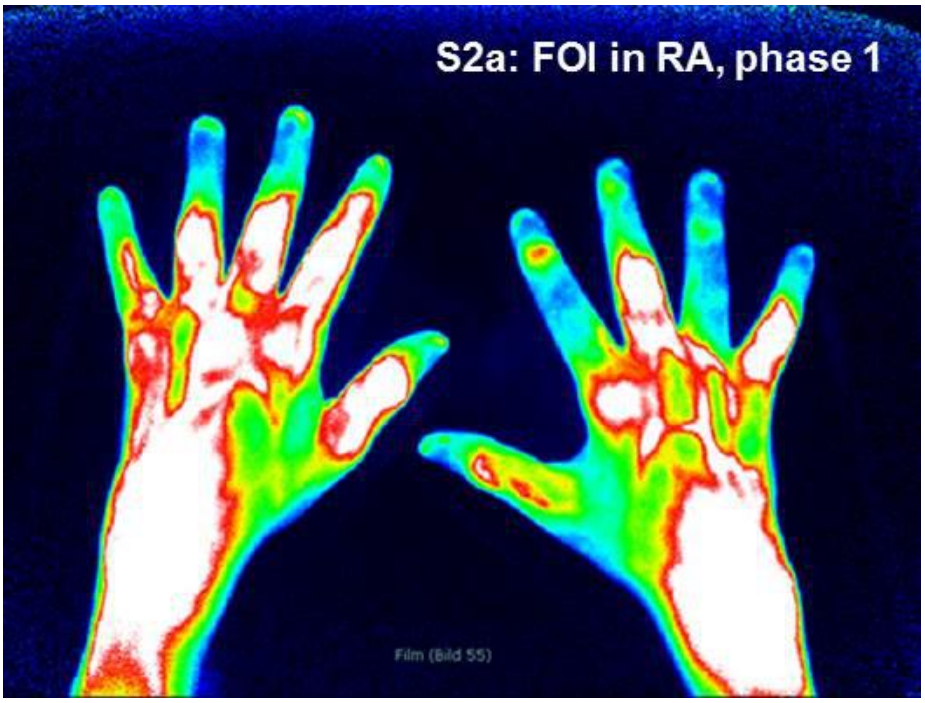


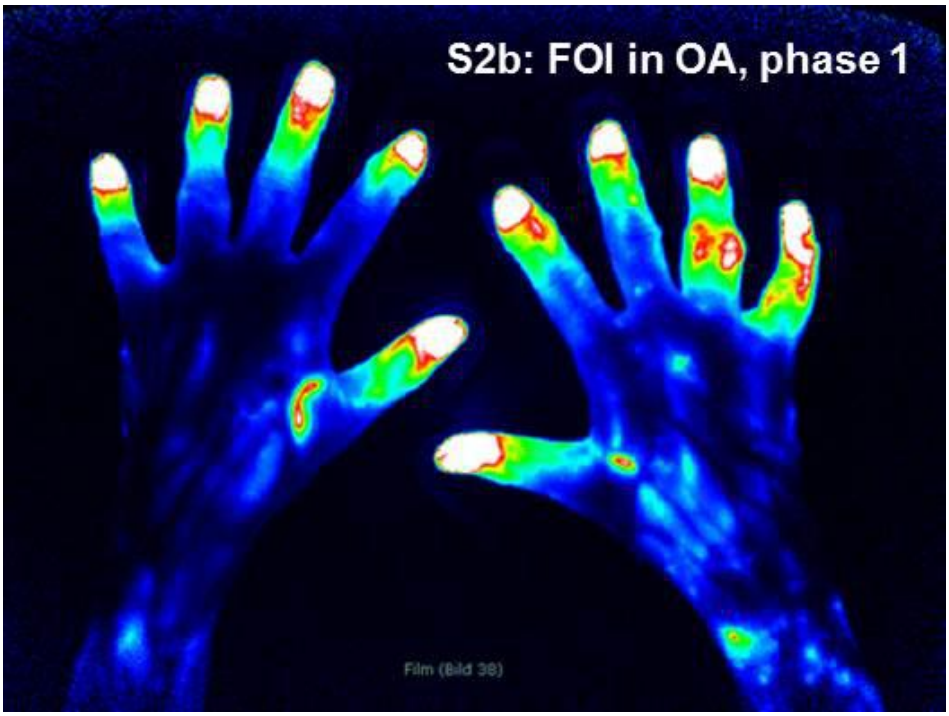
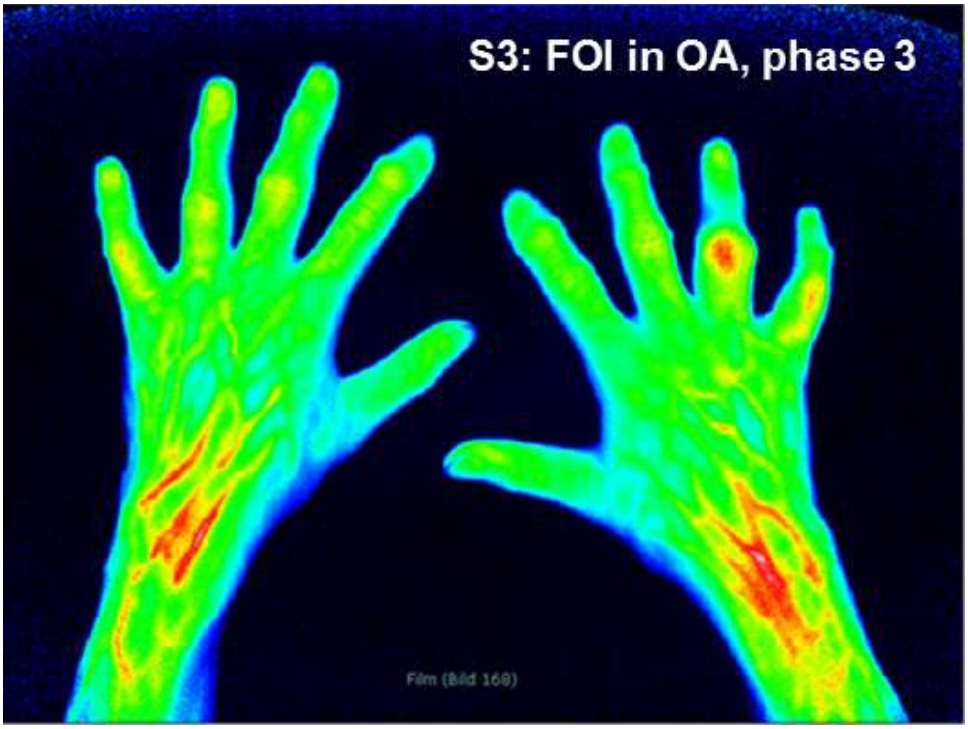
Figure S3: Phase 3 in FOI in OA patient. Remaining FOI signals in PIP IV.