

## MATTERS ARISING

### Pulsed electromagnetic field therapy in the management of knee OA

It seems most unusual that in a review of "all currently available treatments" for knee osteoarthritis (OA) by 21 authorities and "two experts in the field of guidelines methodology", pulsed electromagnetic field therapy was not mentioned in the text or the 51 references.<sup>1</sup> This is particularly troubling because over 2800 publications between 1966 and 1998 were retrieved. An identical search for efficacy of magnetic field therapy during this period listed 31 studies with at least one control group,<sup>2</sup> including two double blind trials citing benefits in knee OA from a peer reviewed arthritis journal.<sup>3,4</sup> In 1999 over 50 000 patients received pulsed signal therapy (PST) prescribed by over 1000 doctors at more than 300 clinics and hospitals in 16 countries, where it is usually reimbursed by fiscal intermediaries because of its proven record of cost effectiveness and safety. A summary of PST double blind and randomised study results in over 50 000 patients has been published,<sup>5</sup> and findings in 100 000 patients (the vast majority with knee OA) have also been reported at recent international conferences.<sup>6,7</sup> Although "alternative" remedies, ranging from minerals, vitamins, nutritional supplements, and capsaicin and diclofenac gels to sex hormones were discussed, in contrast with PST, none satisfied the category criteria the panel established to determine strong recommendation. Nor do any have the solid basic science studies that PST provides with its *in vitro* support for mechanisms of action to explain efficacy based on proteoglycan synthesis and chondrocyte stimulation results.<sup>8,9</sup>

Pulsed signal therapy is the result of three decades of research designed to characterise the piezoelectric signal that normally stimulates chondrocyte activity by creating a streaming potential in the extracellular matrix when bone is subjected to pressure. Although the transmission of this signal is impaired in OA, PST can reproduce this streaming potential in affected joints under no load, and the nine one-hour daily non-invasive treatments are devoid of any adverse side effects. Long term follow up confirms sustained pain relief, improved mobility, and a high safety profile as assessed by validated instruments (WOMAC, OMERAC, modified Ritchie scales) as well as evaluations by doctors and patients.

My interest in PST began in 1995 when a *Journal of Rheumatology* article suggested that it might alleviate my 15 year old daughter's pain caused by an arthritic condition. Although unable to walk without crutches, two weeks after a course of PST her pain was relieved and she could walk unassisted. A month later she was able to pursue all athletic activities without discomfort. She subsequently enrolled in a martial arts class, recently attained black belt status, and has continued to remain symptom free without the need for any drugs or further treatment for the past five years.

Although I am certified in cardiology and gastroenterology, a significant portion of my practice is now devoted to exploring how PST achieves its benefits.<sup>10</sup> I have treated 1000 patients, most of whom had knee OA, with very gratifying results similar to those reported in the literature. The panel cited two prior efforts to establish guidelines for treating knee OA, emphasising that these "primarily represent consensus statements from expert panels" and "The type and strength of evidence to support such guidelines remain unclear." Their stated objective, therefore, was to "develop guidelines relating to clinical issues in OA management, and to indicate clearly the level of evidence to support individual statements". However, electromagnetic therapy approaches were again omitted, though at least one of the members is quite familiar with PST. The reason for this exclusion is not clear and I believe that your readership deserves to be aware of this extremely safe and effective option.

K PFEIFFER  
Augsburgerstr 4,  
80337 München,  
Germany

- 1 Pendleton A, Arden N, Dougados M, Doherty M, Bannwarth B, Bijlsma JWJ, *et al*. EULAR recommendations for the management of knee osteoarthritis: report of a task force of the Standing Committee for International Clinical Studies Including Therapeutic Trials (ESCI-SIT). *Ann Rheum Dis* 2000;59:936-44.
- 2 Quittan M, Schuhfried O, Wiesinger GF, Fialka-Moser V. Clinical effectiveness of magnetic field therapy—a review of the literature. *Acta Med Austriaca* 2000;27:61-8.
- 3 Trock DH, Bollet AJ, Markoll R. The effect of pulsed electromagnetic fields in the treatment of osteoarthritis of the knee and cervical spine. Report of randomized, double blind, placebo controlled trials. *J Rheumatol* 1994;21:1903-11.
- 4 Trock DH, Bollet AJ, Dyer RH Jr, Fielding LP, Miner WK, Markoll R. A double-blind trial of the clinical effects of pulsed electromagnetic fields in osteoarthritis. *J Rheumatol* 1993;20:456-60.
- 5 Markoll R. Pulsed signal therapy for the treatment of osteoarthritis: double blind and randomized study results in over 50,000 patients. *Ann Rheum Dis* 2000;59(suppl 1):131.
- 6 Markoll R. Pulsed signal therapy for the treatment of osteoarthritis: double blind and randomized study results in over 50,000 patients. *The Bioelectromagnetics Society 22nd Annual Meeting Abstracts Book*, 2000:76.
- 7 Markoll R. Clinical trial results of pulsed signal therapy in over 100,000 patients with osteoarthritis and evidence of efficacy in TMJ syndrome and tinnitus: supportive *in vitro* cartilage and chondrocyte stimulation studies. *The Eleventh International Congress on Stress Abstracts Book*, 2000.
- 8 Nerucci A, Marcolongo R, Markoll R. Pulsed signal therapy (PST) enhances proteoglycan concentrations in human chondrocyte cultures. *The Bioelectromagnetics Society 22nd Annual Meeting Abstracts Book*, 2000:48.
- 9 Gierse H, Breul R, Faensen M, Markoll R. Pulsed signal therapy (PST) stimulates mitosis of human chondrocytes in culture. *Proceedings tenth international conference on biochemical engineering*, Singapore 2000, Singapore: Humanitas Press, 2000:473-4.
- 10 Pfeiffer K. Changes in Kirlian photography energy fields following pulsed signal therapy. *The Eleventh International Congress on Stress Abstracts Book*, 2000.

### Authors' reply

We thank Dr Pfeiffer for raising this point. The EULAR recommendations for the management of knee osteoarthritis<sup>1</sup> combined an evidence based approach and a consensus approach. The evidence based approach—that is, the literature research, was only applied for the treatment modalities selected

by the experts at the first meeting of the committee (see table 1 of the paper).

Pulsed electromagnetic field therapy, with other less commonly used interventions, was not included in this list, and its evidence for efficacy was therefore not assessed. However, as emphasised by Dr Pfeiffer, an evidence based evaluation of all other interventions would be of interest and could be considered for inclusion in the next round of evidence based guidelines.

M DOUGADOS  
Clinique de Rhumatologie B,  
Groupe Hospitalier Cochin,  
27 rue du Faubourg St Jacques,  
75679 Paris CEDEX 14,  
France

M DOHERTY  
Rheumatology Unit,  
City Hospital, Nottingham NG5 1PB, UK

- 1 Pendleton A, Arden N, Dougados M, Doherty M, Bannwarth B, Bijlsma JWJ, *et al*. EULAR recommendations for the management of knee osteoarthritis: report of a task force of the Standing Committee for International Clinical Studies Including Therapeutic Trials (ESCI-SIT). *Ann Rheum Dis* 2000;59:936-44.

### Treatment of women with aPL in pregnancy

I read with much interest the article of Derksen *et al* in the January issue of the *Annals of the Rheumatic Diseases*.<sup>1</sup> The authors gave a detailed introduction to the difficult field of treatment of pregnant patients with antiphospholipid syndrome (APS). Despite the presence of only a limited amount of data from controlled studies the authors gave helpful recommendations for the daily management of these patients.

However, there is a major concern with which I would like to deal. As we know the success of treatment of APS with oral anticoagulants very much depends on the strictness with which the dose is adjusted to the international normalised ratio. The authors rightly suggest changing from oral anticoagulants to subcutaneous low molecular weight heparin in pregnant patients with APS. However, I believe that the dose of low molecular weight heparin has to be adjusted in individual patients.

The measurement of anti-factor Xa activity in plasma enables us to calculate the dose of low molecular weight heparin which is needed to achieve optimal inhibition of the coagulation cascade. Values of 0.6–1.0 U/ml are believed to give maximum protection against thromboembolic events.

From my experience the optimal dose of low molecular weight heparin may be different in different patients. Moreover, a dose given once daily rarely guarantees the desired value of anti-factor Xa activity and often a second injection has to be applied to achieve optimal effect. Therefore, as long as controlled data are missing I would suggest that the measurement of anti-factor Xa activity in pregnant patients with APS should be used to adjust the dose of low molecular weight heparin. This may result in better protection of mother and fetus in this disease.

C FIEHN  
Rheumatology Outpatient Unit,  
University Hospital of Heidelberg,  
Germany

christoph\_fiehn@med.uni-heidelberg.de

1 Derksen RHW, de Groot PhG, Nieuwenhuis HK, Christiaens GCML. How to treat women with antiphospholipid antibodies in pregnancy? *Ann Rheum Dis* 2001;60:1-3.

## Authors' reply

We thank Dr Fiehn for his interest and comments on our recent leader in the *Annals*.<sup>1</sup> At present, there are insufficient data from randomised trials to give evidence based guidelines for optimal (prophylactic) treatment of many of the clinical manifestations of the antiphospholipid syndrome (APS). This not only holds for prevention of pregnancy related complications, the topic of our leader, but also for treatment of thrombosis related to antiphospholipid antibodies.<sup>2</sup>

The major issue raised by Dr Fiehn is that he believes that in patients with APS one should use adjusted, not fixed, doses of low molecular weight heparin (LMWH). It is well known that anti-Xa activity relates to anti-thrombotic effects of LMWHs, and that the amount of LMWH needed to achieve and maintain a certain range of anti-Xa activity increases during the course of pregnancy. In most patients dose adjustment is needed in the second trimester and, in some, in the third trimester (mean (SD) 20.5 (8.2) weeks), but individual patients vary widely in the time when the dose of LMWH needs to be adjusted from once to twice daily.<sup>3</sup> Despite this, there is so far no clinical proof that for thromboprophylaxis in pregnancy or prevention of poor pregnancy outcome an adjusted dose LMWH (with cumbersome and costly monthly monitoring of pre- and/or post-injection anti-Xa activity) is better than a fixed dose based on body weight.<sup>4,5</sup> Therefore, we do not share Dr Fiehn's view that one should advise adjusted doses of LMWH in all pregnant patients with APS.

R H W M DERKSEN

*Department of Rheumatology and Clinical Immunology,  
University Medical Centre Utrecht,  
The Netherlands*

P G DE GROOT

*Department of Haematology*

H K NIEUWENHUIS

*Department of Obstetrics and Gynaecology*

G C M L CHRISTIAENS

*Haemostasis and Thrombosis Laboratory*

- 1 Derksen RHW, de Groot PhG, Nieuwenhuis HK, Christiaens GCML. How to treat women with antiphospholipid antibodies in pregnancy? *Ann Rheum Dis* 2001;60:1-3.
- 2 Derksen RHW, de Groot PhG. Do we know which patients with the antiphospholipid syndrome should receive long-term high dose anticoagulation? *J Autoimmun* 2000;15:255-9.
- 3 Hunt BJ, Doughty H, Majumdar G, Coppstone A, Kerslake S, Buchanan N, et al. Thromboprophylaxis with low molecular weight heparin (fragmin) in high risk pregnancies. *Thromb Haemost* 1997;77:39-43.
- 4 Sanson B, Lensing AWA, Prins MH, Ginsberg JS, Barkagan ZS, Lavenne E, et al. Safety of low-molecular-weight heparin in pregnancy: a systematic review. *Thromb Haemost* 1999;81:668-72.
- 5 Greer IA. Thrombosis in pregnancy: maternal and fetal issues. *Lancet* 1999;353:1258-65.

## Caudal epidural injections

Price *et al* recommend that caudal epidural injections should be carried out with x ray screening.<sup>1</sup> In practice the technique is often

performed in the outpatient clinic, where screening facilities are not usually available.

I have reviewed the outcome of 44 unscreened caudal epidural injections given to 34 patients in my outpatient clinic in the 12 months from July 1999 to June 2000. Patient selection was principally on the basis of unilateral nerve root pain in the leg in the presence of symmetrical straight leg raising. However, nine patients had asymmetrically reduced straight leg raising and four of those with full straight leg raising had pain in the L4 dermatome, mostly with a positive femoral nerve stretch test on the affected side. Spinal mobility and the presence or absence of a neurological deficit did not influence the decision to offer an epidural injection.

The procedure was carried out with the patient lying prone on the examination couch. After thorough skin preparation and a local injection of 2 ml lidocaine (lignocaine) 2%, 40 mg triamcinolone hexacetonide mixed with 10 ml lidocaine 0.5% and 10 ml normal saline was injected into the epidural space through the sacral hiatus with a 20G spinal needle. The patient was subsequently kept prone for 30 minutes and remained horizontal for a total of 60 minutes before being allowed home.

Six of the patients were subsequently given a second epidural injection and two of them received three in the 12 month period. The procedure was repeated only if there was a satisfactory response to the original injection.

For the purpose of this audit, outcomes were graded as:

- 1 Complete or substantial relief of root symptoms for a minimum of three months.
- 2 Temporary relief for between one week and three months.
- 3 A sustained partial response (up to 50% reduction in pain).
- 4 No response (negligible pain relief or pain reduced for less than one week).

After the first epidural injection, 13 patients were cured of their root pain or obtained relief for three months or more, six derived temporary relief, four partial relief, and 10 showed no response. One of the non-responders was subsequently deemed to have Achilles tendinitis rather than S1 root pain. The outcome in the remaining case is unknown as the patient defaulted from follow up.

Of the eight patients who received a second epidural injection, three were cured or had sustained relief, three partial relief, and two did not respond (despite previous satisfactory responses for four and nine months, respectively). Of the two patients who were given a third epidural injection, one enjoyed sustained relief of pain while the other had temporary relief for six to eight weeks.

In brief, 23/34 (68%) of patients experienced at least a temporary or partial response to the initial unscreened caudal epidural injection and of the eight patients who were given either two or three epidural injections, four obtained sustained relief from their leg pain.

There were no complications from the procedure.

On further analysis of the results, 68% of patients with full straight leg raising showed at least a temporary response to the first epidural injection compared with 44% of those with asymmetrically reduced straight leg raising. Of patients with a neurological deficit, 85% experienced at least temporary pain relief.

Sixteen patients (47%) were ultimately referred to the chronic pain management services for nerve root blocks and three (9%)

for a surgical opinion on the basis of the results of a magnetic resonance imaging scan of their lumbar spine.

Although x ray guidance theoretically might improve the accuracy of placement of the spinal needle, these results show that caudal epidural injections can be carried out safely and effectively in an outpatient setting without radiological screening. This also ensures prompt treatment for the patient.

N J SHEEHAN

*Department of Rheumatology,  
Edith Cavell Hospital,  
Bretton Gate,  
Peterborough PE3 9GZ, UK*

njsheehan@doctors.org.uk

- 1 Price CM, Rogers PD, Prosser ASJ, Arden NK. Comparison of the caudal and lumbar approaches to the epidural space. *Ann Rheum Dis* 2000;59:879-82.

## Authors' reply

Dr Sheehan's letter describes an audit of the efficacy of caudal epidural injections. His audit clearly describes outpatient caudal epidural injections as being well tolerated and safe.

The main issue of our paper was not safety, however, rather that a high proportion of caudal epidural injections are incorrectly placed and therefore unlikely to be of any therapeutic benefit. Effectiveness is less clearly shown by Dr Sheehan's audit as he has no control group. It is well known from the epidemiological studies of sciatica, that most patients will improve spontaneously with time alone. The degree of improvements in the audit is not dissimilar to that expected from the natural history of the condition. It is therefore difficult to state that the caudal epidural injections were effective. Certainly it is not possible from this audit to state that screened epidural injections would not be more effective.

C PRICE

N ARDEN

*Pain Clinic,*

*Royal South Hants Hospital,*

*Southampton University Hospitals NHS Trust,*

*Brinton's Terrace,*

*Southampton, Hampshire*

## Interleukin 1 gene polymorphisms

I read with interest the recent article by Crilly and colleagues<sup>1</sup> on the potential use of interleukin 1 (IL1) gene polymorphisms in predicting the need for joint surgery in patients with rheumatoid arthritis. Although the authors' findings are certainly interesting and worthy of further investigation, I would like to raise a couple of points as to how these were arrived at in the first place.

When adopting the "candidate gene" approach in any disease association study, it pays to consider carefully the physiological context of a hypothesis. In this case the authors worked on the premise that one of the IL1 gene family polymorphisms investigated might correlate with disease outcome. These included polymorphisms both in the IL1 genes and the IL1 receptor antagonist (IL1ra) locus. The IL1ra is unique in being the only known endogenous cytokine receptor antagonist. The genes encoding IL1 $\alpha$ ,  $\beta$

and the IL1ra have co-evolved as a cytokine control mechanism<sup>2</sup>: agents eliciting IL1 production generally induce IL1ra gene transcription as well, either directly or through a feedback loop triggered by IL1 itself. IL1ra competes with IL1 for binding to the cognate receptor, but produces no known signalling events upon binding. Additionally, one of the two IL1 receptors, type II, also lacks any known signalling capacity and is thought to function as a decoy binding site. If it is assumed that polymorphisms found in various members of the IL1 gene family modify gene function then the implication is that they should be studied collectively, not individually. In support of this argument comes recent experimental evidence showing that plasma IL1ra levels are determined by allelic combinations within the IL1 gene family,<sup>3</sup> as well as evidence for linkage disequilibrium between polymorphic markers spread across the IL1 gene family locus.<sup>4</sup> It is fair to say that Crilly and colleagues did allude in their paper to the possible existence of an extended IL1 gene family haplotype. However, there is already sufficient published evidence<sup>5-6</sup> to justify examination of haplotypic combinations of the investigated alleles in population studies.

On a different note, although the authors' argument about the validity of surgery as a study end point is convincing, their selection of a 15 year disease duration free from surgery as the cut off time point for this study seems dubious. A previous study by the same group had calculated that the median disease duration before surgery was 14.6 years, implying that there are a substantial number of patients in the "no surgery" group who will require surgery shortly after the 15 year time point, thereby potentially confounding any significant statistical findings. One might argue that the aim of this study was not to differentiate between patients that will or will not require surgery but, rather, to differentiate between rapid (<15 years) versus delayed (>15 years to surgery) disease progression. Even so, a more valid statistical approach might have been to analyse all patients as a single group and try to correlate genotype (or haplotype) with disease duration to surgery.

J VAMVAKOPOULOS  
University Department of Surgery,  
Addenbrooke's Hospital,  
Cambridge, UK

- Crilly A, Maiden N, Capell HA, Madhok R. Predictive value of interleukin 1 gene polymorphisms for surgery. *Ann Rheum Dis* 2000;59:695-9.
- Eisenberg SP, Brewer MT, Verderber E, Heimdal P, Brandhuber BJ, Thompson RC. Interleukin 1 receptor antagonist is a member of the interleukin 1 gene family: evolution of a cytokine control mechanism. *Proc Natl Acad Sci USA* 1991;88:5232-6.
- Hurme M, Santtila S. IL-1 receptor antagonist (IL-1Ra) plasma levels are co-ordinately regulated by both IL-1Ra and IL-1beta genes. *Eur J Immunol* 1998;28:2598-602.
- Cox A, Camp NJ, Nicklin MJH, di Giovine FS, Duff GW. An analysis of linkage disequilibrium in the interleukin-1 gene cluster, using a novel grouping method for multiallelic markers. *Am J Hum Genet* 1998;62:1180-8.
- Wilkinson RJ, Patel P, Llewelyn M, Hirsch CS, Pasvol G, Snounou G, et al. Influence of polymorphism in the genes for the interleukin (IL)-1 receptor antagonist and IL-1beta on tuberculosis. *J Exp Med* 1999;189:1863-73.
- El-Omar EM, Carrington M, Chow W-H, McColl KE, Bream JH, Young HA, et al. Interleukin-1 polymorphisms associated with increased risk of gastric cancer. *Nature* 2000;404:398-40.

## Author's reply

I thank Dr Vamvakopoulos for his interest in our article<sup>1</sup> and would like to make the following response.

We agree that testing for haplotype combinations of the interleukin 1 (IL1) gene family allele would be useful. However, for a large number of alleles to be tested a considerable sample size would be needed to correct for multiple allele testing. This would require a multicentre study; this is limited by funding constraints.

Secondly, for the statistical analysis we predefined early and late surgery. Analysis was undertaken after discussion with a qualified medical statistician. Should the correspondent wish to analyse our data, we would be happy to allow access if guarantees can be provided.

R MADHOK  
Centre for Rheumatic Diseases,  
Glasgow Royal Infirmary,  
84 Castle Street,  
Glasgow G4 0SF, UK

- Crilly A, Maiden N, Capell HA, Madhok R. Predictive value of interleukin 1 gene polymorphisms for surgery. *Ann Rheum Dis* 2000;59:695-9.

## LETTERS TO THE EDITOR

### A case of shingles mimicking carpal tunnel syndrome

A 59 year old woman with an eight year history of seropositive erosive rheumatoid arthritis (RA) receiving sulfasalazine and penicillamine presented with severe sudden onset pain radiating from the left elbow to the left thumb, index and middle fingers. Examination disclosed synovitis of the left wrist, which might have caused median nerve compression. The wrist joint was injected with 20 mg of triamcinolone acetate with 1% lidocaine (lignocaine). She returned the following morning complaining of worsening pain. She was clinically well with no fever. White cell count was normal, but the erythrocyte sedimentation rate (ESR) was raised at 73 mm/1st h. A transcutaneous nerve-stimulating (TENS) machine was applied and she was prescribed amitriptyline 25 mg at night. The following day she had improved significantly but had developed a vesicular rash in the C6 dermatome consistent with herpes zoster infection (fig 1). Viral titres were consistent with current varicella zoster infection.

#### DISCUSSION

Establishing the cause of pain in patients with RA can be notoriously difficult. In addition to the psychological factors that influence pain perception, wrist and hand pain may result from rheumatoid synovitis, soft tissue inflammation, or mechanical nerve compression at wrist, elbow, and cervical spine.

Herpes zoster infection is heralded by burning discomfort in a dermatomal distribution, which may occur for up to five days

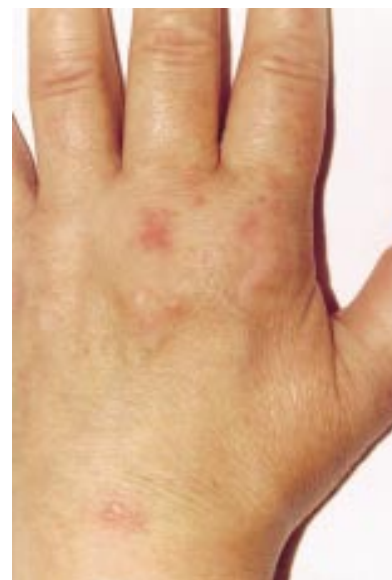

Figure 1 Vesicular rash in the C6 dermatome of the left hand.

before the onset of the typical rash. Cervical dermatomes are affected in up to 15% of patients<sup>1</sup> and may result in diaphragmatic paralysis and lower motor neurone paresis.<sup>2</sup> In this case the occurrence of prodromal symptoms of herpes zoster mimicked the symptoms of carpal tunnel syndrome, presumed secondary to RA synovitis.

RA increases the risk of herpes zoster infection.<sup>3</sup> In one series the use of low dose methotrexate, long duration of disease, and seropositivity were risk factors for subsequent infection.<sup>4</sup> Gold treatment may also increase the likelihood of shingles.<sup>5</sup>

Immunocompromised patients should receive acyclovir early to avoid viral dissemination. In patients with RA the complexity of the differential diagnosis may delay diagnosis unless the possibility of herpes zoster infection is kept in mind.

Conflict of interest: none.

H WILSON  
J HAMILTON  
R MADHOK  
Centre for Rheumatic Diseases,  
University Department of Medicine,  
Glasgow Royal Infirmary,  
Glasgow G31 2ER, UK

Correspondence to: Dr H Wilson  
hilary@jings.com

- M Aminoff. *Neurology and general medicine*. 2nd ed. Edinburgh: Churchill Livingstone, 1995.
- Soler JJ, Perpina M, Alfaro A. Hemidiaphragmatic paralysis caused by cervical herpes zoster. *Respiration* 1996;63:403-6.
- Ragozzino MW, Kurland LT. Subsequent risk of rheumatoid arthritis in patients diagnosed with herpes zoster [letter]. *Lancet* 1982;ii:884.
- Antonelli MA, Moreland LW, Brick JE. Herpes zoster in patients with rheumatoid arthritis treated with weekly low dose methotrexate. *Am J Med* 1991;90:295-8.
- Fam AG, Paton TW, Cowan DH. Herpes zoster during gold therapy [letter]. *Ann Intern Med* 1981;94:712-13.

### Azathioprine hypersensitivity

Systemic hypersensitivity is a rare but documented side effect of azathioprine. The commoner adverse effects of azathioprine include

fevers, gastrointestinal disturbances of nausea and vomiting, granulocytopenia, and hepatocellular injury.<sup>1</sup> More rarely, hypersensitivity can present with features of severe systemic infection and end organ dysfunction.<sup>2-5</sup> Azathioprine is a commonly used immunosuppressive drug and is used in many medical specialties. Therefore recognising azathioprine hypersensitivity is important for all doctors. We report a case in which we suspect such an azathioprine hypersensitivity reaction.

A 32 year old Asian woman with mixed connective tissue disorder presented with a one day history of general malaise, fevers, and painful digits. Fourteen days earlier treatment had been started with azathioprine 50 mg daily, and her prednisolone increased from 5 mg to 15 mg daily owing to the development of proteinuria (1.5 g on 24 hour urine collection) and urticarial vasculitis on her lower legs.

On examination she was shocked, with a blood pressure of 70/30 mm Hg and had marked acrocyanosis (fig 1). The differential diagnosis included a lupus crisis or septic shock. She was treated in the intensive care

unit with intravenous ceftriaxone, metronidazole, and prostacyclin for digital ischaemia after serial cultures were taken from all major sites. Staphylococcal toxic shock was excluded, with no growth on vaginal swabs and a negative staphylococcal toxin test. After negative cultures 1 g methylprednisolone was given for a possible flare up of her connective tissue disease. The azathioprine was discontinued. She improved despite concomitant intravascular coagulation. Multiple cultures from all sites did not identify any source of sepsis.

We suspected azathioprine hypersensitivity owing to:

- The timing of the patient's illness in relation to the initiation of azathioprine
- The presence of recognised features of hypersensitivity—fever, chills, diarrhoea, hypotension, and hepatic dysfunction
- The effect of rechallenge. Three weeks after the presenting episode, one dose of azathioprine 25 mg was given for steroid-sparing effect (the initial illness was attributed to disease flare up); the patient had a more severe and rapid hypersensitivity

response requiring treatment with inotropes and haemofiltration in intensive care.

She improved after treatment with high dose corticosteroids. No cultures ever isolated an infective source.

This case shows the importance of recognising azathioprine hypersensitivity. Approximately 50 cases have been reported in patients with immune mediated diseases such as inflammatory bowel disease, multiple sclerosis, and immune thrombocytopenias, where the initial illness is often ascribed to sepsis or reactivation of underlying disease. Most reactions occur in the first four weeks of drug initiation.<sup>6</sup> Hypersensitivity should always be included in the differential of fever, hypotension, and renal failure. The case was reported to the Committee on Safety of Medicines (United Kingdom).

The mechanism of the reaction is unclear. Azathioprine is composed of a nitroimidazole attached to 6-mercaptopurine. It is proposed that the imidazole component causes hypersensitivity, while the 6-mercaptopurine may cause haematological side effects. However, there are conflicting reports about the component of the drug to which the hypersensitivity reaction can be attributed.<sup>7-8</sup> Fields reviewed 49 cases, where the reaction occurred equally in men and women, aged 16–76 years, and there was a wide variation in azathioprine doses.<sup>6</sup> All patients who developed shock were also taking corticosteroids.

Support for an allergic reaction is that it occurs in only a small percentage of patients,<sup>5,6</sup> and the event recurs with drug rechallenge, as occurred inadvertently in our patient. Rechallenge with azathioprine is therefore dangerous and should be done under careful observation. A hapten from the imidazole component may bind to a protein molecule to elicit type 1 hypersensitivity.<sup>9</sup> Reactions mimicking sepsis may result from increased production of mediators such as tumour necrosis factor.<sup>10</sup>

N SOFAT

J HOUGHTON

J MCHALE

C S HIGGINS

Northwest London Hospitals NHS Trust,  
Northwick Park Hospital, Watford Road,  
Harrow HA1 3UJ, UK

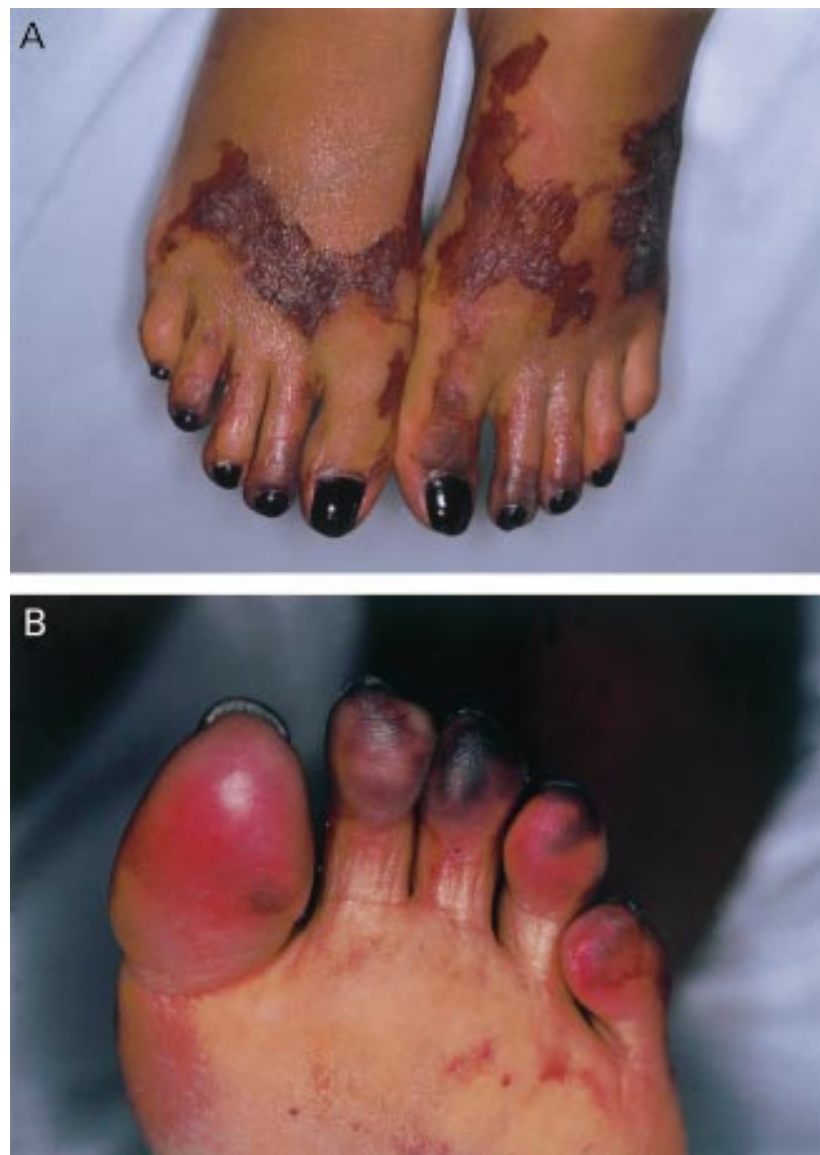

Figure 1 (A) A view of the patient's feet three weeks after the initial presentation, showing demarcating digital ischaemia; (B) a close up view showing marked digital peripheral ischaemia.

- 1 Dukes MNG, Meyler S. *Side-effects of drugs*. 13th ed. Amsterdam: Elsevier, 1996.
- 2 Knowles SR, Gupta AK, Shear NH, Sander D. Azathioprine hypersensitivity-like reactions—a case report and review of the literature. *Clin Exp Dermatol* 1995;20:353–6.
- 3 Brown G, Boldt C, Webb JG, Halpeni L. Azathioprine-induced multi-system organ failure and cardiogenic shock. *Pharmacotherapy* 1997;17:815–18.
- 4 Pozniak AL, Anem M, Blake DR. Azathioprine-induced shock. *BMJ* 1981;283:1548.
- 5 Saway PA, Heck LW, Bonner JR. Azathioprine hypersensitivity—case report and review of the literature. *Am J Med* 1988;84:960–4.
- 6 Fields C, Robinson J, Roy T, Ossorio M, Byrd R. Hypersensitivity reaction to azathioprine. *South Med J* 1998;91:471–4.
- 7 Farthing M, Coxon A, Sheaff P. Polyneuritis associated with azathioprine sensitivity reaction. *BMJ* 1980;280:367.
- 8 Stetter M, Schmidli M, Krapf R. Azathioprine hypersensitivity mimicking Goodpasture's syndrome. *Am J Kidney Dis* 1994;23:874–7.
- 9 Davis M, Eddleston AL, Williams R. Hypersensitivity and jaundice due to azathioprine. *Postgrad Med J* 1980;56:274–5.
- 10 Dinarello CA, Gelfand JA, Wolff SM. Anti-cytokine strategies in the treatment of the systemic inflammatory syndrome. *JAMA* 1993; 269:1829–35.

## Immunosuppressive treatment for vasculitis associated with Lyme borreliosis

Vasculitis of the central nervous system is a rare complication of Lyme borreliosis.<sup>1,2</sup> We now report a case of early onset borrelia associated encephalitis followed by systemic vasculitis. Antibiotics failed to improve the clinical course and remission was only reached after extensive immunosuppressive treatment.

A 52 year old man was admitted because of fever, headache, tinnitus, and painful joints. He reported a tick bite on his left arm, which had occurred three weeks earlier and which was followed by a reddish skin eruption. His general practitioner started treatment with doxycycline, but the patient's condition worsened. The patient had a fever of 39.9°C; further physical examination showed no other abnormalities. Except for an erythrocyte sedimentation rate of 51 mm/1st h and a leucocyte count of  $16.1 \times 10^9/l$ , routine blood analysis was normal. Cultures (blood, urine, stool) were negative. Enzyme linked immunosorbent assays (ELISAs) showed an increased anti-borrelia-IgM titre of 322.5 EU/ml (normal <30) with normal IgG levels, suggestive of early stage Lyme borreliosis. This was supported by western immunoblotting, with reactivity towards anti-borrelia-IgM.<sup>3,4</sup> Intravenous ceftriaxone (2 g daily) was started. Because of signs of meningoencephalitis the patient was transferred to the intensive care unit (ICU). Analysis of the cerebrospinal fluid (CSF) showed anti-borrelia-IgM antibodies, pleocytosis, and an increased protein level, consistent with neuroborreliosis.<sup>5</sup> An artificially increased IgM level in the CSF owing to the introduction of blood during the

spinal tap was ruled out, because few erythrocytes were seen.

Shortly upon arrival at the ICU the patient was intubated and mechanically ventilated because of respiratory insufficiency due to muscle fatigue. Examination now disclosed numerous splinter haemorrhages distributed over the whole body. Ceftriaxone was continued for 10 days and then replaced by doxycycline. After 18 days antibiotic treatment was discontinued because of lack of improvement. Fever persisted and generalised epileptic seizures complicated the course. Cultures remained negative. An ELISA was repeated after four weeks: the anti-borrelia-IgM was then raised to 800 EU/ml; the IgG level was also above normal. The number of splinter haemorrhages increased and a non-oliguric renal insufficiency developed, resembling a glomerulonephritis with microscopic haematuria, granular casts, and proteinuria (0.9 g/24 h). Screening markers of autoimmune diseases (antineutrophil cytoplasmic antibodies, antinuclear antibodies, cryoglobulins) were negative. A skin-fascia-muscle biopsy sample taken from the right leg showed vasculitis of medium sized arteries (fig 1). No spirochaetes were detected in this sample. Treatment with prednisolone (1 mg/kg/day) did not improve the condition of the patient within one week, therefore, cyclophosphamide (2 mg/kg/day) was added. Within two days the patient regained normal neurological functions. Renal function improved within four weeks (serum creatinine decreasing from 249 to 130  $\mu\text{mol/l}$ , blood urea nitrogen decreasing from 56.4 to 24.4 mmol/l of urea) and the patient was weaned from the ventilator. Follow up was uneventful.

Vasculitis may develop within weeks after infection and complicate the clinical course of Lyme borreliosis. To our knowledge, this is the first description of a systemic vasculitis including cerebral and renal disease after *B*

*burgdorferi* infection in a human being. Histological proof for vasculitis was assessed in a skin-fascia-muscle sample; the absence of spirochaetes therein suggests an autoimmune based pathogenesis.<sup>2,6</sup> As in this case, laboratory support for acute *B burgdorferi* infection is an important issue, especially for endemic areas like the Netherlands.<sup>7,8</sup> Whether elicited directly by the micro-organism or by secondary autoimmune mechanisms, vasculitis occurs in association with disseminated organ failure. Cyclophosphamide, successful in a case of *B burgdorferi* induced cerebral vasculitis,<sup>9</sup> was effective for this case of systemic vasculitis as well.

In conclusion, persisting vasculitic activity should be suspected whenever antibiotic treatment does not improve the clinical course in Lyme borreliosis. When borrelia associated vasculitis has been histologically established, and does not respond to corticosteroid treatment alone, we suggest the combined use of prednisolone and cyclophosphamide.

R KOMDEUR  
J G ZIJLSTRA  
T S VAN DER WERF  
J J M LIGTENBERG  
J E TULLEKEN

Department of Internal Medicine,  
Intensive and Respiratory Care Unit (ICB),  
University Hospital Groningen,  
The Netherlands

Correspondence to: Dr J E Tulleken, Intensive and Respiratory Care Unit (ICB), Department of Internal Medicine, University Hospital Groningen, PO 30.001, 9700 RB Groningen, The Netherlands  
j.e.tulleken@int.azg.nl

- 1 Nadelman RB, Wormser GP. Lyme borreliosis. *Lancet* 1998;352:557-65.
- 2 Sigal LH. Immunologic mechanisms in Lyme neuroborreliosis: the potential role of autoimmunity and molecular mimicry. *Semin Neurol* 1997;17:63-8.
- 3 Recommendations for test performance and interpretation from the Second National Conference on Serologic Diagnosis of Lyme Disease. *MMWR Morb Mortal Wkly Rep* 1995;44:590-1.
- 4 Brown SL, Hansen SL, Langone JJ. Role of serology in the diagnosis of Lyme disease. *JAMA* 1999;282:262-6.
- 5 Kaiser R. Neuroborreliosis. *J Neurol* 1998;245:247-55.
- 6 Sigal LH, Williams S. A monoclonal antibody to *Borrelia burgdorferi* flagellin modifies neuroblastoma cell neuritogenesis in vitro: a possible role for autoimmunity in the neuropathy of Lyme disease. *Infect Immun* 1997;65:1722-8.
- 7 de Mik EL, van Pelt W, Docters-van Leeuwen BD, van der Veen A, Schellekens JF, Borgdorff MW. The geographical distribution of tick bites and erythema migrans in general practice in The Netherlands. *Int J Epidemiol* 1997;26:451-7.
- 8 Nohlmans MK, van den Bogaard AE, Blaauw AA, van Boven CP. Prevalence of Lyme borreliosis in The Netherlands. *Ned Tijdschr Geneesk* 1991;135:2288-92.
- 9 Schmitt AB, Kuker W, Nacimiento W. Neuroborreliosis with extensive cerebral vasculitis and multiple cerebral infarcts. *Nervenarzt* 1999;70:167-71.

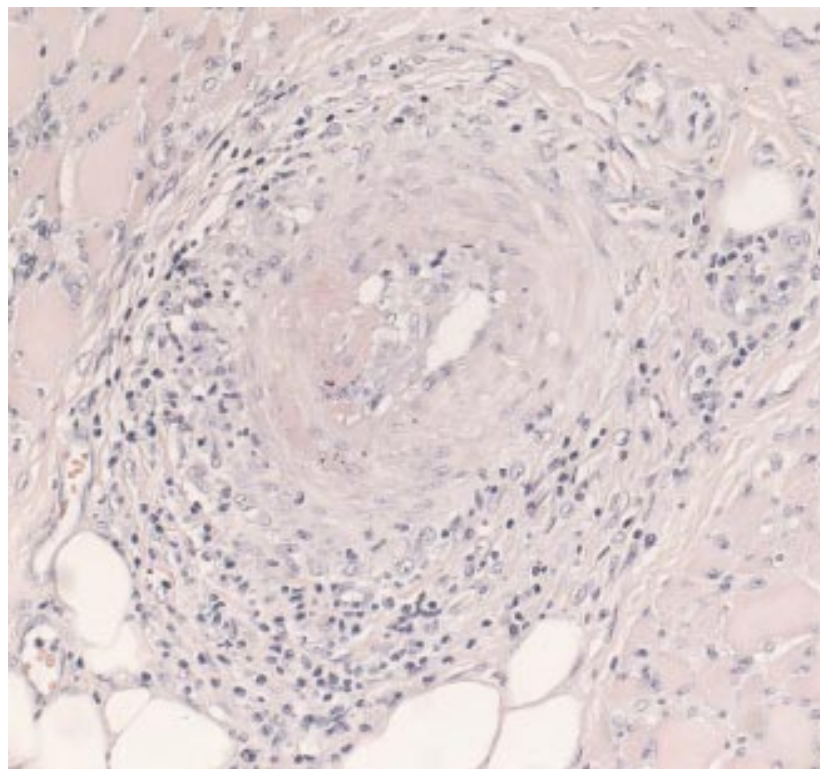


Figure 1 Skin-fascia-muscle biopsy sample showing vasculitis of a medium sized artery and some necrosis of the vessel wall.

## Bilateral transient osteoporosis of the knee in pregnancy

Transient osteoporosis of pregnancy involving the hips has been reported widely. The knee is much less commonly affected and only isolated cases have been reported. We report the case of a woman in the third trimester of pregnancy with bilateral transient osteoporosis of the knees.

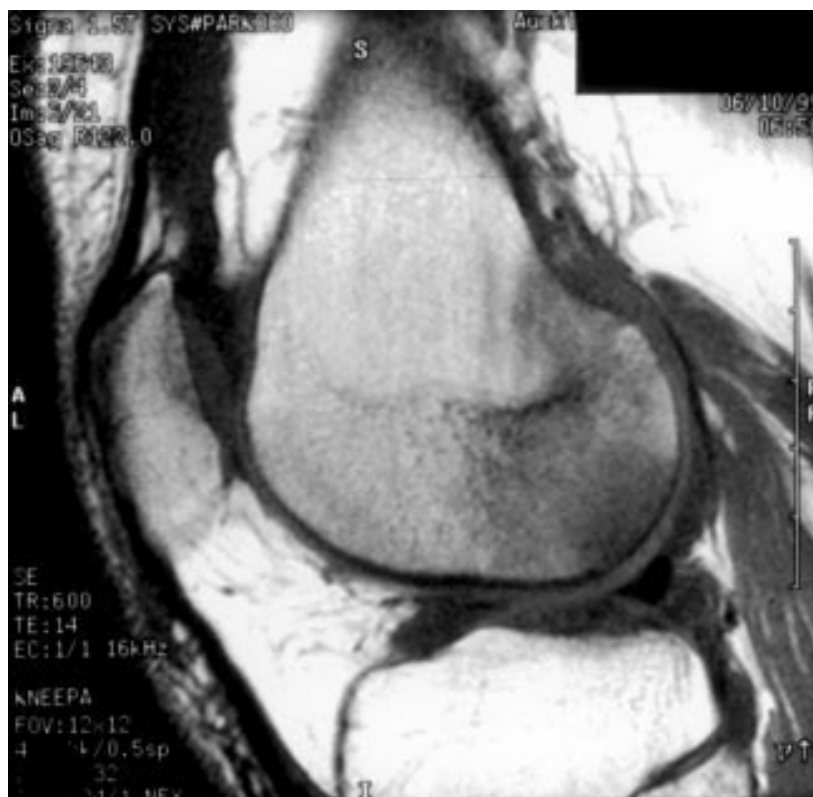

Figure 1 Magnetic resonance imaging at presentation. The T<sub>1</sub> weighted sagittal image of the right knee shows diffuse low signal in the posterior aspect of the lateral femoral condyle. Note the low signal fluid in the knee joint cavity.

A 36 year old woman presented with a one month history of pain in the left knee followed a week later by pain in the right. The right knee deteriorated over one to two weeks until she was unable to weight bear. There was no pain at rest. At the time of presentation she was 30 weeks pregnant with her first child conceived through in vitro fertilisation. There was no past history of joint problems, alcohol excess, corticosteroid use, preceding trauma, acute medical illness, or any constitutional symptoms. She walked with two crutches. Joint examination showed a slightly warm right knee with no clinical evidence of an effusion. Both knees were non-tender to palpation but painful at maximal flexion.

Investigations showed an erythrocyte sedimentation rate of 33 mm/1st h, C reactive protein slightly raised at 10 mg/l (normal <3), and globulins at 36 g/l (25–35) with a normal protein electrophoresis. Full blood count, creatinine, electrolytes, 25-hydroxyvitamin D<sub>3</sub>, parathyroid hormone, creatine kinase, and liver and thyroid function tests were all normal. Antinuclear antibodies, rheumatoid factor, and HLA-B27 were negative. Plain radiographs of the knees were normal. Magnetic resonance imaging (MRI) showed extensive oedema in the medial and lateral femoral condyles and some oedema in the surrounding soft tissues of the right knee (fig 1). There was an effusion in the suprapatellar bursa and some synovial proliferation. In the left knee there was a moderate amount of oedema in the medial femoral condyle and a trace of oedema in the medial tibial condyle.

A diagnosis of transient osteoporosis of pregnancy was entertained and the patient was treated with simple analgesics and followed up closely throughout the remainder

of her pregnancy. She presented to the delivery suite in labour at 39 weeks' gestation and successfully delivered a healthy 4500 g male infant by fast normal vaginal delivery. By three weeks post partum the pain had begun to resolve and she could walk without any aids. At three months post partum there was only residual discomfort in the right knee walking up and down stairs. Repeat MRI of the knees showed dramatic improvement in the bone marrow oedema. In the right knee there was only minor patchy oedema in the distal femur and proximal tibia. In the left knee there was some residual spotty marrow inhomogeneity in the lateral tibial plateau.

Transient osteoporosis is an uncommon condition affecting middle aged men or women in the third trimester of pregnancy. The hip joints are most commonly affected, being reported in 76% of cases.<sup>1</sup> There are only isolated case reports of the knee being affected in pregnant women,<sup>2–3</sup> and none with both knees involved as in this report.

Plain radiography of the affected joint is often normal early in the course of disease, with changes only becoming apparent after four to six weeks.<sup>4</sup> Demineralisation of the bone and resultant osteopenia may be severe. Joint space is preserved throughout the course and there is no progression to joint erosion.<sup>5–6</sup> MRI is the radiological investigation of choice showing transient bone marrow oedema (the term preferred to "transient osteoporosis") and almost always a joint effusion.<sup>5,7</sup> The cause is unknown, but the MRI appearances and limited histological information<sup>7–8</sup> suggest an active inflammatory process. Although a variety of treatments have been used,<sup>2,9</sup> a conservative approach is favoured during pregnancy.

L STAMP  
L MCLEAN  
N STEWART  
Department of Rheumatology and Department  
of Radiology,  
Auckland Healthcare,  
Auckland, New Zealand

L MCLEAN  
Department of Molecular Medicine,  
University of Auckland,  
Auckland, New Zealand

N STEWART  
Auckland Radiology Group,  
Auckland, New Zealand

M BIRDSALL  
Fertility Associates,  
Auckland, New Zealand

Correspondence to: Dr L. Stamp, Rheumatology Unit, Level 4, Eleanor Harrald Building, Royal Adelaide Hospital, North Terrace, Adelaide, SA 5000, Australia

lstamp@mail.rah.sa.gov.au

- 1 Bijl M, van Leeuwen M, van Rijswijk M. Transient osteoporosis of the hip: presentation of (a) typical cases and a review of the literature. *Clin Exp Rheumatol* 1997;17:601–4.
- 2 Samdani A, Lachmann E, Nagler W. Transient osteoporosis of the hip during pregnancy. A case report. *Am J Phys Med Rehabil* 1998;77:153–6.
- 3 Doury P, Delahaye RP, Granier R, Pattin S, Metzges PJ. Highly localized transient osteoporosis of the knee [letter]. *Arthritis Rheum* 1978;21:992–3.
- 4 Daniel W, Sanders C, Alarcon G. The early diagnosis of transient osteoporosis by magnetic resonance imaging. *J Bone Joint Surg Am* 1992;74:1262–4.
- 5 Urbanski S, De Lange E, Eschenroeder H. Magnetic resonance imaging of transient osteoporosis of the hip. *J Bone Joint Surg Am* 1991;73:451–5.
- 6 Wilson A, Murphy WA, Hardy DC, Totty WG. Transient osteoporosis? Transient bone marrow edema? *Radiology* 1988;167:757–60.
- 7 Potter H, Moran M, Schneider R, Bansal M, Sherman C, Markisz J. Magnetic resonance imaging in diagnosis of transient osteoporosis of the hip. *Clin Orthop* 1992;280:223–9.
- 8 Lakhnani S, Ginsburg WW, Luthra HS, Hunder GG. Transient regional osteoporosis: a study of 56 cases and review of the literature. *Ann Intern Med* 1987;106:444–50.
- 9 Carmona-Ortells L, Carvajal-Mendez I, Garcia-Vadillo JA, Alvaro-Gracia JM, Gonzalez-Alvaro I. Transient osteoporosis of the hip: successful response to deflazacort. *Clin Exp Rheumatol* 1995;13:653–5.

## Anticholesterol antibody levels in patients with systemic lupus erythematosus

Systemic lupus erythematosus (SLE)—the prototype of immune complex diseases—is characterised by disturbances of the cellular and humoral immune systems. Antibodies against nuclear components are the hallmark of SLE, but a number of antibodies against proteins, glycoproteins, and carbohydrates have also been reported. Dyslipoproteinaemia and accelerated atherosclerosis that commonly lead to coronary artery disease and other complications are recognised sequelae.<sup>1–3</sup> The role of autoimmunity in the aetiology of atherosclerosis has recently been highlighted.<sup>1–3</sup> Increased levels of antibodies against oxidised low density lipoprotein, lysophosphatidylcholine, and apolipoprotein A1 were found in patients with SLE.<sup>4,5</sup> As reported earlier, we have shown marked alterations of anticholesterol antibody

(ACHA) levels in patients with various atherosclerotic vascular disorders.<sup>6</sup> In this study ACHA levels of patients with SLE were compared with those of healthy donors.

Sixty eight patients (64 women, four men), aged 39.4 (10.6) (mean (SD)) years, who fulfilled at least four of the diagnostic criteria established by the American Rheumatism Association for SLE<sup>7</sup> and 60 healthy donors (55 women, five men), aged 42.6 (8.12), were enrolled into the study. The SLEDAI (SLE Disease Activity Index) score was used to measure disease activity.<sup>8</sup> Patients were considered to have active lupus if they scored at least 2 on the modified SLEDAI scale (calculated by omitting anti-dsDNA and complement from SLEDAI) and prompt treatment was obviously indicated to control their symptoms.

The level of cholesterol-specific antibodies was measured by a solid phase enzyme immunoassay described earlier.<sup>6</sup> Polystyrene plates (Greiner, Frickenhausen, Germany) were coated with 5 µg/well cholesterol dissolved in 100 µl absolute ethanol and incubated at 4°C for 24 hours. After washing with phosphate buffered saline (PBS) and blocking with 0.1% casein (Reanal, Budapest, Hungary) in PBS, the wells were incubated with 100 µl samples of serum diluted 1:800 in PBS containing 0.1% casein. The binding of ACHA was detected by anti-human horseradish peroxidase conjugated γ-chain-specific rabbit antibodies (DAKO, Glostrup, Denmark); and with *o*-phenylenediamine (Sigma, St Louis, USA) using H<sub>2</sub>O<sub>2</sub> as substrate. Optical density was measured at 492 nm (reference at 620 nm), and the mean of duplicates was calculated. Serial dilutions of purified immunoglobulin were used as standards in all experiments. Data obtained as optical density values were expressed in arbitrary units per millilitre (AU/ml), related to the standard curve. Our previous observations,<sup>6</sup> in accordance with those of others,<sup>9</sup> demonstrated the specificity of ACHA to cholesterol. The inter- and intra-assay variations of this method were 18.7% and 9.5%, respectively.

Differences between the parameters measured in controls and patients with SLE, between patients with active and inactive SLE, and those between patients with and without previous vascular events were calculated with the Mann-Whitney-test. The  $\chi^2$  test was used to estimate the discriminative power of ACHA between patients with SLE and healthy donors. The correlation of individual parameters with each other and with the SLEDAI score was calculated using Spearman's rank correlation test.

Twelve samples (18%) were classified as having been obtained from patients with active SLE and 56/68 (82%) from patients with inactive disease. Three of the 12 "active" samples were from patients with SLE active in more than one organ system and nine were from patients with disease activity in one organ system only (musculoskeletal (four), central nervous system (two), renal (two), and cutaneous (one)).

The difference between ACHA levels measured in the control group and in patients with SLE was significant ( $p < 0.001$ ) (fig 1). High ACHA levels, in the upper quartile occurred in 29/68 (43%) patients with SLE and 13/60 (22%) controls ( $p = 0.012$ ). ACHA levels (mean (SD)) of patients with active (97 (81) AU/ml) or inactive (64 (38) AU/ml) SLE did not differ significantly ( $p = 0.21$ ) and did not correlate with the SLEDAI score

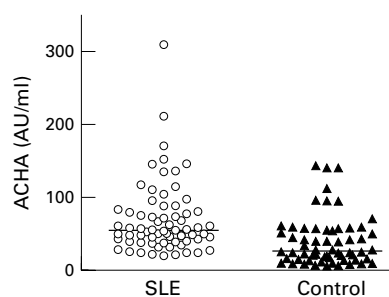


Figure 1 Individual anticholesterol antibody (ACHA) levels (mean (SD)) of patients with systemic lupus erythematosus (SLE) (69 (49) AU/ml) and of healthy donors (38 (34) AU/ml). Horizontal lines show median values.

( $r_s = 0.22$ ,  $p = 0.066$ ). No correlation was found between the ACHA level and other parameters (such as anti-dsDNA, CH<sub>50</sub>, C3, and C4, data not shown). No significant differences were found between patients treated with corticosteroids for inactive disease or those with inactive disease and not receiving corticosteroid treatment ( $p = 0.174$ ). The latter group had not received corticosteroids for at least one year before blood samples were obtained. The difference between the ACHA levels of patients who had or had not experienced vascular events was not significant.

The observed increases of ACHA levels may be related to underlying chronic inflammatory disease. A number of conditions such as dyslipoproteinaemia,<sup>1-3</sup> nephrotic syndrome, and changes in cholesterol membrane domains<sup>10</sup> might have elicited the increase of ACHA levels. Corticosteroid treatment might also have stimulated ACHA production, though according to our observations this intervention does not alter ACHA levels significantly. A preventive role against atherosclerosis in patients with SLE has been attributed to raised ACHA levels, though these may also exert an atherogenic effect.<sup>9</sup> Further studies are necessary to clarify the role of ACHA in the changes of lipid metabolism ascertained in patients with SLE.

This work was supported by grants OTKA No T 029044 (IK) and ETT No 239/2000 (LR).

G NAGY  
A HORVÁTH  
G FÜST  
L ROMICS  
P GERGELY  
I KARÁDI

3rd Department of Internal Medicine,  
Budapest, Hungary

G NAGY  
P GERGELY  
Central Laboratory of Immunology  
Faculty of Medicine,  
Semmelweis University

G NAGY  
A HORVÁTH  
G FÜST  
L ROMICS  
I KARÁDI  
Research Group of Metabolism,  
Genetics and Immunology,  
Hungarian Academy of Sciences,  
Budapest, Hungary

- Manzi S. Inflammation-mediated rheumatic diseases and atherosclerosis. *Ann Rheum Dis* 2000;59:321-5.
- Illowitz NT. Hyperlipidemia and the rheumatic diseases. *Curr Opin Rheumatol* 1996;8:455-8.
- Bruce IN, Urowitz MB, Gladman DD, Hallett DC. Natural history of hypercholesterolemia in

systemic lupus erythematosus. *J Rheumatol* 1999;26:2137-43.

- Dinu AR, Merrill JT, Shen C, Antonov IV, Myones BL, Lahita RG. Frequency of antibodies to the cholesterol transport protein apolipoprotein A1 in patients with SLE. *Lupus* 1998;7:355-60.
- Wu R, Svenungsson E, Gunnarsson I, Andersson B, Lundberg I, Schafer Elinder L, et al. Antibodies against lysophosphatidylcholine and oxidized LDL in patients with SLE. *Lupus* 1999;8:142-50.
- Horváth A, Füst G, Horváth I, Vallus G, Duba J, Harcos P, et al. Anti-cholesterol antibody levels in patients with different atherosclerotic vascular diseases. *Atherosclerosis* (in press).
- Tan EM, Cohen AS, Fries JF, Masi AT, McShane DJ, Rothfield NF, et al. The 1982 revised criteria for the classification of systemic lupus erythematosus (SLE). *Arthritis Rheum* 1982;25:1271-7.
- Bombardier C, Gladman DD, Urowitz MB, Caron D, Chang CH, and the Committee on Prognosis Studies in SLE. Derivation of the SLEDAI. A disease activity index for lupus patients. *Arthritis Rheum* 1992;35:630-40.
- Dijkstra J, Swartz GM, Rancey JJ, Anigolou J, Toro L, Nancy CA, et al. Interactions of anti-cholesterol antibodies with human lipoproteins. *J Immunol* 1996;157:2006-13.
- Schroeder F, Woodford JK, Kavcansky J, Wood WG, Joiner C. Cholesterol domains in biological membranes. *Mol Membr Biol* 1995;12:113-19.

## Intravenous immunoglobulin for treatment of gastrointestinal haemorrhage in dermatomyositis

Polymyositis (PM) and dermatomyositis (DM) are systemic inflammatory disorders affecting skeletal muscles and other organs, especially the digestive tract.<sup>1-8</sup> Oesophageal motor disturbances are common, occurring in as many as 25-60% of patients with PM/DM.<sup>5</sup> Gastrointestinal disease is less recognised in PM/DM, though it may be responsible for life threatening complications—for example, dramatic haemorrhage, perforation, pseudo-obstruction, pneumatosis cystoides intestinalis, and spontaneous abdominal haematoma<sup>1-4 6-8</sup>. We recently observed a new case, which is of particular interest. The patient who had DM refractory to steroids and both gastrointestinal haemorrhage related to vasculitis and oesophageal impairment due to DM experienced a rapid and complete resolution of all clinical manifestations after intravenous immunoglobulin treatment was started.

An 18 year old man had DM evolving from March 1999. The diagnosis of DM was made by the Bohan and Peter criteria<sup>9 10</sup>: (a) symmetrical muscle weakness. Muscle power was gauged for eight proximal muscles (neck flexors, trapezius, deltoid, biceps, psoas, maximus and medius gluteus, and quadriceps) by a modification of the British Medical Research Council Grading system,<sup>3</sup> resulting in a theoretical maximum score of 88 points. Muscle power of the patient was 73 points; (b) increased serum muscle enzymes—that is, creatine kinase (CK) 1700 U/l (normal 5-130) and aldolase 7.2 U/l (normal 0.5-3.1); (c) myopathic changes on electromyography; (d) muscle damage on histological examination; and (e) characteristic dermatological manifestations—that is, heliotrope rash, periungual erythema, and poikiloderma.

Autoantibody screen was positive for anti-nuclear antibodies (ANA) with a value of 1/1000. Investigations, including pulmonary function tests, computed tomography scan of

the lungs, echocardiography, and abdominal ultrasound, were normal. Treatment with prednisone was started at a dose of 1 mg/kg daily. As both the clinical and biochemical status continued to deteriorate gradually, the steroid regimen was increased to a dose of 1.5 mg/kg a day in June 1999.

In July 1999 the patient presented with a two week history of dysphagia and melaena evolving from one day. On admission, his general condition was poor and abdominal palpation was tender. Physical examination also showed cutaneous manifestations of DM and muscle weakness affecting both arms and legs. Muscle power of the patient was 65 points. Laboratory findings were as follows: erythrocyte sedimentation rate 50 mm/1st h, C reactive protein 30 mg/l, haemoglobin 6.6 mmol/l, mean corpuscular volume 90 fl, reticulocytes  $150 \times 10^9/l$ , white blood cell count  $10 \times 10^9/l$ , platelet count  $490 \times 10^9/l$ , CK 3000 U/l, and aldolase 13.5 U/l. Findings of renal and liver tests, total protein, and albumin levels were normal. Autoantibody screening was positive for ANA  $>1/1000$  with a speckled pattern; other tests, particularly for anti-Jo1 antibody, rheumatoid factors, anticardiolipin and antiphospholipid antibodies, lupus-like anticoagulant, antineutrophil cytoplasmic antibodies, and cryoglobulin, were negative. Oesophageal manometry showed decreased peristalsis in the upper third of the oesophageal body and normal pressure in both upper and lower oesophageal sphincters. Gastroscopy demonstrated multiple small ulcerations affecting the stomach and the duodenum, with histology showing vasculitis of the small sized vessels.

A diagnosis of gastrointestinal haemorrhage related to vasculitis and oesophageal impairment due to DM was made. The patient was given intravenous immunoglobulin at a dose of 1 g/kg for two consecutive days monthly for six months. Prednisone was simultaneously decreased gradually to 5 mg every 15 days. The patient had no gastrointestinal haemorrhage recurrence, swallowing disorders and muscle strength improved rapidly, and the dermatological signs cleared.

In November 1999 methotrexate treatment was started at a dose of 30 mg weekly. At one year follow up, the patient remains free of digestive, cutaneous, and muscle symptoms with methotrexate at a dose of 30 mg weekly and 12 mg prednisone daily.

Although oesophageal motor abnormalities predominate in patients with PM/DM and have been extensively described, involvement of the gastrointestinal tract is considered to be less common.<sup>1-8</sup> In a review of 96 patients with DM, Downey *et al* found that only four patients had gastrointestinal manifestations.<sup>2</sup> Our findings confirm that gastrointestinal impairment is a major cause of morbidity in PM/DM, as our patient presented with life threatening gastrointestinal haemorrhage. A diagnosis of gastrointestinal vasculitis related to DM could reasonably be made for our patient because the onset of DM clinical deterioration and gastrointestinal vasculitis was concomitant and the search for other causes of vasculitis (notably systemic vasculitides or other connective tissue disorders) proved negative.

Our report further highlights the importance of recognising gastrointestinal complications at an early stage in PM/DM, resulting in accurate diagnosis and management, and therefore decreasing both morbidity and mortality. The pathological mechanisms of gastrointestinal involvement are still not

clearly understood in PM/DM, though it may be related to vasculitis of small sized vessels, leading to ischaemia, haemorrhage, and perforation of the gastrointestinal wall.<sup>2,3,9</sup> Moreover, the present case is original, as our patient with DM and life threatening digestive impairment received intravenous immunoglobulin treatment, which prevented gastrointestinal haemorrhage recurring and produced dramatic and rapid remission of swallowing disorders. Previous authors have also mentioned a favourable outcome with intravenous immunoglobulin treatment in patients with systemic vasculitis—for example, Churg-Strauss vasculitis, microscopic polyangiitis, or systemic lupus erythematosus.<sup>11-14</sup> In this instance, a limitation was the concomitant continuation of steroids during the entire period of intravenous immunoglobulin, making it difficult to be certain that the patient's clinical improvement was only attributable to intravenous immunoglobulin treatment. However, the improvement of all gastrointestinal symptoms may reasonably be related to intravenous immunoglobulin infusions in our patient with DM because the gastrointestinal manifestations deteriorated persistently despite high doses of prednisone as a single treatment. The beneficial effect of the accompanying methotrexate treatment could also be excluded, as this later drug was started at the five month follow up of the patient.

Finally, our findings indicate that intravenous immunoglobulin should be considered the best treatment in both gastrointestinal haemorrhage related to vasculitis and oesophageal dysfunction due to steroid refractory DM, such a treatment offering the advantages of short term efficacy and good tolerance. However, no definite conclusion can be drawn and further controlled trials with a large number of patients with PM/DM are required to establish optimal doses and effective management.

I MARIE  
H LEVESQUE  
N CAILLEUX  
H COURTOIS

Department of Internal Medicine,  
Centre Hospitalier Universitaire de  
Rouen-Boisguillaume,  
76031 Rouen Cedex, France

C GUÉDON

Department of Gastroenterology,  
Centre Hospitalier Universitaire de Rouen,  
76031 Rouen Cedex, France

Correspondence to: Dr I Marie, 16 rue Arthur Duval, 76300 Sotteville-lès-Rouen, France

- Boardman P, Nolan DJ. Case report: small intestinal pseudo-obstruction: an unusual manifestation of polymyositis. *Clin Radiol* 1998;53:706-7.
- Downey EC Jr, Woolley MM, Hanson V. Required surgical therapy in the pediatric patient with dermatomyositis. *Arch Surg* 1988; 123:1117-20.
- Eshraghi N, Farahmand M, Maerz LL, Campbell SM, Deveney CW, Sheppard BC. Adult-onset dermatomyositis with severe gastrointestinal manifestations: case report and review of the literature. *Surgery* 1998;123:356-8.
- Kleckner FS. Dermatomyositis and its manifestations in the gastrointestinal tract. *Am J Gastroenterol* 1970;53:141-6.
- Marie I, Hachulla E, Levesque H, Reumont G, Ducrotte P, Cailleux N, *et al*. Intravenous immunoglobulins as treatment of life threatening esophageal involvement in polymyositis and dermatomyositis. *J Rheumatol* 1999;26: 2706-9.
- Orrell RW, Johnston HM, Gibson C, Cass RM, Griggs RC. Spontaneous abdominal hematoma in dermatomyositis. *Muscle Nerve* 1998;21:1800-3.

- Pasquier E, Wattiaux MJ, Peigney N. First case of pneumatosis cystoides intestinalis in adult dermatomyositis. *J Rheumatol* 1993;20:499-503.
- Schullinger JN, Jacobs JC, Berdon WE. Diagnosis and management of gastrointestinal perforations in childhood dermatomyositis with particular reference to perforations of the duodenum. *J Pediatr Surg* 1985;20:521-4.
- Bohan A, Peter JB. Polymyositis and dermatomyositis. *N Engl J Med* 1975;292:344-7.
- Bohan A, Peter JB. Polymyositis and dermatomyositis. *N Engl J Med* 1975;292:403-7.
- Hashkes PJ, Lovell DJ. Vasculitis in systemic lupus erythematosus following intravenous immunoglobulin therapy. *Clin Exp Rheumatol* 1996;14:673-5.
- Jayne DR, Lockwood CM. Intravenous immunoglobulin as sole therapy for systemic vasculitis. *Br J Rheumatol* 1996;35:1150-3.
- Levy Y, George J, Fabbri F, Rotman P, Paz Y, Shoenfeld Y. Marked improvement of Churg-Strauss vasculitis with intravenous gamma-globulins. *South Med J* 1999;92:412-14.
- Levy Y, Sherer Y, George J, Langevitz P, Ahmed A, Bar-Dayyan Y, *et al*. Serologic and clinical response to treatment of systemic vasculitis and associated autoimmune disease with intravenous immunoglobulin. *Int Arch Allergy Immunol* 1999;119:231-8.

## Sjögren's syndrome: an unusual cause of Bell's palsy

The most common form of facial paralysis is idiopathic—that is, Bell's palsy. Sjögren's syndrome (SS), a chronic inflammatory disorder characterised by lymphocytic infiltration of exocrine glands resulting in the so called "sicca complex", is a rare secondary cause of this self limiting illness. Primary SS includes mostly peripheral, and to a lesser extent cranial, autonomic neuropathy and central nervous system involvement.<sup>1</sup> A patient with unilateral facial palsy, autoimmune hypothyroidism, and Sjögren's syndrome is presented.

A 41 year old woman developed right sided facial numbness, described as "dentist anaesthesia for tooth extraction". One day later she had a reduced sense of taste and right facial weakness. General physical examination was not remarkable. Neurological examination showed anisocoria, peripheral right sided facial paresis, reduced sense of taste on the right half of the tongue, and dysaesthesia in the region of the second segment of the right trigeminal nerve.

Although the erythrocyte sedimentation rate (ESR) was 30 mm/1st h, routine laboratory investigations were normal. Liquor examination, including IgG, IgG index, and oligoclonal or extra bands on electrophoresis, was not abnormal. Screening tests for herpes simplex and varicella virus, syphilis, and borrelia in the serum and in the liquor were negative. Magnetic resonance imaging (MRI) of the brain showed no abnormalities. Nerve conduction studies showed peripheral facial paresis. She recovered spontaneously from her symptoms within several days. Conversely, during follow up the raised ESR persisted.

Review of her medical history uncovered complaints of burning eyes and dry mouth, slight weight gain, and cold intolerance. There was no history of arthralgias or skin lesions. She denied using any drugs previously. A strongly positive anti-extranuclear antigen (ENA)/SS-A antibodies test was shown on further investigation, with negative tests for antinuclear factor/anti-nDNA antibodies/rheumatoid factor and RNP/SS-B/Sm antibodies. Rose-Bengal staining showed corneal punctate lesions (van Bijsterveld score 6). Lower labial biopsy showed histopathological findings matching the diagnosis of SS with a



focus score of one lymphocyte focus for 4 mm<sup>2</sup> salivary gland tissue. Additionally, thyroid function tests showed a raised thyroid stimulating hormone (11 mU/l), low free thyroxine 4 (13.0 pmol/l) with positive antithyroid microsomal antibodies and negative antithyroglobulin antibodies.

The clinical, serological, and histopathological manifestations fulfilled the European study group criteria for the diagnosis of SS. The patient was treated with artificial tears and thyroxine supplements that returned her thyroid function tests to normal.

Prevalence of neuropathy in patients with SS ranges from 10 to 50%.<sup>2</sup> Polyneuropathy can be the first clinical manifestation of SS and may even precede sicca symptoms in 40% of patients.<sup>3</sup> However, less frequently, cranial neuropathy can occur with a predisposition to involvement of the trigeminal nerve.<sup>4</sup> The vasculitic damage to vaso nervorum documented by pathological studies is associated with a higher incidence of serum anti-SS-A (Ro) antibodies.<sup>5</sup> The association of SS with autoimmune thyroid disease (AITD) is well recognised.<sup>6,7</sup> AITD and SS share similarities in the immunopathology in addition to their genetic linkage to the HLA-DR3/DR4 alleles.<sup>7</sup> Only nine cases of facial nerve involvement associated with SS have been described previously.<sup>1,8-10</sup>

This case illustrates how facial palsy disclosed the primary SS as an underlying systemic disorder. To our knowledge the combination Bell's palsy as presenting feature in a patient with SS, and hypothyroidism secondary to AITD has not been reported hitherto.

M HADITHI  
F STAM  
A J M DONKER  
Department of Internal Medicine

B A C DIJKMANS  
Department of Rheumatology,  
Academic Hospital Vrije Universiteit,  
Amsterdam, The Netherlands

Correspondence to: M Hadithi, Department of Internal Medicine, Academic Hospital Vrije Universiteit, P O Box 7057, 1007 MB Amsterdam, The Netherlands

m.hadithi@azvu.nl

1 Mauch E, Volk C, Kratzsch G, Krampf H, Kornhuber HH, Laufen H, *et al.* Neurological and neuropsychiatric dysfunction in primary Sjogren's syndrome. *Acta Neurol Scand* 1994;89:31-5.

2 Kaplan JG, Rosenberg R, Reinitz E, Buchbinder S, Schaumburg HH. Invited review: peripheral neuropathy in Sjogren's syndrome. *Muscle Nerve* 1990;13:570-9.

- 3 van Dijk GW, Notermans NC, Kater L, Kruijze AA, Linssen WH, Wokke JH. Sjogren's syndrome in patients with chronic idiopathic axonal polyneuropathy [see comments]. *J Neurol Neurosurg Psychiatry* 1997;63:376-8.
- 4 Alexander EL, Provost TT, Stevens MB, Alexander GE. Neurologic complications of primary Sjogren's syndrome. *Medicine (Baltimore)* 1982;61:247-57.
- 5 Peyronnard JM, Charron L, Beaudet F, Couture F. Vasculitic neuropathy in rheumatoid disease and Sjogren syndrome. *Neurology* 1982;32:839-45.
- 6 Perez B, Kraus A, Lopez G, Cifuentes M, Alarcon-Segovia D. Autoimmune thyroid disease in primary Sjogren's syndrome. *Am J Med* 1995;99:480-4.
- 7 Coll J, Anglada J, Tomas S, Reth P, Goday A, Millan M, *et al.* High prevalence of subclinical Sjogren's syndrome features in patients with autoimmune thyroid disease. *J Rheumatol* 1997;24:1719-24.
- 8 Sjogren H. Zur Kenntnis der Keratoconjunctivitis sicca. II. Allgemeine Symptomatologie und Aetiologie. *Acta Ophthalmol (Kbh)* 1935;13:1-39.
- 9 Uchihara T, Yoshida S, Tsukagoshi H. Bilateral facial paresis with Sjogren's syndrome [letter]. *J Neurol* 1989;236:186.
- 10 Phanthumchinda K. Multiple cranial nerve palsies as a presenting symptom in primary Sjogren's syndrome. *J Med Assoc Thai* 1989;72:291-4.

### $\alpha_1$ Antitrypsin phenotypic variability is not associated with ANCA in southern Chinese

$\alpha_1$  Antitrypsin ( $\alpha_1$ AT) is a 52 kDa proteinase encoded by a gene locus Pi on chromosomal segment 14q32.1. It is a natural inhibitor of proteinase 3 (PR3), a neutrophil granular protein and a major autoantigen of antineutrophil cytoplasmic antibody (ANCA). The function of  $\alpha_1$ AT is in turn restricted by myeloperoxidase (MPO), another autoantigen of ANCA. The interplay between the enzymes, inhibitors, and the autoantibodies is implicated in the dynamics of the vasculitic process,<sup>1</sup> resulting in a whole spectrum of clinical conditions ranging from systemic granulomatous diseases to kidney limited glomerulonephritis. There have been reports of the correlation of specific  $\alpha_1$ AT alleles, notably Pi<sup>Z</sup>, with ANCA.<sup>2-4</sup> These were largely studies of white subjects, which may not necessarily be extrapolated to all populations.

$\alpha_1$ AT variant phenotypes may have predisposed to PR3-ANCA, but the same association may not exist for MPO-ANCA. In populations with a low prevalence of  $\alpha_1$ AT variant phenotypes, the pattern of ANCA could differ from that in white subjects where such variants prevail. We set out therefore to

Table 2  $\alpha_1$  Antitrypsin alleles in ANCA\* (anti-PR3\* or anti-MPO\*) positive patients

Allele	All ANCA+ No (%)	Anti-PR3+ No (%)	Anti-MPO+ No (%)
M1	250(80)	94(78)	156(80)
M2	58(18)	24(20)	34(18)
M3	2(1)	0(0)	2(1)
M4	0(0)	0(0)	0(0)
S	2(1)	1(1)	1(0.5)
Z	0(0)	0(0)	0(0)
Other	2(1)	1(1)	1(0.5)
Total	314(100)	120(100)	194(100)

\*ANCA = antineutrophil cytoplasmic antibody; PR3 = proteinase 3; MPO = myeloperoxidase.

establish the distribution of  $\alpha_1$ AT in patients with the two main forms of ANCA (anti-PR3 positive and anti-MPO positive). Blood samples of patients with vasculitis received at the immunology section of the Department of Pathology, Queen Mary Hospital, Hong Kong, were tested for ANCA by indirect immunofluorescence, followed by enzyme linked immunosorbent assays (ELISA) for anti-PR3 and anti-MPO.  $\alpha_1$ AT phenotypes were determined by isoelectric focusing, the results of which were compared with those of healthy Chinese adults.

A total of 157 samples from ANCA+ (either anti-MPO or anti-PR3 positive by ELISA) patients were evaluated, 60 (38%) of which were positive for anti-PR3 and 97 (62%) for anti-MPO by ELISA. All were Chinese patients with a clinical diagnosis of vasculitis. The male to female ratio was 0.76 (0.94 for anti-PR3 positive and 0.67 for anti-MPO positive patients). The mean age of the two groups was 52.4 and 59.4 years, respectively. A total of 103 (66%) were homozygous M, 50 (32%) heterozygous M (for example, M1 M2), and 4 (3%) heterozygous for M and a variant allele. Tables 1 and 2 show the allelic and phenotypic frequencies. In the healthy controls (n=1085), 717 (66.1%) were homozygous for an M phenotype. Allelic variants were rare, accounting for only 0.7% of all alleles. The  $\alpha_1$ AT deficiency variant Pi<sup>Z</sup> was absent in both the study group and the healthy control group. There was no significant difference in the proportion of homozygous and heterozygous M phenotypes between the normal and the ANCA+ group (exact  $\chi^2$  test, p=0.56) and between anti-PR3 and anti-MPO (exact  $\chi^2$  test, p=0.80). ANCA+ patients had a higher proportion of variant alleles, but this did not reach significance (1.26% v 0.70%; exact  $\chi^2$  test, p=0.10).

The rarity of the Pi<sup>Z</sup> allele in oriental<sup>5</sup> and black populations<sup>6</sup> has been previously reported, a finding which is confirmed for Chinese patients in this study. We found no association of  $\alpha_1$ AT variant phenotypes with ANCA in Chinese patients. It is interesting to note the higher number of anti-MPO positive patients in the study group. In a separate study the anti-MPO to anti-PR3 ratio in Chinese patients diagnosed over a defined period was 1.4:1 (the reverse of the situation in white populations, where PR3-ANCA positive Wegener's granulomatosis is much more common).<sup>7</sup> Even for the Chinese patients who tested positive for PR3-ANCA, the positive predictive value for Wegener's granulomatosis was less than 25%. The low prevalence of  $\alpha_1$ AT variant phenotypes may be one factor behind the uncommon presence of anti-PR3 in Chinese people. We conclude that  $\alpha_1$ AT does not have a significant role in ANCA

Table 1  $\alpha_1$  Antitrypsin phenotypes in ANCA\* (anti-PR3\* or anti-MPO\*) positive patients

Phenotypes	All ANCA+ No (%)	Anti-PR3+ No (%)	Anti-MPO+ No (%)
Homozygous M			
M1 M1	99(63)	36(60)	63(65)
M2 M2	4(3)	2(3)	2(2)
M3 M3	0(0)	0(0)	0(0)
M4 M4	0(0)	0(0)	0(0)
Heterozygous M			
M1 M2	48(31)	20(33)	28(29)
M1 M3	0(0)	0(0)	0(0)
M2 M3	2(1)	0(0.0)	2(2)
Other heterozygous			
M1 S	2(1)	1(2)	1(1)
M2 S	0(0)	0(0)	0(0)
M1 other	2(1)	1(2)	1(1)
M2 other	0(0)	0(0)	0(0)
Total	157(100)	60(100)	97(100)

\*ANCA = antineutrophil cytoplasmic antibody; PR3 = proteinase 3; MPO = myeloperoxidase.

associated diseases in southern Chinese among whom anti-MPO predominate.

S S LEE

J W M LAWTON

K H KO

Department of Pathology,  
The University of Hong Kong,  
Queen Mary Hospital Compound,  
Pokfulam Road,  
Hong Kong Special Administrative Region,  
China

Correspondence to: Dr S S Lee, 5/F Yaumatei Jockey Club Clinic, 145 Battery Street, Yaumatei, Kowloon, Hong Kong SAR

microssl@health.gcn.gov.hk

- 1 Esnault VL, Testa A, Audrain M, Roge C, Hamidou M, Barrier JH, *et al*. Alpha 1-antitrypsin genetic polymorphism in ANCA-positive systemic vasculitis. *Kidney Int* 1993;43:1329–32.
- 2 Griffith ME, Lovegrove JU, Gaskin G, Whitehouse DB, Pusey CD. C-antineutrophil cytoplasmic antibody positivity in vasculitis patients is associated with the Z allele of alpha-1-antitrypsin, and P-antineutrophil cytoplasmic antibody positivity with the S allele. *Nephrol Dial Transplant* 1996;11:438–43.
- 3 Savige JA, Chang L, Cook L, Burdon J, Daskalakis M, Doery J. Alpha 1-antitrypsin deficiency and anti-proteinase 3 antibodies in anti-neutrophil cytoplasmic antibody (ANCA)-associated systemic vasculitis. *Clin Exp Immunol* 1995;100:194–7.
- 4 Elsouki AN, Eriksson S, Lofberg, Nasberger L, Wieslander J, Lindgren S. The prevalent clinical significance of  $\alpha$ 1-antitrypsin deficiency (PiZ) and ANCA specificities (proteinase 3, BPI) in patients with ulcerative colitis. *Inflamm Bowel Dis* 1999;5:246–52.
- 5 Ying QL, Liang ZQ. Allelic frequencies of plasma  $\alpha$ 1-antitrypsin in Chinese. *Sci Sin* 1984;27:161–8.
- 6 World Health Organization.  $\alpha$ 1-Antitrypsin deficiency: memorandum from a WHO meeting. *Bulletin World Health Organ* 1997;75:397–415.
- 7 Lee SS, Lawton JWM. Heterogeneity of anti-PR3 associated disease in Hong Kong. *Postgrad Med J* 2000;76:287–8.

## A case of cholesterol embolism with ANCA treated with corticosteroid and cyclophosphamide

We report a case of a patient with cholesterol embolism who showed positive for both myeloperoxidase antineutrophil cytoplasmic antibody (MPO-ANCA) and proteinase 3 antineutrophil cytoplasmic antibody (PR3-ANCA) and who was treated with prednisolone (PSL) and cyclophosphamide.

A 50 year old man underwent cardiac catheterisation for back pain. The examination disclosed 90% stenosis of the right coronary artery and a sacular aneurysm in the thoracic aorta. The patient underwent percutaneous transluminal coronary angioplasty and the aneurysm was wrapped with an artificial blood vessel. Postoperatively, the patient had a fever, pleural effusion, abdominal pain, and increased white blood cell (WBC) count, C reactive protein (CRP), and serum creatinine. Cultures of blood and pleural effusion exudate were negative. PSL 15 mg/day was started. However, acute progression of renal failure required haemodialysis.

The patient was transferred to our hospital. Physical examination showed a temperature of 38.0°C and blood pressure of 178/98 mmHg. Cyanosis was noted in both heels and all toes with necrosis and ulcers at the tips of the fifth toes. He had an increased erythrocyte sedimentation rate (ESR) of 82 mm/1st

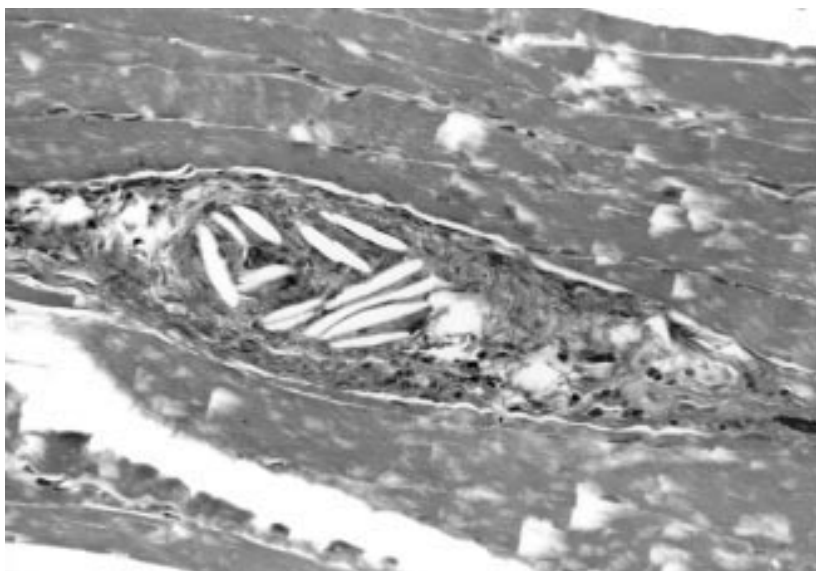


Figure 1 Skin biopsy specimen showing cholesterol embolism in arterioles within subcutaneous tissues (haematoxylin and eosin,  $\times$  400).

h. Anaemia was noted with a red blood cell count of  $2500 \times 10^9/l$ , while the patient's WBC count was high at  $12 \times 10^9/l$ . His platelet count ( $304 \times 10^9/l$ ) was within the normal range. Biochemistry showed high levels of blood urea nitrogen (10.0 mmol/l of urea), creatinine (710  $\mu$ mol/l), and CRP (11.3 mg/l). Complements components were within normal ranges. PR3-ANCA and MPO-ANCA were high at 82E and 29E, respectively.

After admission to hospital, circulatory disturbance in his toes worsened. A diagnosis of ANCA associated vasculitis was made based on systemic inflammatory findings and high levels of WBC, CRP, PR3-ANCA, and MPO-ANCA. High dose steroid treatment was started. Biopsies of the right heel skin and thigh quadriceps showed cholesterol embolism (fig 1). However, PSL treatment was continued together with three courses of cyclophosphamide pulse treatment because of persistent fever and high ANCA values. The treatment reduced the fever and toe necrosis, and the ulcers improved. ANCA gradually decreased to normal. The PSL dosage was reduced to 15 mg/day and the patient was discharged.

Cholesterol embolism predominantly affects elderly men with a history of hypertension, atherosclerotic vascular diseases, and renal insufficiency at the time of diagnosis. At least 31% of patients had a preceding history of anticoagulant use or the antecedent performance of a vascular procedure affecting the arterial circulation.<sup>1</sup> The presence of these cholesterol embolisms within the vascular lumen triggers a characteristic localised inflammatory and endothelial vascular reaction. The inflammatory changes resulting from cholesterol embolism may be responsible for many of the systemic manifestations such as fever, weight loss, myalgias, leucocytosis, eosinophilia, and a raised ESR. Thus cholesterol embolism is referred to as both vasculitis look-alikes<sup>2</sup> and pseudovasculitic syndrome.<sup>3</sup> The prognosis is poor, particularly in the presence of acute renal failure.<sup>4</sup>

Three ANCA positive cases<sup>5,6</sup> of cholesterol embolism have been described. Peat and Mathieson reported an ANCA positive patient with dyspnoea and haemoptysis after

acute deterioration of renal function.<sup>5</sup> Cyclophosphamide and PSL improved the symptoms, but cyclophosphamide was discontinued and the PSL dose was reduced because renal and skin biopsies showed cholesterol embolisms. Subsequently, the patient died of intractable cardiac failure.

Kaplan-Pavlovic *et al* reported two cases of renal failure with positive MPO-ANCA.<sup>6</sup> The details are unknown for one patient. The other patient was treated with corticosteroid alone. This patient required haemodialysis and amputation of the toes. Although their treatment did not result in the improvement of vasculitis, the combination of PSL and cyclophosphamide was effective in our patient with ANCA.

This result suggests that active treatment with corticosteroid and cyclophosphamide should be considered in ANCA positive cases of cholesterol embolism.

E MAESHIMA  
Y YAMADA  
M MUNE  
S YUKAWA

Third Department of Internal Medicine,  
Wakayama Medical College,  
811-1, Kimiidera, Wakayama City,  
Wakayama 641-0012, Japan

Correspondence to: Dr Maeshima

- 1 Fine MJ, Kapoor W, Falanga V. Cholesterol crystal embolization: a review of 221 cases in the English literature. *Angiology* 1987;38:768–84.
- 2 Lie JT. Vasculitis look-alikes and pseudovasculitis syndromes. *Curr Diagn Pathol* 1995;2:78–5.
- 3 Cappiello RA, Espinoza LR, Adelman H, Aguilar J, Vasey FB, Germain BF. Cholesterol embolism: a pseudovasculitic syndrome. *Semin Arthritis Rheum* 1989;18:240–6.
- 4 Thadani R, Camargo C Jr, Xavier R, Fang L, Bazari H. Atheroembolic renal failure after invasive procedures. Natural history based on 52 histologically proved cases. *Medicine (Baltimore)* 1995;74:350–8.
- 5 Peat DS, Mathieson PW. Cholesterol emboli may mimic systemic vasculitis. *BMJ* 1996;313:546–7.
- 6 Kaplan-Pavlovic S, Vizjak A, Vene N, Ferluga D. Antineutrophil cytoplasmic autoantibodies in atheroembolic disease. *Nephrol Dial Transplant* 1998;13:985–7.

## HLA-DRB1\*0301 and DQA1\*0501 in RA

Auranofin is an oral gold preparation used in the treatment of rheumatoid arthritis (RA). During treatment, proteinuria has been reported in approximately 3% of patients.<sup>1</sup> In a few cases in which renal biopsies were performed, a membranous nephropathy was shown to have developed.<sup>2</sup>

Several antirheumatic agents have been reported to induce renal manifestations or drug induced lupus reactions, or both, in patients with RA. In these subjects a genetic predisposition for HLA has previously been suggested.<sup>3-6</sup>

To determine whether similar genetic factors might be operative in auranofin induced nephropathy, we analysed the HLA-DRB1, DQA1, and DQB1 alleles using a polymerase chain reaction. Furthermore, we investigated if the renal side effects were associated with serological findings in accordance with systemic lupus erythematosus (SLE), thus indicating the development of a drug induced lupus reaction.

Six patients (three female, three male) who developed biopsy proven membranous nephropathy or significant proteinuria (>0.5 g/day) during treatment with auranofin are reported. All patients met the American College of Rheumatology criteria for RA.<sup>7</sup> The median age before onset of auranofin treatment was 72 (52–83) years, 4/6 patients were rheumatoid factor positive and 2/5 patients were antinuclear antibody (ANA) positive. The median duration of auranofin treatment before the onset of proteinuria was 5 (4–10) months.

During auranofin treatment, two patients developed an increased ANA titre (1/200 and 1/1600) but no antibodies against anti-dsDNA, SSA/SSB, Sm, or RNP were detected. None of the patients developed an increased serum creatinine level. After withdrawal of auranofin, proteinuria decreased significantly or disappeared in all cases.

Table 1 presents the HLA alleles.

A high frequency of the alleles associated with SLE—namely, DRB1\*0301 (DR3),

Table 1 HLA DRB1\*, DQA1\*, and DQB1\* alleles in patients with development of renal manifestations during auranofin treatment

Patient	DRB1*	DQA1*	DQB1*
1	0301, 0801	0501, 0401	0201/02, 0402
2	0101, 0301	0101, 0501	0501, 0201/02
3	1201, 1301	0501, 0103	0603, 03011
4	0101, 0301	0101, 0501	0501, 0201/02
5*	0401, 1301	0303, 0103	0301, 0603
6*	0101, 0301	0101, 0102	0501, 0602

\*No renal biopsy was performed in these patients.

DQA1\*0501, and DQB1\*0201, was recorded in the patients developing membranous nephropathy or proteinuria during auranofin treatment. Of these, DRB1\*0301 and DQA1\*0501 occurred in 4/6 of the patients, and 5/6 patients carried at least one of these alleles.

The importance of DR3 or DQA1\*0501 in drug induced renal manifestations has previously been suggested in patients with penicillamine and sodium aurothiomalate induced renal side effects.<sup>3,5</sup> Also, in accordance with these findings, the DQA1\*0501 and DRB1\*0301 alleles have been recorded in a high frequency in patients developing sulfasalazine induced nephritis.<sup>6</sup>

In two cases the development of membranous nephropathy was accompanied by a simultaneous increase in the ANA titre, thus indicating development of a drug induced SLE reaction.<sup>8</sup> However, both patients had previously presented some sign of an autoimmune reactivity pattern, which may confer a risk factor in the treatment with certain antirheumatic drugs in RA.

Simultaneous treatment with sulfasalazine had been given in two cases, but as the sulfasalazine treatment period was either limited, or lacked any time relation with the onset of proteinuria, it seems unlikely that the patients developed a drug reaction against sulfasalazine. Further arguments rejecting the possibility of a sulfasalazine induced drug reaction are the lack of anti-dsDNA antibodies and the rapid onset of proteinuria among the patients, thus contrasting with the findings reported in sulfasalazine induced SLE.<sup>6</sup>

The mechanism for induction of membranous nephropathy during auranofin treatment is unknown. Interestingly, it has been suggested that gold can bind to and alter major histocompatibility complex-peptide complexes,<sup>9</sup> thus giving a possible explanation of both beneficial effects as well as side effects during treatment. Another possibility is that auranofin may alter the cytokine pattern towards an SLE-like phenotype and thus facilitate the development of SLE associated manifestations in genetically susceptible subjects. In accordance with this hypothesis, auranofin or other gold preparations have been reported to inhibit the production of interleukin 1 (IL1), tumour necrosis factor  $\alpha$ , and IL2.<sup>10</sup> The effects on IL10, a cytokine reported to be increased in both patients with idiopathic SLE and their healthy relatives<sup>11</sup> as well as in patients developing sulfasalazine induced SLE-like reactions,<sup>12</sup> is unknown, however.

In conclusion, the data suggest that SLE related HLA alleles, with special focus on DRB1\*0301 and DQA1\*0501, may predispose to development of renal side effects or

drug induced lupus reactions during treatment with auranofin, as also previously recorded during treatment with other antirheumatic agents. Development of drug induced SLE, here reported for the first time, may occur during auranofin treatment.

I GUNNARSSON  
B RINGERTZ

Department of Rheumatology,  
Karolinska Hospital,  
Stockholm, Sweden

J BRATT

Department of Rheumatology,  
Huddinge Hospital,  
Stockholm, Sweden

B SUNDELIN

Department of Pathology and Cytology,  
Karolinska Hospital,  
Stockholm, Sweden

Correspondence to: Dr I Gunnarsson, Department of Rheumatology, D2:01, Karolinska Hospital, S-171 76 Stockholm, Sweden  
iva.gunnarsson@ks.se

- Katz WA, Blodgett RC, Pietrusko RG. Proteinuria in gold-treated rheumatoid arthritis. *Ann Intern Med* 1984;101:176–9.
- Heuer MA, Pietrusko RG, Morris RW, Scheffler BJ. An analysis of worldwide safety experience with auranofin. *J Rheumatol* 1985;12:695–9.
- Wooley P, Griffin J, Panayi G, Batchelor J, Welsh K, Gibson T. HLA-DR antigens and toxic reaction to sodium aurothiomalate and D-penicillamine in patients with rheumatoid arthritis. *N Engl J Med* 1980;303:300–2.
- Emery P, Panayi G, Huston G, Welsh K, Mitchell S, Shah R, *et al.* D-penicillamine induced toxicity in rheumatoid arthritis: the role of sulphoxidation status and HLA-DR3. *J Rheumatol* 1984;11:626–32.
- Sakkas LJ, Chikanza IC, Vaughan RW, Welsh KI, Panayi GS. Gold induces nephropathy in rheumatoid arthritis and HLA class II genes. *Ann Rheum Dis* 1993;52:300–1.
- Gunnarsson I, Kanerud L, Pettersson E, Lundberg I, Lindblad S, Ringertz B. Predisposing factors in sulphasalazine-induced systemic lupus erythematosus. *Br J Rheumatol* 1997;36:1089–94.
- Arnett F, Edworthy S, Bloch D, McShane D, Fries J, Cooper N, *et al.* The American Rheumatism Association 1987 revised criteria for the classification of rheumatoid arthritis. *Arthritis Rheum* 1988;31:315–24.
- Cush JJ, Goldings EA. Southwestern Internal Medicine Conference: drug-induced lupus: clinical spectrum and pathogenesis. *Am J Med Sci* 1985;290:36–45.
- Romagnoli P, Spinaz GA, Sinigaglia F. Gold-specific T cells in rheumatoid arthritis patients treated with gold. *J Clin Invest* 1992;89:254–8.
- Barrera P, Boerbooms AMT, van de Putte LBA, van der Meer JWM. Effects of antirheumatic agents on cytokines. *Semin Arthritis Rheum* 1996;25:234–53.
- Llorente L, Richaud-Patin Y, Couderc J, Alarcon-Segovia D, Ruiz-Soto R, Alcocer-Castillejos N, *et al.* Dysregulation of interleukin-10 production in relatives of patients with systemic lupus erythematosus. *Arthritis Rheum* 1997;40:1429–35.
- Gunnarsson I, Nordmark B, Hassan Bakri A, Gröndal G, Larsson P, Forslid J, *et al.* Development of lupus-related side-effects in patients with early RA during sulphasalazine treatment – the role of IL-10 and HLA. *Rheumatology* 2000;39:886–93.