

## CONCISE REPORTS

## Quantitative ultrasonography in rheumatoid arthritis: evaluation of inflammation by Doppler technique

E Qvistgaard, H Røgind, S Torp-Pedersen, L Terslev, B Danneskiold-Samsøe, H Bliddal

### Abstract

**Objective**—To evaluate ultrasonographic methods, including the Doppler technique, as measures of synovial inflammation in finger joints of patients with rheumatoid arthritis.

**Methods**—Ultrasonography was performed with a high frequency transducer (13 MHz).

Evaluation of the sonographic data was conducted by two independent observers and included measurement of synovial area and thickness (grey tone ultrasound), vascularisation (power/colour Doppler), and indices of the intra- and extrasynovial arterial flow (spectral Doppler). The flow pattern was estimated by the indices of pulsatility (PI) and resistance (RI).

**Results**—The sonographic measurements of joint space were reproducible with intraobserver, intraclass correlation coefficients (ICC) 0.82–0.97 ( $p < 0.0001$ ) and interobserver ICC 0.81 ( $p < 0.0001$ ). The mean (SD) fraction of the synovium vascularised in the patients was 0.15 (0.15). The synovial blood flow was characterised by a diastolic flow—that is, the flow persisting during the diastole. The mean (SD) PI was 1.92 (1.18) and RI 0.70 (0.13). The estimated vascular fraction correlated with the erythrocyte sedimentation rate (ESR) ( $r_s = 0.53$ ,  $p = 0.03$ ). The relative Pi (rPi), an estimate of an abnormally low resistance to vascularisation, correlated with both ESR ( $r_s = -0.557$ ,  $p < 0.05$ ) and Health Assessment Questionnaire score ( $r_s = -0.584$ ,  $p < 0.05$ ). After an injection of contrast Levovist the vascular fraction increased, while no difference in PI and RI was observed.

**Conclusion**—Ultrasonography is a reliable tool for estimating the size of the joint space and the synovial activity measured by the degree of vascularisation and pattern of flow. Ultrasonography may be useful in monitoring the synovial inflammation in rheumatoid arthritis.

(Ann Rheum Dis 2001;60:690–693)

To monitor treatment in rheumatoid arthritis (RA) a precise measure of the disease activity

should be obtained by both clinical and paraclinical parameters.<sup>1</sup>

The disease activity of a joint is correlated with the synovial vascularisation,<sup>2,3</sup> which can be estimated by magnetic resonance imaging (MRI) measurement of synovial membrane volumes after intravenous gadolinium injection. This examination is relatively expensive and time consuming. It would be of advantage for both patient and therapist if a similar estimate could be obtained by ultrasonography directly in the outpatients' clinic.

Ultrasonography has proved to be valuable in the morphological and structural assessment of soft tissue in patients with arthritis.<sup>4</sup> With modern high quality sonographic equipment, colour/power Doppler can be used to determine the flow even in small blood vessels. This, again, may give an estimate of the presence and extent of inflammation.<sup>5,6</sup>

The purpose of this study was to evaluate the sonographic technique, including the Doppler technique, as a supplement to the clinical evaluation of synovitis in RA.

Moreover, the value of ultrasound contrast media was tested in the quantification of vascularisation of the synovial membrane in patients with RA.

### Patients and methods

A total of 18 patients with RA according to the American College of Rheumatology criteria agreed to participate in the study. Their mean age was 60 years (range 30–78) and mean duration of RA 7.6 years (range 2–10). The patients were receiving stable treatment with a disease modifying antirheumatic drug or Enbrel in the three months before the investigation, and during this period the patients had had no injections of glucocorticosteroids.

The patients were evaluated clinically with the Health Assessment Questionnaire (HAQ) score, number of tender and swollen joints, and blood tests were drawn for measurement of erythrocyte sedimentation rate (ESR) and C reactive protein (CRP).

### ULTRASONOGRAPHY

The patients were scanned with an Acuson Sequoia (Mountainview, California, USA) using a near-focused transducer with a centre frequency of 13 MHz.

The Parker Institute,  
Department of  
Rheumatology,  
Frederiksberg  
Hospital, DK 2000  
Frederiksberg,  
Denmark  
E Qvistgaard  
H Røgind  
L Terslev  
B Danneskiold-Samsøe  
H Bliddal

Ultrasound  
Laboratory, Gentofte  
County Hospital,  
Denmark  
S Torp-Pedersen

Correspondence to:  
Professor H Bliddal  
henning.bliddal@fh.hosp.dk

Accepted 9 January 2001

Additional Doppler images  
appear on the Annals web site  
at [www.annrheumdis.com](http://www.annrheumdis.com)

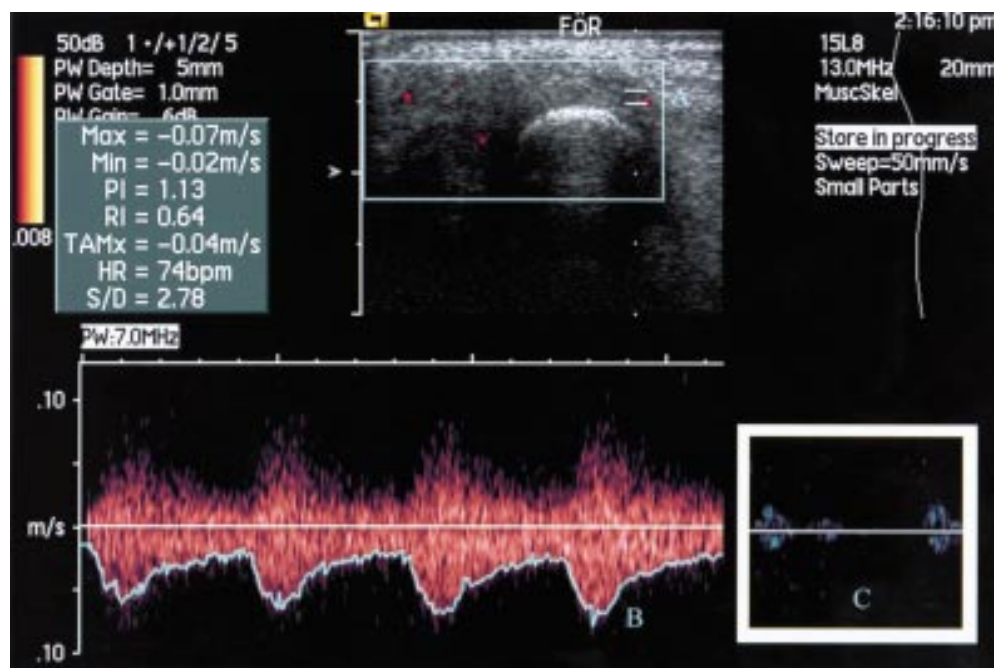


Figure 1 Analysis of the flow pattern with spectral Doppler utility. A = vessel chosen for the analysis; B = blood velocity. Note the persistent flow in the diastole. Pulsatility (PI) and resistance (RI) are calculated automatically by the program. C = an example of normal musculoskeletal flow. Note the absence of diastolic flow.

Scanning was run on the joint perceived by the patient as being the most inflamed, either the metacarpophalangeal, proximal interphalangeal, or the wrist joint. In this joint the synovial membrane was visualised and maximal area and thickness were determined in two dimensions. The blood flow in the region was visualised by colour Doppler and an image with maximal colour activity was selected for analysis.

With the aid of spectral Doppler the quality of flow was determined (fig 1) and the indices of pulsatility (PI) and resistance (RI) were measured in three arteries within the synovial membrane and in a neighbouring muscle as control. PI was defined as (maximum systolic velocity – end diastolic velocity)/maximum velocity. To characterise the relation between flow inside and outside the joint, the ratio between indices was calculated:  $rPI=PIs/PIx$  and  $rRI=RIx/RIx$ . Both PI and RI correlate with an increased peripheral resistance, indicating a decrease in perfusion of the tissue.<sup>7 8</sup>

An intravenous injection of ultrasound contrast agent (Levovist, Schering) was given and synovial flow was monitored with unchanged colour Doppler settings until maximum effect was judged to be present (fig 2A). An image was selected for analysis and spectral Doppler measurements were repeated.

#### DATA EVALUATION

The quantitative estimation of the vascularisation in the synovial membrane was performed in the following way: the digitally stored UL pictures were read with a DICOM-compatible program. The unchanged pictures were then transferred to a processing program (Corel photo-paint 7).

All the coloured pixels on the Doppler sonographic picture correspond to motion. When

noise has been reduced to a minimum they may be interpreted as blood flow (fig 2A). The colour recognition function was used to change all marked pixels to a reference colour. The total number of pixels was finally depicted using a colour histogram (fig 2B).

Clinical evaluation included the HAQ, pain on a 100 mm visual analogue scale, the doctor's global assessment, and patient's global assessment. Global inflammatory activity was assessed by ESR and CRP.

The examiner was unaware of the clinical status and treatment of the patients.

#### STATISTICS

Non-parametric statistical methods were applied with a level of significance of 0.05.

#### OBSERVER VARIATION

The data processing was performed by two independent investigators evaluating the randomly numbered pictures. They were unaware of the name of the patient, the time of investigation, and the treatment given. The procedure was repeated after one month by the two investigators using the same pictures.

## Results

#### ULTRASONOGRAPHIC EVALUATION

In most cases the synovial membrane could clearly be depicted from the surrounding tissue by the sonographic examination. It was subsequently possible with the aid of power Doppler to choose arteries both intrasynovially and extrasynovially for measurement by spectral Doppler. Joint effusion was rarely seen and the amount of fluid in these cases was of no importance for the area measurements.

The profile of the arteries measured with spectral Doppler was qualitatively determined to be from areas with a low vascular

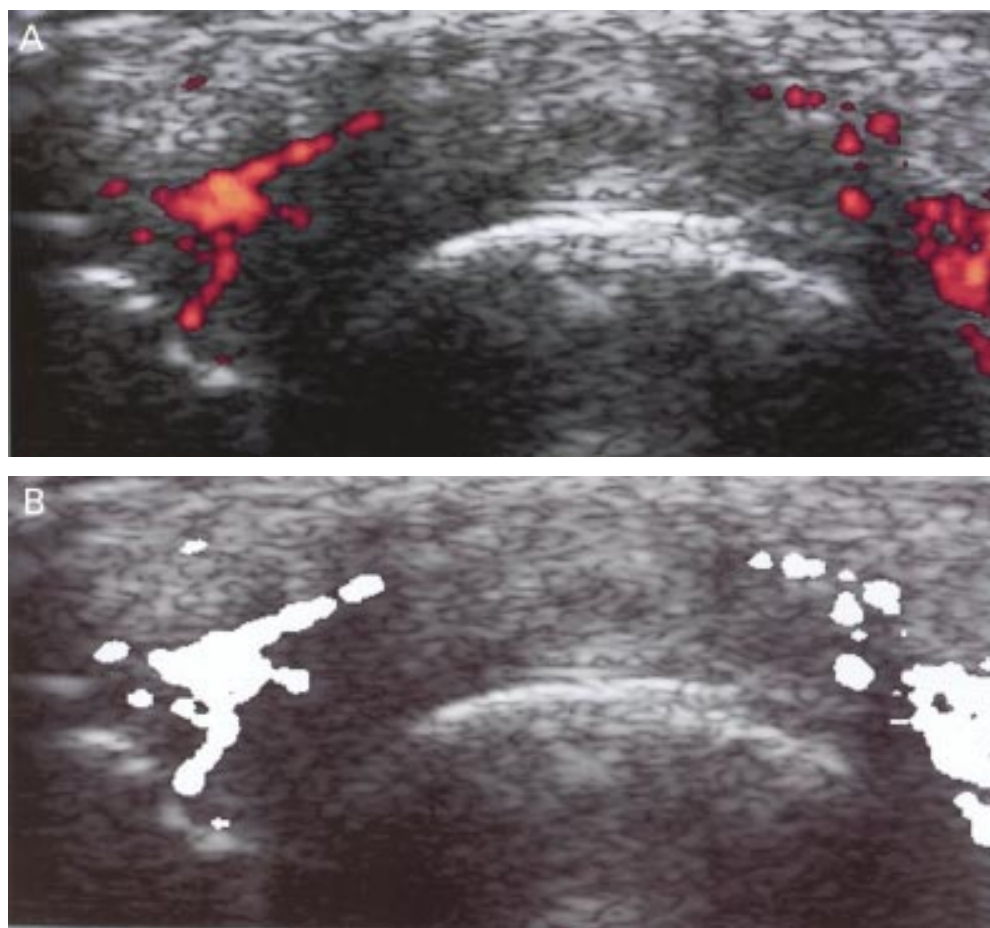


Figure 2 (A) Longitudinal scan of two metacarpophalangeal joints after injection of contrast (Levovist). (B) All coloured fields are replaced with a monochrome colour (white). Using a histogram facility, it is possible to assess the area of the outlined synovial membrane and blood vessels within the limits chosen.

Table 1 Correlation between the vascular fraction at baseline measured by investigator 1 and the variable listed below

ESR† baseline	0.534*
VAS† baseline	0.229
Doctor global baseline	0.406
Patient global baseline	0.146
HAQ† baseline	0.152

\*Correlation is significant at the 0.05 level (two tailed) Spearman's correlation.

†ESR = erythrocyte sedimentation rate; VAS = visual analogue score; HAQ = Health Assessment Questionnaire.

resistance—that is, with a persistent flow present during the diastole. The ESR correlated with the vascularisation of the synovial membrane, both when measured as a vascular fraction ( $n=16$ ,  $r_s=0.53$ ,  $p=0.03$ ) and as a vascular pixel area ( $n=16$ ,  $r_s=0.48$ ,  $p=0.05$ ). No other correlations were found between the clinical data and synovial or vascular pixel areas (table 1).

The ratio indices rPi also correlated with the ESR ( $n=13$ ,  $r_s=-0.557$ ,  $p=0.048$ ) and HAQ ( $n=13$ ,  $r_s=-0.584$ ,  $p=0.036$ ).

After the intravenous injection of contrast there was an increase in vessels depicted by the power Doppler. However, no further significant changes in rPi and rRI were found.

#### RELIABILITY

The two investigators measured the pixel area of the synovial vessels twice. The intraclass

correlation coefficient (ICC) of 74 evaluable double measurements was for investigator 1, 0.97 ( $p<0.0001$ ) and for investigator 2, 0.82 ( $p<0.0001$ ).

Intertester reliability was tested in the first evaluation of the pictures and the ICC between investigators 1 and 2 was 0.81 ( $n=75$ ,  $p<0.0001$ ).

#### Discussion

This study showed a consistent and reproducible delineation of the inflamed synovial membrane in the small joints of the hands or fingers of patients with active RA. The grey tone ultrasonographic pictures gives an overview of the amount of swelling of the tissue around the joints. However, in our study this was not related to clinical data. This observation is in accordance with other studies, which have found a lack of correlation between clinical parameters and similar determinations of synovial area and volume by ultrasound and MRI.<sup>3,9</sup> An explanation for this apparent inconsistency may be the varying amount of fibrous tissue in the synovial membrane. In almost all patients an abnormal presence of arteries could be demonstrated by colour Doppler, and by measuring the area of these arteries, an estimate could be obtained of the perfused part of the synovial membrane corresponding to the activity of the RA in the joint.



By the same argument, areas without signs of vascularisation may represent dormant synovium or fibrous tissue from previous healed attacks of synovitis. It must be realised, however, that the ultrasonographic measurement is only representative of the perfusion at the precise moment and variations during the day should be clarified in future studies.

Our method of determining colour pixels through a simple picture-handling program allowed a quantitative analysis of the degree of vascularisation, and the clinical relevance was indicated by the correlation with the ESR. It remains to be seen whether this quantitative measure offers a better way of monitoring the outcome of treatment than the semiquantitative tests proposed in former studies.<sup>10 11</sup> In our patients, and in accordance with other studies, several erosions were seen that were non-discernible, or barely discernible, on conventional radiography. However, there was no indication of specific areas of the synovium being vascularised more often than others, and we found no preponderance of blood flow near the erosions of the joints.

The synovial perfusion was not only abnormal owing to its increased number of arteries, as evidenced by the colour Doppler, and when spectral Doppler was used the arterial perfusion of the tissue showed persistent flow during the diastole. The flow curve of the vessels in the rheumatoid synovial membrane may be altered by the inflammation; the diastolic perfusion, in particular, being unusual in resting musculoskeletal tissue. A high diastolic flow is normal in, for example, renal, cerebral, and umbilical arteries, where a low peripheral resistance assures a permanent and high perfusion. In other parts of the body resting tissue has a high peripheral resistance and a deviation from this indicates inflammation, malignancy, or arteriovenous malformations.<sup>7</sup> Also, measurements of the pulsatility and resistance indices are used to characterise perfusion. In our study calculation of the indices was based on extrasynovial control arteries in the tissue immediately surrounding the joint. These arteries might have been affected by the presence of inflammatory tissue nearby, and for future, more sophisticated calculations muscle tissue distal from the joint should be chosen for the purpose of comparison with the synovial vessels.

It may be noted that the disclosure of small synovial arteries for such measurements requires highly sensitive sonographic equipment. The use of ultrasound contrast agents may increase sensitivity in the event of diminished synovial vascularisation and may also be of value in situations involving the use of suboptimal equipment.

In comparison with MRI, ultrasonography has the advantage of being more readily accessible and far cheaper. In the not too distant future sonographic equipment may be available in many rheumatology departments. Teaching simple procedures, such as estimating local signs of inflammation or finding minor effusions in the joint, will be simplified, thus pointing to yet another application for ultrasonography in the daily clinic.

During the editorial evaluation of this article an observation of Doppler ultrasonography in Raynaud's syndrome has been published.<sup>12</sup> In that article a specific computer program was employed for the detection of colour pixels in the region of interest. However, as shown above, an ordinary colour program may be used with reproducible results.

We thank Acuson for the loan of the Sequoia ultrasonographic equipment and Schering for the donation of half of the Levovist used in this study.

The study was supported by the Oak Foundation.

- 1 ACR ad hoc committee. Guidelines for the management of rheumatoid arthritis. American College of Rheumatology Ad Hoc Committee on Clinical Guidelines. *Arthritis Rheum* 1996;39:713-22.
- 2 Lindblad S, Hedfors E. Intraarticular variation in synovitis. Local macroscopic and microscopic signs of inflammatory activity are significantly correlated. *Arthritis Rheum* 1985; 28:977-86.
- 3 Ostergaard M, Hansen M, Stoltenberg M, Gideon P, Klarlund M, Jensen KE, *et al*. Magnetic resonance imaging-determined synovial membrane volume as a marker of disease activity and a predictor of progressive joint destruction in the wrists of patients with rheumatoid arthritis. *Arthritis Rheum* 1999;42:918-29.
- 4 Grassi W, Lamanna G, Farina A, Cervini C. Synovitis of small joints: sonographic guided diagnostic and therapeutic approach. *Ann Rheum Dis* 1999;58:595-7.
- 5 Babcock DS, Patriquin H, Lafortune M, Dauzat M. Power Doppler sonography: basic principles and clinical applications in children. *Pediatr Radiol* 1996;26:109-15.
- 6 Newman JS, Laing TJ, McCarthy CJ, Adler RS. Power Doppler sonography of synovitis: assessment of therapeutic response—preliminary observations [see comments]. *Radiology* 1996;198:582-4.
- 7 Bude RO, Rubin JM. Effect of downstream cross-sectional area of an arterial bed on the resistive index and the early systolic acceleration. *Radiology* 1999;212:732-8.
- 8 Adamson SL. Arterial pressure, vascular input impedance, and resistance as determinants of pulsatile blood flow in the umbilical artery. *Eur J Obstet Gynecol Reprod Biol* 1999;84:119-25.
- 9 Backhaus M, Kamradt T, Sandrock D, Loreck D, Fritz J, Wolf KJ, *et al*. Arthritis of the finger joints: a comprehensive approach comparing conventional radiography, scintigraphy, ultrasound, and contrast-enhanced magnetic resonance imaging. *Arthritis Rheum* 1999;42:1232-45.
- 10 Hau M, Schultz H, Tony HP, Keberle M, Jahns R, Haerten R, *et al*. Evaluation of pannus and vascularization of the metacarpophalangeal and proximal interphalangeal joints in rheumatoid arthritis by high-resolution ultrasound (multidimensional linear array). *Arthritis Rheum* 1999;42: 2303-8.
- 11 Stone M, Whelan B, Bergin D, Maher M, Murray J, McCarthy CJ. Power Doppler ultrasonography in metacarpophalangeal joint synovitis [abstract]. *Ann Rheum Dis* 1999;EULAR suppl:29.
- 12 Keberle M, Tony HP, Jahns R, Hau M, Haerten R, Jenett M. Assessment of microvascular changes in Raynaud's phenomenon and connective tissue disease using colour Doppler ultrasound. *Rheumatology (Oxford)* 2000;39:1206-13.