

Radiographic assessment of patellofemoral osteoarthritis

A C Jones, J Ledingham, T McAlindon, M Regan, D Hart, P J MacMillan, M Doherty

Abstract

Objectives—To determine the feasibility of assessing patellofemoral osteoarthritis using the 'skyline' view and to compare its reproducibility with the standard lateral view.

Methods—Fifty patients attending a rheumatology outpatient department with osteoarthritis of the knee had standard radiographs taken of both knees: standing weightbearing anteroposterior; lateral supine radiograph in 30° of flexion; and a skyline view of the patellofemoral joint. After an initial training period using 20 sets of films the remaining 30 sets were read blind by five observers. Intraobserver and interobserver variability was assessed using the κ statistic. The minimum joint space in each compartment was measured using a ruler. Two views of a single normal subject were measured to determine the effect of knee flexion.

Results—The final 30 study films were from 20 women and 10 men, median age 72.5, range 18–91 years. A grading system comprising assessment of osteophytosis, joint space narrowing, sclerosis, cysts, and attrition could easily be applied to the skyline patellofemoral view. Intraobserver reproducibility was better than the interobserver reproducibility for all features. The skyline view performed more reproducibly and over a wider range of categorisation for joint space narrowing than the lateral radiograph. Measurement using a ruler was easy to perform and precise to within 1 mm for the medial tibiofemoral and lateral facet of the patellofemoral joint. In normal knees the degree of flexion significantly affected the measurement.

Conclusions—Radiographic grading of the skyline patellofemoral view is readily achieved, is more reproducible than assessment of the lateral view, and allows more precise localisation of change. Such views should be considered in radiological surveys of osteoarthritis of the knee.

(*Ann Rheum Dis* 1993; 52: 655–658)

Patellofemoral osteoarthritis is common and important, and may occur in association with or in isolation from osteoarthritis in other compartments of the knee.^{1–3} Its importance may, however, have been previously underestimated as many surveys have not routinely incorporated patellofemoral radiographs. In-

deed, although assessment of plain radiographs is currently the gold standard used to assess structural changes in osteoarthritis of the knee, the most commonly used system of radiographic assessment of osteoarthritis does not include the patellofemoral joint.⁴ In those grading systems that include the patellofemoral joint, this grading is hampered by the poor reproducibility of the lateral radiograph in assessing the features of patellofemoral osteoarthritis.⁵

The 'skyline' patellar view has been suggested to be more sensitive in assessing patellofemoral osteoarthritis⁶ and in addition may allow more precise compartmentalisation of such change. We are unaware of any formal studies which address the relative sensitivities and reproducibility of the different patellofemoral views, however. This study is an attempt to develop a grading system for the patellofemoral joint and to assess its reproducibility and sensitivity compared with other methods of compartmental evaluation of the knee joint.

Patients and methods

PATIENTS

Fifty patients with osteoarthritis of the knee attending a rheumatology clinic were studied.

RADIOGRAPHIC ASSESSMENT

The following views of both knee joints were obtained: (a) a standing weightbearing anteroposterior radiograph of the tibiofemoral joint (55 kV, 8 mA s, full scale deflection (FSD) 100 cm); (b) a lateral radiograph of the knee taken in 30° of flexion (55 kV, 8 mA s, FSD 100 cm; fig 1A); and (c) a skyline view of the patellofemoral joint taken in 30° of flexion (60 kV, 10 mA s, FSD 100 cm; fig 1B).⁷

Twenty sets of films were assessed by two of the investigators (PM and AJ) to determine the feasibility of a grading system for the skyline view based on the elements of two popular grading systems which assess the individual features of osteoarthritis.^{6,8} The features chosen were joint space narrowing, osteophyte, sclerosis, cysts, and bone attrition. After this preliminary assessment the same 20 sets of radiographs were used by all the observers, including the consultant radiologist, in a training session to formulate the final chosen grading system (table 1).

INTRAOBSERVER VARIABILITY

This was assessed by two observers (AJ and JL/MR) independently grading a further 30 sets of

Rheumatology Unit,
City Hospital,
Nottingham,
United Kingdom

A C Jones
J Ledingham
M Regan
M Doherty

St Thomas's Hospital,
London,
United Kingdom
T McAlindon

St Bartholomew's
Hospital,
London,
United Kingdom
D Hart

Department of
Radiology,
City Hospital,
Nottingham,
United Kingdom
P J MacMillan

Correspondence to:
Dr A C Jones,
Rheumatology Unit,
City Hospital,
Nottingham NG5 1PB,
United Kingdom.

Accepted for publication
26 May 1993

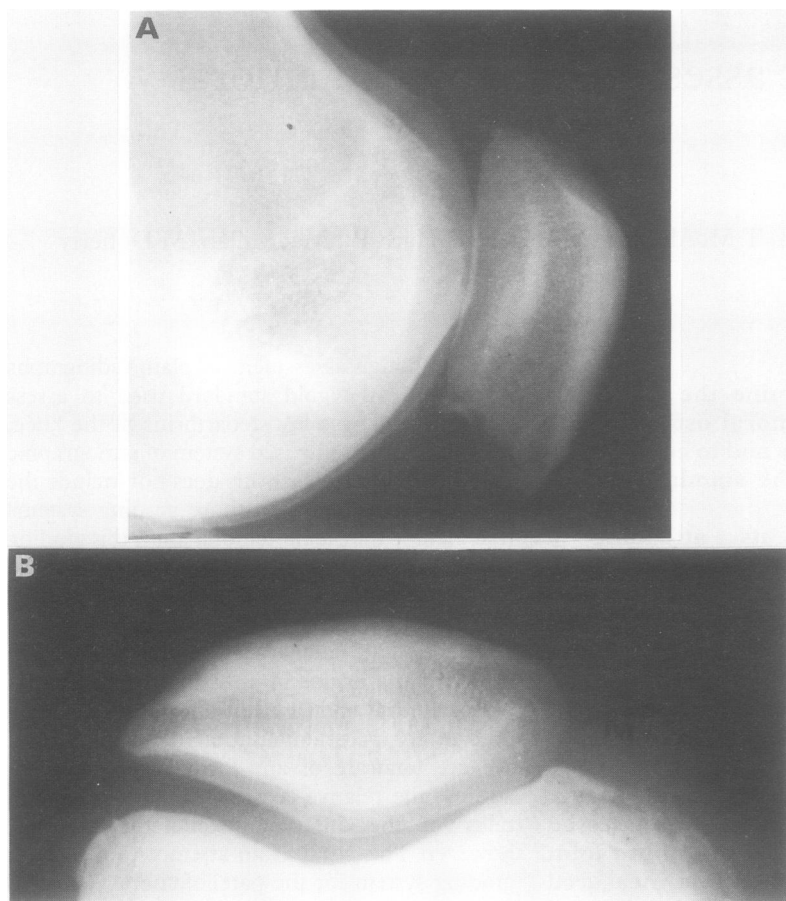


Figure 1 (A) Lateral and (B) skyline views of the same patient showing the different perception of joint space narrowing that may be apparent in the two views and the ability of the skyline view to assign this to a specific compartment (medial).

Table 1 Definition of grades for each of the individual features assessed

Feature	Grade			
	0	1	2	3
Joint space narrowing	None	Minimal	Moderate	Total joint space loss
Osteophyte	None	Small, definite	Moderate	Large
Cysts	None	One to two small cysts	Single large or multiple cysts	Multiple large cysts
Sclerosis	None	Possible	Definite	Widespread
Attrition	None	Loss of bone stock		

films, thought to represent a spectrum of abnormality, on two occasions one week apart and without knowledge of the previous assessment. Each film was read 'blind' and independently from other views from the same patient. The individual joint compartments assessed were the medial and lateral tibiofemoral joints, the lateral patellofemoral joint, and the medial and lateral facets of the patellofemoral joint (as assessed by the skyline view).

INTEROBSERVER VARIABILITY

Five observers (TM, DH, AJ, PM, and JL/MR (acting as a consensus)) independently assessed the same 30 sets of films.

OBJECTIVE MEASUREMENTS

Minimum joint space in each of the compartments was assessed on two occasions using a ruler. Two views of a single normal subject in two different degrees of flexion were

measured to determine how positioning might affect this assessment.

RELATIONSHIP OF ABNORMALITIES IN THE DIFFERENT VIEWS

This was assessed using the grading as attributed by the consensus observers JL/MR.

STATISTICAL ANALYSIS

Measurement of agreement was assessed using the κ coefficient.⁹ Determination of the major sources of disagreement was assessed using the weighted κ .¹⁰ A computer program facilitated calculation of the two observer weighted κ coefficients.¹¹

Results

PATIENTS

The 30 patients used for the final grading included 20 women and 10 men, median age 72.5, range 18–91 years.

RADIOGRAPHS

Complete sets of films were available for all patients, giving a total of 60 knees. As graded by the consensus observers (MR/JL) the number of knees showing definite (grade ≥ 2) joint space narrowing and osteophytosis in each compartment (equivalent to Kellgren and Lawrence grade 3) were 20 medial tibiofemoral, six lateral tibiofemoral, and 32 lateral patellofemoral compartments assessed on the lateral view. In the skyline view 31 had osteophytosis greater or equal to grade 2 in the medial and 39 in the lateral facet. The results for greater or equal to grade 2, moderate joint space loss were nine and 34 knees respectively.

SKYLINE VERSUS LATERAL PATELLOFEMORAL VIEWS

The grading system was found to be easy to apply to the skyline patellofemoral view.

Intraobserver agreement is shown for unweighted and weighted κ coefficients (table 2). The skyline view performed more reproducibly than assessment of the lateral patellofemoral view for joint space narrowing. In addition, assessment of joint space was more reproducible over a wider range of categorisation. Cysts and sclerosis performed relatively poorly in the two views. The scores attributed by the consensus observers (JL/MR) were generally better than those obtained by the individual observer (AJ).

Interobserver reproducibility was poorer than intraobserver reproducibility (table 3). The same basic observations are made, however: cysts and sclerosis are difficult to grade and the skyline view provides a more reproducible and subtle measure of joint space narrowing. Indeed, similar κ values are obtained for the skyline and anteroposterior views. The skyline view is particularly reproducible for assessing lateral facet joint space narrowing.

Table 2 Intraobserver κ coefficients shown unweighted and dichotomised at the level of grade 2 change. Blanks are where either the calculation of a κ value was not possible, or else it was less than zero

Feature*	AJ-JL/MR	
	κ	0-1 v 2-3
AP lateral joint space narrowing	0.35-0.75	0.82-1.0
AP medial joint space narrowing	0.75-0.81	0.93-0.80
AP lateral osteophyte	0.47-0.92	0.77-0.90
AP medial osteophyte	0.59-0.79	0.80-0.80
Lateral PF joint space narrowing	0.67-0.76	0.90-0.86
Lateral PF osteophyte	0.76-0.84	0.78-0.90
Lateral PF sclerosis	0.73-0.43	0.84-0.29
Lateral PF cysts	0.34-0.54	0.55-0.57
Lateral attrition	0.65-0.73	—
SL lateral joint space narrowing	0.74-0.90	0.80-0.97
SL medial joint space narrowing	0.71-0.76	0.74-0.79
SL lateral osteophyte	0.72-0.75	0.89-0.93
SL medial osteophyte	0.50-0.82	0.73-0.83
SL lateral sclerosis	0.56-0.43	0.79-0.47
SL medial sclerosis	0.19-0.32	—
SL lateral cysts	0.52-0.65	0.55-0.57
SL medial cysts	0.48-0.52	0.38-0.20
SL lateral attrition	0.26-0.83	—

*AP=anteroposterior; PF=patellofemoral; SL=skyline.

Table 3 Overall unweighted κ values for the various features

Feature	View/compartment*				
	AP		Lat PF	Skyline	
	Lat TF	Med TF		Lat facet PF	Med facet PF
Joint space narrowing	0.34	0.46	0.34	0.68	0.33
Osteophyte	0.41	0.36	0.46	0.38	0.42
Sclerosis	-0.46	0.26	-0.17	0.13	0.06
Cysts	0.11	0.16	0.13	0.22	0.18
Attrition	0.15	0.68	0.46	0.47	n/a

*TF=tibiofemoral; PF=patellofemoral; AP=anteroposterior; Lat=lateral; Med=medial.

Table 4 Concordance of joint space narrowing in the two patellofemoral views

Joint space narrowing: lateral view	Maximum joint space narrowing: skyline view			
	0	1	2	3
0	3	1	2	0
1	6	2	0	0
2	6	5	8	2
3	0	0	4	21

Table 5 Concordance of osteophyte grade in the two patellofemoral views

Osteophyte grade: lateral view	Maximum osteophyte grade: skyline view			
	0	1	2	3
0	3	2	2	0
1	2	5	7	3
2	1	1	19	12
3	0	1	0	2

Joint space measurement using a ruler was easy to perform for the two most commonly assessed sites, the medial tibiofemoral joint and the lateral facet of the patellofemoral joint. Measurement to within 1 mm (that is, within the limits of the technique) were possible at the two sites with one exception, a patient with a large cortical femoral defect in whom it was difficult to determine the site of minimum joint space in the medial tibiofemoral compartment. Measurement of the lateral tibiofemoral joint and the medial facet of the patellofemoral joint was less reproducible. The relation between measured joint space and grade for the skyline views is shown (fig 2).

In the normal knee, position had a significant influence on the absolute measured distance. At 30° of flexion the lateral facet distance was 7 mm, whereas in 90° of flexion this was reduced to 5 mm. Measurement of the patellofemoral joint from the lateral view was impossible owing to difficulties in determining precise relations.

SENSITIVITY

The association between joint space narrowing and osteophytosis in the different views of the patellofemoral joint is complex. Figure 1 and tables 4 and 5 show the relation between the two views. The skyline score is derived from the worst category for either of the facets. Although the sample is small there was some degree of discordance for the two features and the resulting distributions differed from that predicted (χ^2). There was a decreased frequency of grade 2-3 joint space loss on the skyline view and an increased frequency of grade 2-3 osteophytosis.

Discussion

This study shows that skyline views can be easily and reproducibly assessed for the presence of the features of osteoarthritis. Furthermore, use of this view has several advantages over the evaluation of lateral radiographs: it is more reproducible; a greater range of abnormality of joint space can be assessed; joint space narrowing can be

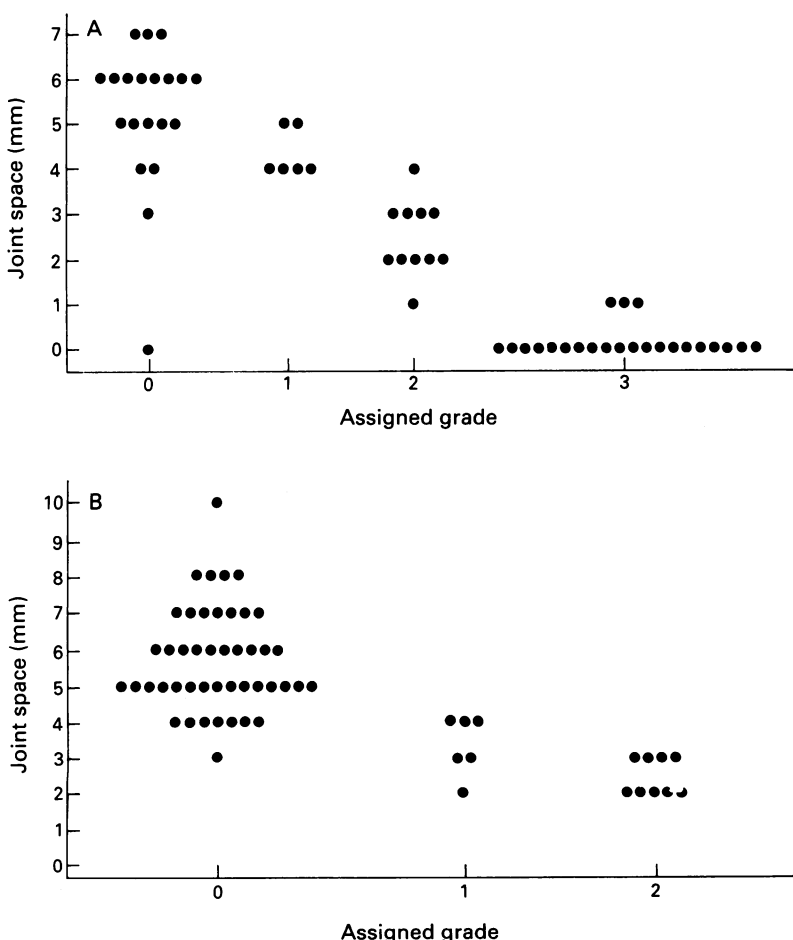


Figure 2 Measured joint space plotted against grade of joint space narrowing assigned to the (A) lateral and (B) medial facet of the patellofemoral joint by the consensus observers (JL/MR).

measured with a ruler; precise compartmentalisation to the lateral and medial facets is possible; and it may be more sensitive to change. We believe that the skyline view and the components of the grading system presented here are a suitable basis for assessing osteoarthritis at this site. The view enables the determination of a wider range of abnormality than that provided by the lateral patellofemoral view and assessments made using this view generally show better interobserver and intraobserver reproducibility. There are a number of caveats to the conclusions of this study, however.

It is conceivable that the better reproducibility achieved by the skyline view resulted from the emphasis given to it in the training session. All the observers had experience of grading the other views using different methods before the study and their previous exposure might have resulted in bias affecting the performance of the other views. Although this might explain the poorer interobserver agreement, we do not feel that this is the explanation for the fact that in the intraobserver comparison the skyline view still performed well.

Although the elements of the grading system have been used in other studies^{6 12-15} it is unclear how these interrelate. This system does not allow for a single precise definition of osteoarthritis in the manner of the commonly used Kellgren and Lawrence system.⁴ We believe, however, that for the purposes of clinical studies it is necessary to differentiate and describe different aspects of the osteoarthritic process before inferring interrelationships and hierarchical importance.

Although this system describes abnormality in the skyline patellofemoral joint, it is uncertain how this relates to outcome (symptoms, function) in osteoarthritis. This aspect is currently being investigated.

Finally, the view is technically less easy to obtain than the standard lateral view and our preliminary data in a normal subject suggest that positioning may be crucial in reducing variability in the technique. These considerations also apply to the other standard views.¹⁶ Although measurement is technically possible with the skyline view even using a simple apparatus such as a ruler, this technical variability may be a serious consideration in determining the reliability of such measurements in cross sectional and longitudinal studies. It is likely that precise standardisation and knowledge of scaling will be important in determining the accuracy of any measurements made. Furthermore, stressing of the patellofemoral joint may be required if the intrabone distance is adequately to reflect cartilage thickness. Further studies are required on this point.

With respect to cost, such radiographs are cheaper than standard lateral views as only

one exposure is taken. The positioning of the x ray beam, however, is such that irradiation of the pelvis and body is a problem, although with accurate alignment of the radiation beam and good shielding techniques the entry dose of the two techniques is similar (lateral and anteroposterior 190 μ Gy, skyline 290 μ Gy) and gonadal and breast dosage is minimal.

It is likely that other imaging modalities, particularly magnetic resonance imaging, will be more sensitive and possibly more reproducible than plain radiography.^{13 14} Until such methods become more widely available and rapid, plain radiography is still likely to be the workhorse of clinical studies. It is unlikely that such methods will ever be applicable to epidemiological studies.

Skyline views allow reliable and reproducible evaluation of osteoarthritis in the patellofemoral joint and have many advantages over lateral radiographs. Although further validation is required they should be considered in all surveys of osteoarthritis of the knee.

We are grateful to Mr Rodgers for details of the radiation exposure of the various techniques used by this department. AJ and MD are grateful to the Arthritis and Rheumatism Council for financial support. Dr P Brennan provided the computer program for calculation of the κ coefficients.

- Ahlback S. Osteoarthritis of the knee: a radiographic investigation. *Acta Radiol Suppl (Stockh)* 1968; 277 (suppl 1): 7-72.
- Barrett J P, Rashkoff E, Sirna E C, Wilson A. Correlation of roentgenographic patterns and clinical manifestations of symptomatic idiopathic osteoarthritis of the knee. *Clin Orthop Rel Res* 1988; 253: 179-83.
- McAlindon T E, Snow S, Cooper C, Dieppe P A. Radiographic patterns of osteoarthritis of the knee joint in the community: the importance of the patellofemoral joint. *Ann Rheum Dis* 1992; 51: 844-9.
- Kellgren J H, Lawrence J S. Radiological assessment of osteoarthrosis. *Ann Rheum Dis* 1957; 16: 494-502.
- Cooper C, Cushnaghan J, Kirwan J R, et al. Radiographic assessment of the knee joint in osteoarthritis. *Ann Rheum Dis* 1992; 51: 80-2.
- Thomas R H, Resnick D, Alazraki N P, Danial D, Greenfield R. Compartmental evaluation of osteoarthritis of the knee. *Radiology* 1975; 116: 585-94.
- Clark K C. *Positioning in radiography*. 8th ed. London: Heinemann, 1967: 114.
- Spector T D, Cooper C, Cushnaghan J, Hart D J, Dieppe P A. *A radiographic atlas of knee osteoarthritis*. London: Springer-Verlag, 1992.
- Cohen J. A coefficient of agreement for nominal scales. *Educational and Psychological Measurement* 1960; 20: 37-46.
- Cohen J. Weighted kappa. *Psychol Bull* 1968; 70: 213-20.
- Brennan P. *Kappa statistic program*. Manchester: ARC Epidemiology Research Unit.
- Altman R D, Fries J F, Bloch D A, et al. Radiographic assessment of progression in osteoarthritis. *Arthritis Rheum* 1987; 30: 1214-25.
- McAlindon T E M, Watt I, McCrae F, Goddard P, Dieppe P A. Magnetic resonance imaging in osteoarthritis of the knee: correlation with radiographic and scintigraphic features. *Ann Rheum Dis* 1990; 50: 14-9.
- Chan W P, Lang P, Stevens M P, et al. Osteoarthritis of the knee: comparison of radiography, CT, and MR imaging to assess extent and severity. *Am J Roentgenol* 1991; 157: 799-806.
- Ledingham J, Regan M, Jones A, Doherty M. Radiographic patterns and associations of knee osteoarthritis in patients referred to hospital. *Ann Rheum Dis* 1993; 52: 520-6.
- Messieh S S, Fowler P J, Munro T. Anteroposterior radiographs of the osteoarthritic knee. *J Bone Joint Surg [Br]* 1990; 72: 639-40.