

CASE REPORTS

Sparing effect of hemiplegia on scleroderma

Sanjay Sethi, Winston Sequeira

Abstract

The paretic limb is spared in patients who develop rheumatic diseases after a hemiplegic stroke. This has been described previously in rheumatoid arthritis, gout, and osteoarthritis. A similar presentation in a case of scleroderma is described in this report. Scleroderma skin changes are absent in the completely paretic limb and were markedly reduced in the weak left leg. Inflammation may be modified either by neuropeptides or by an anatomical neurological lesion and this may explain the phenomenon.

An unusual case of scleroderma is presented here in a woman who had had an antecedent stroke with scleroderma sparing the paretic left side.

Case report

A 56 year old black woman was first examined in the rheumatology clinic in 1986 for changes in skin colour and a 'petechial rash'. She had also complained of cold induced, triple colour changes classical for Raynaud's phenomenon in her right hand without similar changes occurring in her left hand. The patient noticed dyspnoea on moderate exertion and mild dysphagia with solid food.

She had had a stroke in May 1967 as a consequence of a ruptured right posterior communicating artery aneurysm, which was subsequently clipped. She continued to have residual paralysis of her left hand and weakness in her left leg and had received little or no physical treatment.

On physical examination the patient had areas of hypopigmentation and hyperpigmentation with prominent telangiectasia on her face and anterior chest wall. She had generalised sclerodermatous skin changes that spared the left spastic and paretic hand (figure), and the weak left leg was minimally affected. Passive motion of the arm and hand was markedly limited because of severe contractures. She had 3/5 motor power in her left leg and foot; her deep tendon reflexes were exaggerated in the left hand and foot. There was no sensory deficit and the other results of her systemic examination were normal.

Her laboratory tests including a complete blood count, serum electrolytes, liver profile, and urine analysis were normal. Immunological studies were as follows: antinuclear antibody titre 1/1280 with a nucleolar pattern; rheumatoid factor <60 units; anti-Scl-70 positive; anti-

bodies to SS-A, SS-B, Sm, RNP, and dsDNA negative; erythrocyte sedimentation rate (Wintrobe) 40 mm/h; C3 115 mg/l (normal range 83-170); C4 38 mg/l (normal range 20-50). The chest radiograph was normal with a restrictive pattern shown on pulmonary function tests.

The patient was diagnosed as having scleroderma, though at no stage in her disease was her left arm affected. Treatment was started with penicillamine.

Discussion

Scleroderma is an autoimmune disease characterised by diffuse symmetrical involvement of the skin with the classical changes of hidebound skin extending proximal to the metacarpophalangeal joints.¹ We believe that this is an unusual case of scleroderma, which spared the side affected by the stroke. The degree to which skin is affected is inversely proportional to the degree of weakness. The paretic left arm is the least affected, skin changes are mild in the weak left leg with diffuse involvement of the normal limbs. This sparing of the paretic limb has not been described in scleroderma, though it has been noted in rheumatoid arthritis.^{2,3} Inflammation, erosions, and nodules are uncommon on the affected side, and this sparing of the paretic limb occurs only if the stroke precedes the arthritis.^{2,3} Acute attacks of gout⁴ and Heberden's nodes⁵ are also less prevalent in paretic limbs. Why this happens is not clear but certainly poses a number of questions. Why are some diseases bilateral and symmetrical? Does the nervous system have a role in causing or modifying these diseases? Might injury to the nervous system prevent the development of bilateral disease? Might this be a clue to the pathogenesis of scleroderma and other rheumatic diseases?

Decreased use of the paretic limb or a modification in its blood flow might be responsible for the sparing effect described above. There is no evidence that resting a neurologically intact limb prevents progression of rheumatoid arthritis, however. Decreased skin blood flow, as measured by phenolsulphonphthalein clearance time, has been noted in paretic limbs,⁶ but its pathophysiological significance is uncertain.

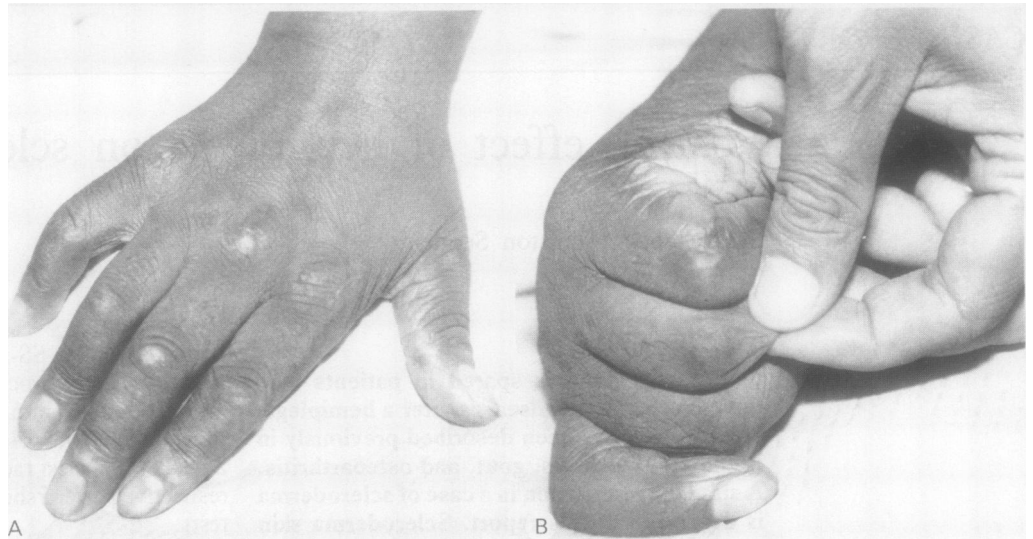
Modification of inflammation by neurological lesions has been shown experimentally. Section of the sciatic nerve before induction of adjuvant arthritis in rats causes sparing of the paretic limb.⁷ The flare component of the triple response of Lewis is diminished significantly after neurological lesions (both central and peripheral).⁸

Department of Medicine,
Cook County Hospital,
Chicago, Illinois, USA
S Sethi

Division of
Rheumatology,
Cook County Hospital,
Chicago, Illinois, USA
W Sequeira

Correspondence to:
Dr Winston Sequeira,
1900 West Polk Street,
Chicago, Illinois 60612, USA

Accepted for publication
26 January 1990



(A) Right hand showing sclerodermatous skin changes; (B) paretic left hand with normal appearing skin.

More recently, the release of substance P and other neuropeptides from the terminal ends of sensory nerves has been shown to have an important role in mediating inflammatory responses.⁹ These observations suggest that interruption of neural pathways may modify the inflammatory and vascular responses seen in the affected limb: both considered to be key factors in the pathogenesis of scleroderma.¹⁰ This may account for the unusual distribution of sclerodermatous changes seen in our patient.

Recent reports have considered the possibility of the autonomic nervous system playing a part in the pathogenesis of scleroderma.¹¹ Autonomic dysfunction induced by the stroke may have had an ameliorating effect in our patient.¹²

1 Subcommittee for scleroderma criteria of the American Rheumatism Association diagnostic and therapeutic criteria committee. Preliminary criteria for the classification of systemic sclerosis (scleroderma). *Arthritis Rheum* 1980; 23: 581-90.

- 2 Thomason M, Bywater E G C. Unilateral rheumatoid arthritis following hemiplegia. *Ann Rheum Dis* 1962; 21: 370-7.
- 3 Glick E N. Asymmetrical rheumatoid arthritis following polio. *Br Med J* 1967; ii: 26-9.
- 4 Glyn J J, Clayton M L. Sparing effect of hemiplegia on tophaceous gout. *Ann Rheum Dis* 1976; 35: 534-5.
- 5 Winter S. Unilateral Heberden nodes in a case of hemiplegia. *NY State J Med* 1952; 52: 349-50.
- 6 Mizushima Y, Yamaura M. Arthropathy and inflammatory reaction in hemiplegic patients. *Acta Rheumatologica Scandinavica* 1969; 15: 297-304.
- 7 Courtright L J, Kuzell W C. Sparing effect of neurological deficit and trauma on the course of adjuvant arthritis in rats. *Ann Rheum Dis* 1965; 24: 360-6.
- 8 Cooper I S. A neurological evaluation of the cutaneous histamine reaction. *J Clin Invest* 1950; 29: 465-9.
- 9 Levine J D, Collier D H, Bassaum A I, Maskowitz A, Helms L A. Hypothesis: the nervous system may contribute to the pathophysiology in rheumatoid arthritis. *J Rheumatol* 1985; 12: 406-11.
- 10 Sternberg E M. Pathogenesis of scleroderma: the inter-relationship of the immune and vascular hypotheses. *Survey of Immunological Research* 1985; 4: 69-80.
- 11 Klimiuk P S, Taylor L, Baker R D, Jayson M I V. Autonomic neuropathy in systemic sclerosis. *Ann Rheum Dis* 1988; 47: 542-5.
- 12 Eto F, Yoshikawa M, Ueda S, Hirai S. Posthemiplegic shoulder-hand syndrome, with special reference to related cerebral localisation. *J Am Geriatr Soc* 1980; 28: 13-17.