

Periarthritis of the shoulder

II. Radiological features

V. WRIGHT AND A. M. M. M. HAQ

From the Rheumatism Research Unit, University Department of Medicine, General Infirmary at Leeds, and Royal Bath Hospital, Harrogate

Wright, V., and Haq, A. M. M. M. (1976). *Annals of the Rheumatic Diseases*, **35**, 220–226. **Periarthritis of the shoulder. II. Radiological features.** A group of 113 women and 73 men with periarthritis of the shoulder have been studied in detail. Electromyography showed 4 patients with neuralgic amyotrophy who had been referred for the shoulder study but were excluded on this basis. Nerve conduction studies showed little difference between the periarthritic group and a control group, apart from some reduction in amplitude and potential, and in women a suggestion of an increased latency. Duration of the action potential was equal. 6 patients had an undoubtedly long latency compatible with median nerve compression.

Degenerative changes were found in the glenohumeral joints in 6–9%. Degenerative changes were found at the acromioclavicular joints in 31% of the men and 44% of the women. Calcification was found around 11 of the shoulder joints. There was frequently a previous history of 'rheumatism' before the episode of periarthritis. In one-third of the women 'nonspecific rheumatism' had occurred. Cervicobrachial pain and a previous episode of shoulder pain had occurred more often in the women.

Arthrography was performed in 7 patients and there was a reduction in volume of material that could be injected in only one patient. There was obliteration of the axillary fold in that patient, and a torn capsule in a patient who had previously been manipulated. Lateral cervical spine x-rays were compared with films from an epidemiological survey. The disc space/vertebral body height ratio was taken, overcoming the magnification effects shown by technical alterations in the method of taking films. Good intra- and interobserver correlation was found for this ratio, but not for the width of the canal. There was no difference in the disc/body ratio between the periarthritic and control group in the upper cervical region. In the C5/6 and C6/7 intervertebral discs there was evidence of more disc degeneration in the periarthritic group. The differences from the control group were not great because of the high incidence of disc space narrowing and osteophytosis after the age of 45 years in the general population.

In the previous paper a general survey of a group of patients with periarthritis of the shoulder was made, and particular attention paid to psychological factors. Another aspect of the disease which might be quantified was the radiological appearances. For instance, cervical disc degeneration has been cited as an aetiological factor (Oppenheimer, 1938; Kamieth, 1965). The present study has been undertaken to look at this aspect in particular, against the background of clinical and other radiological examinations. Certain electrodiagnostic tests were also undertaken.

Materials and methods

The 186 patients described in the previous paper had an x-ray of the shoulder joint and the films were read for (1) the presence of calcification, (2) degenerative changes in the glenohumeral joint, and (3) changes in the acromioclavicular joint. Arthrography was performed on the shoulder in 7 patients.

Radiographs of the cervical spine were taken in the posteroanterior and lateral views. Control films were obtained from the population survey (kindly supplied by the Arthritis and Rheumatism Council Epidemiological Unit in Manchester). On these films the following measurements were made. (1) Depth of the vertebral body.

(2) Depth of the intervertebral space. (3) Posterior alignment. (4) Projection of osteophytes anteriorly. (5) Projection of osteophytes posteriorly.

Cervical spine x-rays of 145 patients were available for reading. A comparable number of x-ray films of the cervical spine were read from subjects in the age group 45–74 years from a field survey done at Leigh (Lancashire) and Wensleydale (Yorkshire).

To ascertain whether absolute figures of vertebral body and disc space size were meaningful on x-ray, experiments were done to assess the effect of varying the distances involved in taking such radiographs. X-rays were taken of the cervical spine of a skeleton with sponge rubber pads the size of the intervertebral discs in place. The effect of magnification was observed by varying the distance between the skeleton and the x-ray tube and the distance between the skeleton and the x-ray plates. Table I shows an undoubted magnification effect which in the grossest example was 33%.

To test the reproducibility of readings 20 random films were scrutinized from the general population under study since these were the most difficult to read. Both authors read them separately. Agreement on the presence or absence of anterior osteophytes was good, but there was no reliability in reading posterior osteophytes. No reliable readings of posterior alignment could be obtained either by measuring the width of the vertebral canal or by observing disturbances in the line of the posterior edges of vertebral bodies.

The depth of each vertebral body of the third cervical vertebra (C3) to the seventh (C7), and each intervertebral disc space from C2/3 to C6/7 was measured by transparent graph paper graduated in mm. The intervertebral disc space was expressed relative to the depth of the vertebral body below, as described by Brain and Wilkinson in 1967.

$$\text{Relative disc space} = \frac{\text{depth of disc}}{\text{depth of body below}} \times 100.$$

Table I Magnification effect on depth of vertebral bodies by varying the distance of the x-ray source from the film, and of the film from the cervical spine

Source from films	3 feet		6 feet	
	8"	Contact	8"	Contact
C3 (depth in mm)	9	7	8	7
C4 "	7	6	6.5	6
C5 "	8	7	7	7
C6 "	7.5	6	8	8
C7 "	8	7	8.5	7
D1 "	9	8	8	7

Table II Mean median nerve sensory latencies in normal and periarthritic (PA) subjects

Stimulating site	Median nerve sensory latency in ms				
	Groups	No.	Mean	SD	t-test
Fingers to wrist	Normal	26	2.15	±0.24	P < 0.3 P < 0.10 > 0.05 P > 0.2 P < 0.05 < 0.02
	Male PA	54	2.02	±0.30	
	Female PA	85	1.92	±0.51	

Calculating the relative intervertebral space depths overcame magnification effects and the results of our films could be compared with the epidemiological films taken with a very different technique and under much more difficult conditions. Comparisons were made between the periarthritic groups as a whole and the control films, and then between periarthritic patients in the age group 45–74 years and the control films (which were drawn from a similar age range.) Osteophytes were marked as being present or absent.

Electromyography of the shoulder girdle muscles was done to exclude any neurological condition and in this way 4 patients were found with neuralgic amyotrophy (Parsonage and Turner, 1948). They were not included in this study. Nerve conduction studies were done in 139 patients and compared with normal subjects tested in the same way (Kemble, 1966). The latency, amplitude, and duration of action potentials were recorded.

Results

NERVE CONDUCTION STUDIES

Median sensory nerve conduction studies were carried out in 139 patients. Tables II–IV show the distribution of latency, amplitude, and duration of action potentials in both sexes, in patients with periarthritis of the shoulder compared with normal subjects (Kemble, 1966). Kemble did not separate his normal subjects by sex and this casts doubt on the significance of the difference between the latency in women with periarthritis and the control group. Although there was a reduction in action potential amplitude in periarthritic patients, this is of no great significance in indicating median nerve compression—it is the latency which is important. The duration of

Table III *Action potential amplitudes in normals and in periartritic (PA) subjects*

Site of stimulation	Median nerve action potential amplitudes (volts) (sensory)			
	Groups	No.	Mean	SD
Fingers to wrist	Normal	26	92.6	33.9
	Male PA	54	54.06	20.87
	Female PA	85	56.85	24.7

Table IV *Median nerve sensory action potential duration in normals and in periartritic (PA) subjects*

Site of stimulation	Median nerve sensory action potential duration (ms)			
	Groups	No.	Mean	SD
Fingers to wrists	Normal	26	1.09	0.16
	Male PA	54	1.08	0.23
	Female PA	85	1.02	0.34

the potential was similar in all groups. There were 6 patients with median nerve compression confirmed by a long latency; 2 were men and 4 were women.

RADIOLOGY

Shoulder joints

Normal glenohumeral joints were recorded in 152 on the right side and 153 on the left side in both sexes. Slight degenerative changes were noticed in 4 on the right side and 6 on the left side of the males; in 6 on the right side and 4 on the left side in female patients. Moderate changes were noticed in 2 on the right side, in one on the left side in males; and one on the right side and 2 on the left side in females. No gross changes were noticed on either side in both sexes. The frequency of those changes was similar in both sexes.

Acromioclavicular joints

Normal appearances were observed in 98 on the right side and 100 on the left side of all patients. Some changes were common, being present in 31 to 44% of the joints in each sex.

Calcification

Slight to moderate calcification around the shoulder joint was noted on four occasions on the right side in men and on two occasions in females. Calcification in the left shoulder was found in one male and 4 female patients.

Arthrography of the shoulder joint

Arthrography was done on seven occasions. It was normal in 5 patients. One patient showed obliteration of the axillary fold. He was a man aged 72 years suffering from severe periartthritis with wasting of

the shoulder girdle muscles and having restricted movements of the joint. Another patient was found to have dye outside the joint capsule; he was a man whose shoulder joint previously had been manipulated.

Cervical spine

The age and sex distribution of the 145 patients with cervical spine radiographs available for reading is shown in Fig. 1.

Disc space/body ratio

The measurements of relative disc spaces are summarized in Tables V–VII. There were few differences between the periartritic and the control groups and this is illustrated for the lower cervical region where most marked changes would be expected. The results have been compared in the tables with figures obtained for a normal group by Brain and Wilkinson

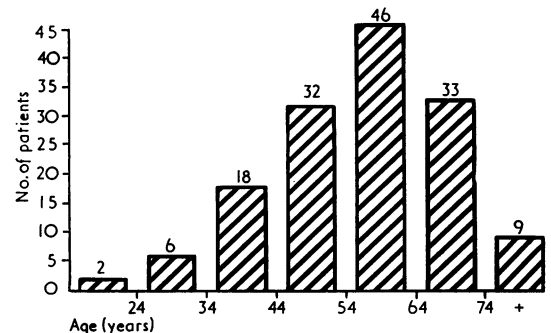


FIG. 1 Age and sex distribution of patients with periartthritis of the shoulder whose cervical spine was x-rayed

Table V *Disc/body ratio C2/3 and C3/4*

Ratio (%)	Disc/body ratio C2/3				Disc/body ratio C3/4			
	Male		Female		Male		Female	
	PA	Con	PA	Con	PA	Con	PA	Con
0-15	0	0	0	1	0	0.5	0	0.5
16-25	2	3	0	1	2	3	1	3
26-35	12	15	6	16	8	11	5	14
36-45	50	41	43	38	39	36	34	27
46-55	26	33	44	28	34	33	52	33
56-65	7	6	17	13	12	10	6	17
66+	5	2	0	3	3	4	2	5
Mean	44.2	42.9	46.5	44	45.5	44.9	46.3	45.9
SD	9.3	9.5	8.0	10.8	9.6	10.4	7.8	11.6
Normal (%) (Brain and Wilkinson, 1967)		42.9		47.9		46.5		46.7

PA = periarthritic subjects; Con = controls.

Table VI *Disc/body ratio in C4/5 and C5/6*

Ratio (%)	Disc/body ratio C4/5				Disc/body ratio C5/6			
	Male		Female		Male		Female	
	PA	Con	PA	Con	PA	Con	PA	Con
0-15	2	0	0	0.5	0	1	2	0
16-25	0	7	3	6	7	10	12	9
26-35	12	13	13	23	26	20	17	20
36-45	35	33	22	33	14	23	18	32
46-55	31	32	55	31	40	27	44	21
56-65	17	8	4	15	7	13	3	15
66+	5	6	2	2	4	5	4	3
Mean	45.9	43.8	45	42.7	42.5	42.4	41.4	42.1
SD	11.5	11.7	9.3	11.6	12.2	13.6	13.1	12.5
Normal (%) (Brain and Wilkinson, 1967)		46.7		45.7		45.3		49.2

(1967). It will be seen that in the upper cervical region there was no difference. In C5/6 and C6/7, however, the discs were relatively narrower in the periarthritic group than in the group of Brain and Wilkinson. They were not narrower than the controls in this study, but these latter came from an older age group (45-74 years).

Anterior osteophytes

The distribution of anterior osteophytes was recorded as superior and inferior in each intervertebral space. Patients between 45 and 74 years were matched with control films and the frequency was compared at each intervertebral space (Figs. 2-5). It is apparent that in the upper cervical region there is little difference, but

Table VII Disc/body ratio in C6/7

Ratio (%)	Disc/body ratio C6/7			
	Male		Female	
	PA	Con	PA	Con
0-15	2	0	7	18
16-25	10	7	19	27
26-35	33	27	33	19
36-45	18	30	36	21
46-55	24	28	6	10
56-65	3	5	—	7
66+	6	2	0	—
Mean	39.5	40.3	31.3	29.5
SD	12.9	10.5	10.6	15.4
Normal (%) (Brain and Wilkinson, 1967)		44.2		47.4

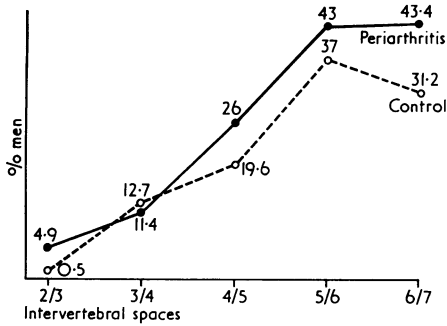


FIG. 2 Frequency of superior anterior osteophytes in men 45-74 years of age with periarthritis of the shoulder compared with controls at different levels

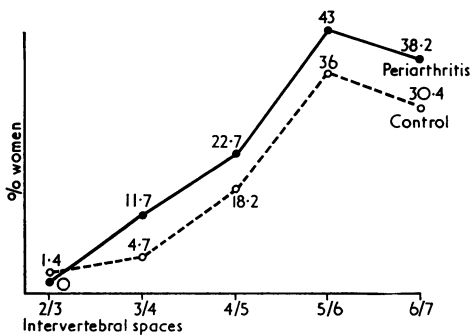


FIG. 3 Frequency of superior anterior osteophytes in women 45-74 years of age with periarthritis of the shoulder compared with controls at different levels

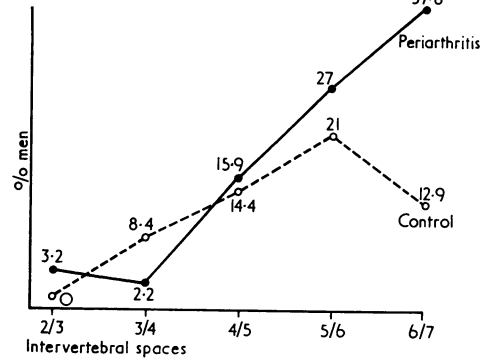


FIG. 4 Frequency of inferior anterior osteophytes in men 45-74 years of age with periarthritis of the shoulder compared with controls at different levels

in the lower two disc spaces osteophytes occurred more commonly in the patients with periarthritis of the shoulder.

Discussion

The present study was concerned mainly with radiological aspects of periarthritis of the shoulder, and particularly with investigating the hypothesis that the condition is associated with cervical disc degeneration as proposed by Oppenheimer (1938) and Kamieth (1965).

Most authors would agree with Steinbrocker (1966) that no diagnostic x-ray changes occur at any

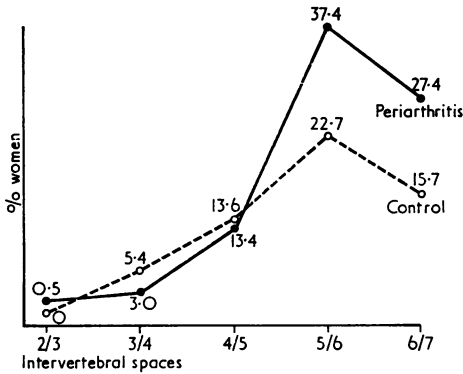


FIG. 5 Frequency of inferior anterior osteophytes in women 45-74 years of age with periarthritis of the shoulder compared with controls at different levels

time, except demineralization after the first 2 or 3 months at the head and upper portion of the humerus, increasing with continued limitation of motion (Rosen and Grahame, 1957; Carrière and Kérambrum, 1967). This is usually spotty in appearance, giving the characteristic appearance of disuse osteoporosis well described by Mumford (1938); the cortex is fairly well preserved—the medullary portion giving a mottled and moth-eaten shadow and the longitudinal trabeculae being less well defined. In this series degenerative changes were found in a small number of shoulders, but such changes were found commonly at the acromioclavicular joint (no control data are available). On the other hand, Kernwein (1965) cited six radiographically detectable changes which occurred with such frequency as to be significant. These were (1) cysts of the tuberosities of the humerus; (2) erosion of the tuberosities of the humerus; (3) degenerative arthritis of the acromioclavicular joint; (4) spur formation of the periphery of the glenoid; (5) spur formation of the inferior surface of the humerus; (6) calcification of the rotator cuff.

A small series of arthrographic investigations differed somewhat from the larger series of Kernwein, Roseberg, and Sneed (1957) and Reeves (1966) who showed reduced volume. In our series one patient showed obliteration of the axillary fold; the other joints received a normal volume of contrast medium. Nevasier (1962) found in two manipulated shoulders evidence of a ruptured capsule, which was seen in one patient in this group. In Nevasier's cases arthrography 2 months later showed the joint

had returned to a normal appearance with healing of the capsular defect. This did not occur in our patient.

Kamieth (1965) noted that the peak incidence of periarthritis of the shoulder occurred after the 45th year and that this coincided with the peak incidence of cervical disc degeneration. Although relative disc space narrowing in the lower cervical intervertebral disc regions occurred more commonly in patients with periarthritis of the shoulder than in the normals reported by Brain and Wilkinson (1967), there was no significant difference between the periarthritic patients and the age-matched subjects from the general population. There was some difference in the frequency of osteophytosis at the C5/6 and C6/7 levels. The data emphasized the difficulty of ascribing great significance to cervical disc changes seen radiologically in patients after the age of 45 years, such is their prevalence (Friedenberg and others, 1960; Tapiovaara and Heinivaara, 1954; Lawrence, 1969). The radiological findings, however, give little support to the view that cervical disc degeneration is of aetiological significance in periarthritis of the shoulder.

The fairly high incidence of 'nonspecific rheumatism' in the previous medical history of these patients is of interest (Wright and Haq, 1976). We have the impression that cervical disc degeneration, periarthritis of the shoulder, epicondylitis, and median nerve compression may coexist more frequently than by chance, sometimes with other conditions such as de Quervain's tenosynovitis. Among the women there was increased latency of median nerve conduction compared with a small control group (Kemble, 1966). It is difficult to draw firm conclusions in view of the absence of age and sex stratification of this control group, but 6 periarthritic patients had abnormal latencies compatible with median nerve compression. The inter-relationship of the conditions is being studied further (Murray-Leslie, Longton, and Wright, 1975).

We are grateful to Dr. D. Taverner for making electrodiagnostic facilities available, to Dr. S. Mattingley for discussion of the whole problem, to Dr. P. N. P. Wood for allowing us to read the films of the cervical spine from epidemiological studies and for much helpful discussion in the reading of these films. One of us (A.M.M.M.H.) is most grateful to the World Health Organization for financial assistance which enabled him to return to Leeds to help collate the material and to the Government of the People's Republic of Bangladesh for allowing him to leave the country on deputation.

References

- BRAIN, W. R., AND WILKINSON, M. (1967) In 'Cervical Spondylosis'. Heinemann, London
 CARRIÈRE, J., AND KÉRAMBUM, G. (1967) *Rev. Tuberc.*, 31, 267 (Periarthrite scapulo-humérale et syndrome épaule-main en milieu sanatorial (à propos de 53 observations))

- FRIEDENBERG, Z. B., BRODER, H. A., EDEIKEN, J. E., AND SPENCER, H. N. (1960) *J. Amer. med. Ass.*, **174**, 375 (Degenerative disk disease of cervical spine)
- KAMIETH, H. (1965) *Z. Orthop.*, **100**, 162 (Radiography of the cervical spine in shoulder periarthritis)
- KEMBLE, F. (1966) 'Sensory conduction in the adult median nerve'. M.D. thesis, University of Manchester
- KERNWEIN, G. A. (1965) *J. Amer. med. Ass.*, **194**, 179 (Roentgenographic diagnosis of shoulder dysfunction)
- , ROSEBERG, B., AND SNEED, W. R. (1957) *J. Bone Jt Surg.*, **39A**, 1267 (Arthrographic studies of the shoulder joint)
- LAWRENCE, J. S. (1969) In 'Textbook of the Rheumatic Diseases', ed. W. S. C. Copeman, 4th ed. Livingstone, Edinburgh
- MUMFORD, E. B. (1938) *J. Bone Jt Surg.*, **20**, 949 (Roentgenotherapy in acute osteoporosis)
- MURRAY-LESLIE, C., LONGTON, E. B., AND WRIGHT, V. (1975) *Scand. J. Rheum.*, **Suppl. 8**, 37 (Relationship between idiopathic carpal tunnel syndrome and humeral epicondylitis)
- NEVASIER, J. A. (1962) *J. Bone Jt Surg.*, **44A**, 1321 (Arthrography of the shoulder joint)
- OPPENHEIMER, A. (1938) *Surg. Gynec. Obstet.*, **67**, 446 (The swollen atrophic hand)
- PARSONAGE, M. J., AND TURNER, J. W. A. (1948) *Lancet*, **1**, 973 (Neuralgic amyotrophy)
- REEVES, B. (1966) *Proc. roy. Soc. Med.*, **59**, 827 (Arthrographic changes in frozen and post-traumatic stiff shoulders)
- ROSEN, P. S., AND GRAHAM, W. (1957) *Canad. med. Ass. J.*, **77**, 86 (The shoulder-hand syndrome)
- STEINBROCKER, O. (1966) In 'Arthritis and Allied Disorders', ed. J. L. Hollander, p. 1247. Kimpton, London
- TAPIOVAARA, J., AND HEINIVAARA, O. (1954) *Ann. Chir. Gynaec. Fenn.*, **43**, Suppl. 5, 436 (Correlation of cervico-brachialgies and roentgenological findings in cervical spine)
- WRIGHT, V., AND HAQ, A. M. M. M. (1976) *Ann. rheum. Dis.*, **35**, 213. (Periarthritis of the shoulder. I. Aetiological considerations with particular reference to personality factors)