

Response to: 'Correspondence on 'Bowman's capsule rupture on renal biopsy improves the outcome prediction of ANCA-associated glomerulonephritis classifications'' by Hakroush and Tampe

The moral of the story is that the implementation of the Bowman's capsule rupture (BCR) in prognostic classification systems is still lacking.¹ BCR is a common final step of the crescent formation² for many different glomerular diseases characterised by extracapillary hypercellularity, as in anti-glomerular basement membrane (GBM) disease,³ lupus nephritis, IgA nephropathy and glomerulonephritis in the setting of antineutrophil cytoplasmic antibodies (ANCA)-associated vasculitis (AAV). Although the consequences of BCR in terms of nephron loss and renal scarring have already been investigated⁴ and its putative prognostic role in AAV have been proposed in our previous study,⁵ its actual frequency in pauci-immune crescentic glomerulonephritis (as in other forms) remains elusive. In our experience, the incidence of BCR in AAV cases is even higher than the one reported by Hakroush *et al.* In a retrospective evaluation of our archives updated to January 2021, on a total of 68 renal biopsies diagnosed with ANCA-associated glomerulonephritis, 38 (56%) were characterised by at least a focal rupture of Bowman's capsule. Moreover, considering only those cases with BCR, its incidence on the total number of glomeruli evaluated was 20% (112 out of 573). Since

all these cases were characterised by at least one cellular/fibrocellular (active) crescent, we did not note a different incidence of BCR in the subset of overt crescentic cases. Interestingly, 5 out of 68 (7%) of all the biopsies analysed showed BCR involving at least 50% of glomeruli (figure 1). Evaluation in larger cohorts and with additional endpoints will definitely shed light on the putative role of this alteration in the prognosis of patients with AAV, allowing its eventual implementation even in other glomerulonephritis classifications.

Vincenzo L'Imperio¹,² Gisella Vischini,^{2,3} Manuel Ferraro,^{2,3} Fabio Pagni¹

¹Department of Medicine and Surgery, Pathology, San Gerardo Hospital, University of Milano-Bicocca, Monza, Italy

²UOC Nefrologia, Fondazione Policlinico Universitario A Gemelli IRCCS, Roma, Italy

³Università Cattolica del Sacro Cuore, Roma, Italy

Correspondence to Dr Vincenzo L'Imperio, Pathology, Università degli Studi di Milano-Bicocca, Milano, Italy; vincenzo.limperio@gmail.com

Handling editor Josef S Smolen

Twitter Vincenzo L'Imperio @VlImperioMD

Contributors VL ideated the study. VL and GV performed the histological assessment. MF performed the statistical analysis. FP supervised and revised the final draft of the manuscript.

Funding The authors have not declared a specific grant for this research from any funding agency in the public, commercial or not-for-profit sectors.

Patient consent for publication Not required.

Provenance and peer review Commissioned; internally peer reviewed.

© Author(s) (or their employer(s)) 2023. No commercial re-use. See rights and permissions. Published by BMJ.

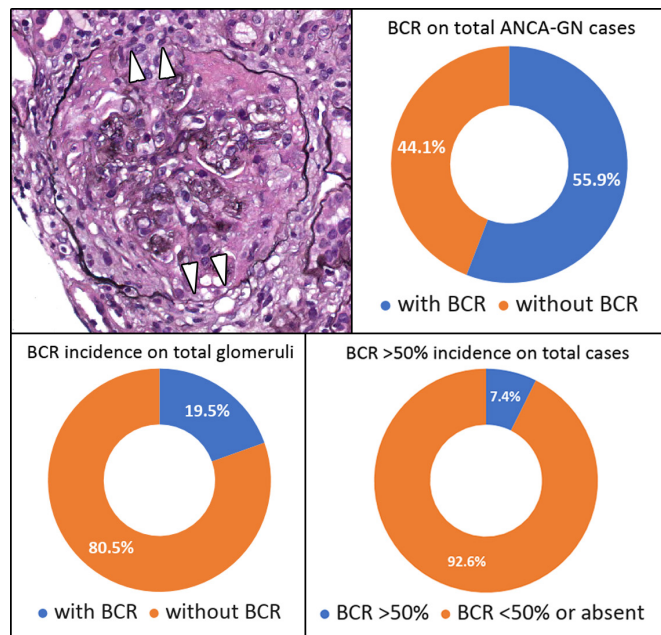
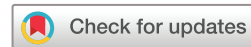

Figure 1 The distribution of BCR in our case series. ANCA-GN, ANCA-associated glomerulonephritis; BCR, Bowman's capsule rupture.

To cite L'Imperio V, Vischini G, Ferraro M, *et al.* *Ann Rheum Dis* 2023;**82**:e126.

Received 27 January 2021

Accepted 27 January 2021

Published Online First 5 February 2021



► <http://dx.doi.org/10.1136/annrheumdis-2021-219970>

Ann Rheum Dis 2023;**82**:e126. doi:10.1136/annrheumdis-2021-219988

ORCID iD

Vincenzo L'Imperio <http://orcid.org/0000-0002-9284-2998>

REFERENCES

- Hakroush S, Tampe B. Correspondence on "Bowman's capsule rupture on renal biopsy improves the outcome prediction of ANCA-associated glomerulonephritis classifications". *Ann Rheum Dis* 2023;**82**:e125.
- Anguiano L, Kain R, Anders H-J. The glomerular crescent: triggers, evolution, resolution, and implications for therapy. *Curr Opin Nephrol Hypertens* 2020;**29**:302–9.
- Morley AR. Peri-hilar rupture of Bowman's capsule in crescentic glomerulonephritis. *APMIS Suppl* 1988;**4**:74–81.
- Chen A, Lee K, D'Agati VD, *et al.* Bowman's capsule provides a protective niche for podocytes from cytotoxic CD8+ T cells. *J Clin Invest* 2018;**128**:3413–24.
- L'Imperio V, Vischini G, Pagni F, *et al.* Bowman's capsule rupture on renal biopsy improves the outcome prediction of ANCA-associated glomerulonephritis classifications. *Ann Rheum Dis* 2022;**81**:e95.