

EULAR recommendations for the use of imaging of the joints in the clinical management of rheumatoid arthritis

Alexandra N Colebatch,^{1,2} Christopher John Edwards,¹ Mikkel Østergaard,³ Désirée van der Heijde,⁴ Peter V Balint,⁵ Maria-Antonietta D'Agostino,⁶ Kristina Forslind,^{7,8} Walter Grassi,⁹ Espen A Haavardsholm,¹⁰ Glenn Haugeberg,¹¹ Anne-Grethe Jurik,¹² Robert BM Landewé,¹³ Esperanza Naredo,¹⁴ Philip J O'Connor,¹⁵ Ben Ostendorf,¹⁶ Kristina Potočki,¹⁷ Wolfgang A Schmidt,¹⁸ Josef S Smolen,¹⁹ Sekib Sokolovic,²⁰ Iain Watt,⁴ Philip G Conaghan²¹

► Additional material is published online only. To view please visit the journal online (<http://dx.doi.org/10.1136/annrheumdis-2012-203158>).

For numbered affiliations see end of article.

Correspondence to

Professor Philip G Conaghan, Division of Musculoskeletal Disease, Section of Musculoskeletal Disease, University of Leeds & NIHR Leeds Musculoskeletal Biomedical Research Unit, 2nd Floor Chapel Allerton Hospital, Chapeltown Road, Leeds LS7 4SA, UK; PConaghan@leeds.ac.uk

Accepted 24 February 2013
Published Online First
21 March 2013

ABSTRACT

Objective To develop evidence-based recommendations on the use of imaging of the joints in the clinical management of rheumatoid arthritis (RA).

Methods The task force comprised an expert group of rheumatologists, radiologists, methodologists and experienced rheumatology practitioners from 13 countries. Thirteen key questions on the role of imaging in RA were generated using a process of discussion and consensus. Imaging modalities included were conventional radiography, ultrasound, MRI, CT, dual-emission x-ray absorptiometry, digital x-ray radiogrammetry, scintigraphy and positron emission tomography. Research evidence was searched systematically for each question using MEDLINE, EMBASE and Cochrane CENTRAL. The experts used the evidence obtained from the relevant studies to develop a set of 10 recommendations. The strength of recommendation was assessed using a visual analogue scale.

Results A total of 6888 references was identified from the search process, from which 199 studies were included in the systematic review. Ten recommendations were produced encompassing the role of imaging in making a diagnosis of RA, detecting inflammation and damage, predicting outcome and response to treatment, monitoring disease activity, progression and remission. The strength of recommendation for each proposition varied according to both the research evidence and expert opinion.

Conclusions Ten key recommendations for the role of imaging in the management of RA were developed using research-based evidence and expert opinion.

INTRODUCTION

Structural damage in rheumatoid arthritis (RA) can occur early in the disease. Prompt treatment has been shown to reduce inflammation thereby limiting structural damage.^{1 2} Although conventional radiography (CR) has been considered the gold standard for imaging in RA, its sensitivity for structural damage in RA diagnosis is low, and disease activity cannot be assessed.³ Significant advances have been made within the field of imaging in rheumatic diseases over the past decade.⁴

A European League Against Rheumatism (EULAR) task force was therefore convened to develop evidence-based recommendations on the use of imaging of the joints in the clinical management of RA.

METHODS

An expert group of rheumatologists, radiologists, methodologists and experienced rheumatology practitioners (19 people, representing 13 countries) participated in the study. The objectives were to formulate key clinical questions relating to the role of imaging in RA, to identify and critically appraise the available evidence, and to generate recommendations based on both evidence and expert opinion.

At the initial task force meeting, members contributed clinically relevant questions related to key aspects of the use of imaging in RA. The research questions were agreed by consensus and 13 final research questions were selected, which encompassed the role of imaging in making a diagnosis of RA, detecting inflammation and damage, predicting outcome and response to treatment, monitoring disease progression, and remission (see supplementary material, S1. Research questions, available online only).

A systematic search of articles was performed and the bibliographies of included papers were hand searched for evidence of other studies for inclusion. Specific medical subject headings and additional keywords were used to identify all relevant studies (see supplementary material, S2. Search strategy, available online only).

Titles and abstracts of all citations identified were screened, and potentially relevant articles were reviewed in full text using predetermined inclusion and exclusion criteria. Studies, published in English, on the use of imaging in adults (≥ 18 years of age) with a clinical diagnosis of RA were included. Imaging modalities included were CR, ultrasound, MRI, CT, dual-emission x-ray absorptiometry (DXA), digital x-ray radiogrammetry (DXR), scintigraphy and positron emission tomography (PET). Study types included randomised controlled trials, systematic reviews,

controlled clinical trials, cohort, case-control and diagnostic studies. Studies were considered for inclusion when they provided information on the role of imaging in making a diagnosis of RA, detecting inflammation and damage, predicting outcome and response to treatment, monitoring disease progression and remission.

Following presentation of the data from the literature review, the experts produced 10 recommendations based on the 13 clinical questions with final agreement by a process of discussion and consensus. The experts scored the perceived strength of recommendation (SOR) for each proposition using a 0–10 visual analogue scale (VAS; 0=not recommended at all, 10=fully recommended). Scores reflected both research evidence and clinical expertise.⁵

Evidence was categorised according to study design using a hierarchy of evidence in descending order according to quality.⁶ Greater emphasis was given to the best available evidence when answering questions, although all data were collected and reviewed.

Recommendations for future research were agreed by consensus following presentation of the literature review.

RESULTS

The search of databases (performed in June 2011) resulted in 6888 records, of which 2567 were duplicates. Of the remaining 4321 articles, 3975 were excluded based on title or abstract, leaving 346 articles for detailed review. All full text articles written in English were retrieved for review; 175 articles were excluded after reviewing the full text leaving 171 articles for

inclusion (see supplementary figure S3, available online only). The hand search identified 28 additional articles for inclusion, resulting in a total of 199 articles for inclusion. Articles that were relevant to more than one research question were included in the review more than once. The number of articles included in each question is shown in supplementary table S4 (available online only).

Ten recommendations were produced, and the final wording of the propositions was adjusted using e-mail exchange and at the closing meeting of the group. The recommendations, SOR (mean VAS and 95% CI) and level of evidence are presented in table 1.⁵ A full reference list for articles included in each recommendation is given in the supplementary material, S5 (available online only).

Recommendations

Making a diagnosis of RA (in patients with at least one joint with definite clinical synovitis):

Recommendation 1: When there is diagnostic doubt, CR, ultrasound or MRI can be used to improve the certainty of a diagnosis of RA above clinical criteria alone.

Strength of recommendation: 9.1 (95% CI 8.6 to 9.6)

Five observational studies described the impact of imaging on confirming a diagnosis of RA when the diagnosis could not be confirmed using conventional methods, two with ultrasound and three with MRI. Three of these studies examined the hand joints (wrist, metacarpophalangeal and proximal interphalangeal joints), but none compared sites.^{7–11} One study showed

Table 1 Recommendations, SOR and level of evidence

Recommendation*	SOR, mean VAS0–10 (95% CI)	Level of evidence
1 When there is diagnostic doubt, CR, ultrasound or MRI can be used to improve the certainty of a diagnosis of RA above clinical criteria alone†	9.1 (8.6 to 9.6)	III
2 The presence of inflammation seen with ultrasound or MRI can be used to predict the progression to clinical RA from undifferentiated inflammatory arthritis	7.9 (6.7 to 9.0)	III
3 Ultrasound and MRI are superior to clinical examination in the detection of joint inflammation; these techniques should be considered for more accurate assessment of inflammation	8.7 (7.8 to 9.7)	III
4 CR of the hands and feet should be used as the initial imaging technique to detect damage. However, ultrasound and/or MRI should be considered if conventional radiographs do not show damage and may be used to detect damage at an earlier time point (especially in early RA)	9.0 (8.4 to 9.6)	IV
5 MRI bone oedema is a strong independent predictor of subsequent radiographic progression in early RA and should be considered for use as a prognostic indicator. Joint inflammation (synovitis) detected by MRI or ultrasound as well as joint damage detected by conventional radiographs, MRI or ultrasound can also be considered for the prediction of further joint damage	8.4 (7.7 to 9.2)	III
6 Inflammation seen on imaging may be more predictive of a therapeutic response than clinical features of disease activity; imaging may be used to predict response to treatment	7.8 (6.7 to 8.8)	III-IV
7 Given the improved detection of inflammation by MRI and ultrasound than by clinical examination, they may be useful in monitoring disease activity	8.3 (7.4 to 9.1)	III
8 The periodic evaluation of joint damage, usually by radiographs of the hands and feet, should be considered. MRI (and possibly ultrasound) is more responsive to change in joint damage and can be used to monitor disease progression	7.8 (6.8 to 8.9)	III
9 Monitoring of functional instability of the cervical spine by lateral radiograph obtained in flexion and neutral should be performed in patients with clinical suspicion of cervical involvement. When the radiograph is positive or specific neurological symptoms and signs are present, MRI should be performed	9.4 (8.9 to 9.8)	III
10 MRI and ultrasound can detect inflammation that predicts subsequent joint damage, even when clinical remission is present and can be used to assess persistent inflammation	8.8 (8.0 to 9.6)	III

*Recommendations are based on data from imaging studies that have mainly focused on the hands (particularly wrists, metacarpophalangeal and proximal interphalangeal joints). There are few data with specific guidance on which joints to image.

†In patients with at least one joint with definite clinical synovitis, which is not better explained by another disease.

Categories of evidence: Ia, evidence for meta-analysis of randomised controlled trials; Ib, evidence from at least one randomised controlled trial; IIa, evidence from at least one controlled study without randomisation; IIb, evidence from at least one other type of quasi-experimental study; III, evidence from non-experimental descriptive studies, such as comparative studies, correlation studies and case-control studies; IV, evidence from expert committee reports or opinions or clinical experience of respected authorities, or both. CR, conventional radiography; RA, rheumatoid arthritis; SOR, strength of recommendation; VAS, visual analogue scale (0–10; 0=not recommended at all, 10=fully recommended).

Recommendation

that ultrasound synovitis improved the certainty of RA diagnosis from 42.0% to 53.2% (p 0.17),⁷ and another described how synovitis seen with ultrasound helped confirm (65.2%) or change the diagnosis (11.1%); ultrasound was superior to clinical examination in 75% of patients.⁸ Compared to clinical classification criteria, the demonstration of MRI synovitis increased the diagnosis of RA,^{9 10} and was more valuable than anti-cyclic citrullinated peptide antibody (ACPA) determination in the absence of rheumatoid factor (RF).¹¹

Recommendation 2: The presence of inflammation seen with ultrasound or MRI can be used to predict the progression to clinical RA from undifferentiated inflammatory arthritis.

Strength of recommendation: 7.9 (95% CI 6.7 to 9.0)

Several studies assessed the prognostic value of imaging in patients with undifferentiated inflammatory arthritis (UIA), mainly using ultrasound or MRI. A recent systematic review identified 11 studies relating to MRI.¹² The presence of bone oedema or both synovitis and erosion on MRI increased the likelihood of developing RA (positive likelihood ratio 4.5 and 4.8, respectively), whereas the absence of MRI synovitis decreased the probability of progression to RA (negative likelihood ratio 0.2). A prediction model including clinical hand arthritis, morning stiffness, positivity for RF and bone oedema on MRI correctly predicted progression to RA in 82% of UIA patients.¹³ MRI flexor tenosynovitis has also been described as a predictor of early RA (sensitivity 0.60, specificity 0.73).¹⁴ Of the three strongest predictors of RA (MRI flexor tenosynovitis, RF and ACPA), ACPA was found to be the strongest predictor (OR 13.8) and flexor tenosynovitis the weakest (OR 5.0), but its additional value in diagnosing RA was significant.

In a longitudinal study ultrasound significantly increased the detection of joint involvement in all joint regions. When combined with the Leiden prediction rule,¹⁵ power Doppler counts significantly improved area under the curve (AUC) values for the prediction of progression to RA (0.905 to 0.962).¹⁶ Salaffi *et al*¹⁷ described the likelihood of progression of UIA to RA using the presence of power Doppler on ultrasound (scores higher than grade 1), with OR 9.9 if one joint was involved, and 48.7 if more than three were involved; OR with high titre ACPA or RF was 10.9.

Detecting inflammation and damage:

Recommendation 3: Ultrasound and MRI are superior to clinical examination in the detection of joint inflammation; these techniques should be considered for a more accurate assessment of inflammation.

Strength of recommendation: 8.7 (95% CI 7.8 to 9.7)

This recommendation examines the added benefit of assessing joint inflammation by imaging over clinical examination. Sensitivity and specificity were initially extracted from the data; however, as clinical examination was used as the reference these results are difficult to use clinically. To overcome this we recorded detection rates; for example, how many times more (>onefold) or less (<onefold) does imaging detect inflammation over clinical examination. Our chosen approach may increase the number of false positive results.

We identified 51 studies comparing imaging and clinical examination in the detection of inflammation in various joints; 29 with ultrasound,^{18–36} 16 with MRI,^{21 26 29 30 37–44} 14 with scintigraphy,^{41 45–47} and two with PET (table 2). In general,

ultrasound and MRI detected joint inflammation more frequently than clinical examination; the mean detection rate for synovitis at the hand and wrist was 2.18-fold for ultrasound and 2.20-fold for MRI.³⁰ Using scintigraphy and PET were found to provide little benefit over clinical examination.

Recommendation 4: CR of the hands and feet should be used as the initial imaging technique to detect damage. However, ultrasound and/or MRI should be considered if CR do not show damage and may be used to detect damage at an earlier time point (especially in early RA).

Strength of recommendation: 9.0 (95% CI 8.4 to 9.6)

Three studies compared tissue damage (erosions or loss of joint space) detected by imaging with abnormal clinical examination. Caution is needed when interpreting these studies as bony involvement shown on imaging was compared with clinical signs of inflammation as reference.

Prognosis in RA: predicting outcome:

Recommendation 5: MRI bone oedema is a strong independent predictor of subsequent radiographic progression in early RA and should be considered for use as a prognostic indicator. Joint inflammation (synovitis) detected by MRI or ultrasound as well as joint damage detected by CR, MRI or ultrasound can also be considered for the prediction of further joint damage.

Strength of recommendation: 8.4 (95% CI 7.7 to 9.2)

Forty-eight longitudinal studies described how baseline changes in imaging predicted outcome, in particular erosive progression; 26 with MRI, 11 with ultrasound, 19 with CR, seven with DXA or DXR and three with scintigraphy. Of these, 46 studies examined the hands and 14 also included the feet; none compared the benefit of imaging different joints.

Bone marrow oedema

Of baseline MRI features, bone marrow (BM) oedema was a strong, independent predictor of erosive progression. Hetland *et al*^{48 49} have provided compelling data supporting this association; baseline MRI BM oedema was the only independent predictor of radiographic change in their 2 and 5-year follow-up studies (coefficient 0.75, p <0.001; and coefficient 0.82, p <0.001, respectively). Haavardsholm *et al*⁵⁰ also identified baseline MRI BM oedema (score >2 RAMRIS units) as an independent predictor of radiographic (OR 2.77, 95% CI 1.06 to 7.21) as well as MRI erosive progression (unstandardised β , B 0.21, 95% CI 0.08 to 0.34). This is supported by McQueen *et al*⁵¹ who described BM oedema to be predictive of MRI erosive progression, OR 6.47, p <0.001. This study also demonstrated that the development of radiological erosions at 1 year was highly unlikely in the absence of baseline MRI inflammatory changes (negative predictive value 0.92). Patients with erosive progression on CT also have higher baseline MRI BM oedema scores (relative risk (RR) of CT progression 3.8, 95% CI 1.5 to 9.3).⁵²

Synovitis

Baseline synovitis, detected by MRI or ultrasound, is a predictor of erosive progression. Dohn *et al*⁵² reported the RR of CT erosive progression with baseline ultrasound grey-scale synovitis as 11.2, 95% CI 0.65 to 195.7, p 0.1, baseline ultrasound power Doppler activity RR 7.6, 95% CI 0.91 to 63.2, p 0.061, and baseline MRI synovitis RR 0.68, 95% CI 0.04 to 11.5, p 0.79.⁵² The predictive value of baseline ultrasound grey-

Table 2 Recommendation 3: Summary of included studies comparing imaging and CE in the detection of joint inflammation

Ultrasound 29 studies, mean no. of subjects (range): 40.7 (6–100)		MRI 16 studies, mean no. of subjects (range): 47.3 (6–318)		Scintigraphy 14 studies, mean no. of subjects (range): 22.6 (8–38)	
Ultrasound hand/wrist vs CE (article reference)		MRI hand/wrist vs CE (article reference)		Scintigraphy hand/wrist vs CE (article reference)	
Synovitis ^{18–24}	Detection rate, mean (range) Ultrasound vs CE	MRI synovitis, vs clinical synovitis ^{21–24 37–40}	Detection rate, mean (range) MRI vs CE	vs tenderness/swelling ^{45 46}	Detection rate, mean (range) Scintigraphy vs CE
	2.18-fold (0.55–8.96-fold)		2.20-fold (0.58–5.43-fold) accuracy: 0.72		1.19-fold Validity: 0.45 Coefficient of association: –0.16
			vs pain ⁴¹		0.70-fold κ: 0.32, p 0.008
			vs swelling ⁴¹		1.33-fold κ: 0.64, p 0.023
			Correlation with DAS28 ⁴²		
			r 0.30–0.40 p<0.01		
Tenosynovitis ²⁵	1.06-fold	Relative efficacy for tenosynovitis ²⁶	2.48–4.69		
Relative efficacy of Ultrasound at detecting any inflammation vs TJC ²⁶	0.61–1.33	Relative efficacy of MRI synovitis vs TJC ²⁶	3.03–3.86		
Ultrasound foot/ankle vs CE		MRI foot/ankle vs CE		Scintigraphy feet vs CE	
Effusion ^{27 28}	0.52–0.99-fold κ: 0.04–0.16 % agreement: 71%	Synovitis ^{29 30 40 43}	1.71-fold (0.93–2.8-fold) % agreement: 45.5–71%	vs tenderness/swelling ⁴⁵	0.42-fold
Inflammation ²⁹	2.21-fold % agreement: 63%				
Synovitis ³⁰	0.87-fold				
Tenosynovitis ³⁰	0.58-fold				
		Tenosynovitis ³⁰	% agreement: 54.5–90.9%		
Ultrasound knees vs CE		MRI knees vs CE		Scintigraphy knees vs histology	
Baker's cyst ^{31–33}	1.88-fold (1.17–2.5-fold)	Synovitis vs clinical synovitis ⁴⁴	1.6–3.15-fold	vs histology ⁴⁷	1.11-fold
Suprapatellar bursitis ³³	1.7-fold				
Effusion ³⁴	1.27-fold (1.17–1.4-fold)				
Synovitis vs clinical synovitis ^{35 36}	r 0.9, p 0.0001				
vs DAS28	Strong correlation, p 0.006			Swelling vs histology ⁴⁷	0.72-fold
vs SJC	Weak correlation, p 0.038				

CE, clinical examination; DAS28, disease activity score in 28 joints; TJC, tender joint count; SJC, swollen joint count.

Recommendation

scale synovitis for MRI erosive progression performed better than MRI synovitis with positive likelihood ratios of 1.75 and 1.47, respectively, and accuracy of 70% and 62%, respectively.⁵³ Conaghan *et al*⁵⁴ described a close correlation between the degree of MRI synovitis and the number of new erosions, with the AUC for MRI synovitis the only significant predictor of erosive progression (AUC for MRI synovitis r 0.420, $p < 0.007$).

Tenosynovitis

Baseline tenosynovitis on ultrasound appears to be predictive of erosive progression at 1 year (OR 7.18) and 3 years (OR 3.4).⁵⁵ This effect has not been seen with MRI tenosynovitis,⁵⁶ but baseline MRI tendinopathy has been shown to be predictive of tendon rupture at 1 year (OR 1.57, p 0.02) and 6 years (OR 1.52, p 0.03).⁵⁷

Erosions

Baseline erosions detected by various imaging techniques appear to be predictive of further erosions at 6 months; MRI erosions (β 0.63, $p < 0.001$), radiographic erosions (β 0.68, p 0.04), with ultrasound erosions less significant (β 0.57, p 0.07).⁵⁸ Several studies have reported that baseline MRI erosions are predictive of erosive progression;^{59–60–62} and the absence of baseline MRI erosions predicts that radiographic or MRI erosions are unlikely (negative predictive value 1.0).⁶¹ Baseline radiographic erosions independently predict further radiographic progression (at 3 years, OR 8.47; at 10 years, OR 5.64–18.1).^{63–65} In addition, the baseline Larsen score is shown to predict an annual radiological progression rate greater than the median (OR 2.6, 95% CI 1.3 to 5.3).⁶⁵

Digital x-ray radiogrammetry/dual-emission x-ray absorptiometry

Early hand bone loss measured by change in estimated bone mineral density in the first year of disease by DXR appears to be an independent predictor of erosive progression, even up to 20 years.^{53–66–67} Baseline femoral neck osteopenia or osteoporosis are also predictive of radiographic erosive progression.⁶⁸

Scintigraphy

Baseline inflammatory disease measured by scintigraphy appears to be associated with radiographic progression.⁶⁹ In addition, multiple regression analysis has demonstrated that progression of radiographic joint destruction was primarily predicted by ^{99m}Tc-IgG scintigraphy; joint swelling, ESR and IgM RF were not predictive. This suggests that scintigraphy may be superior to conventional clinical and laboratory measurements in the prediction of joint destruction.⁷⁰ However, when comparing scintigraphy to other baseline imaging predictors of progression, baseline MRI BM oedema score (Spearman's correlation, r 0.67), MRI synovitis score (r 0.57), and ^{99m}Tc-NC scintigraphy uptake (r 0.45) were predictive of change in MRI erosion score from baseline to 2 years. In the multivariate analysis, the BM oedema score was the only baseline variable that predicted erosive progression (OR 4.2, 95% CI 1.3 to 13.8).⁷¹

Prognosis in RA: Predicting response to treatment:

Recommendation 6: Inflammation seen on imaging may be more predictive of a therapeutic response than clinical features of disease activity; imaging may be used to predict response to treatment.

Strength of recommendation: 7.8 (95% CI 6.7 to 8.8)

Two prospective cohort studies have assessed the use of clinical measures and imaging to predict response to anti-tumour necrosis factor (TNF) therapy. Ellegaard *et al*⁷² measured ultrasound Doppler activity and clinical parameters at baseline to predict which patients would benefit from treatment, assessed by treatment persistence at 1 year. They identified ultrasound Doppler activity to be the only baseline parameter to predict treatment persistence (p 0.024); baseline clinical measures including tender and swollen joint counts, C-reactive protein, 28-joint disease activity score (DAS28) and health assessment questionnaire showed no significant association. Elzinga *et al*⁷³ used changes in PET uptake 2 weeks after treatment to predict future treatment response, according to DAS28. A significant correlation was seen between the changes in PET activity at 2 weeks and DAS28 at 14 and 22 weeks after treatment (r 0.62, $p < 0.05$; r 0.65, $p < 0.01$ respectively).

Monitoring disease progression:

Recommendation 7: Given the improved detection of inflammation by ultrasound and MRI than by clinical examination, they may be useful in monitoring disease activity.

Strength of recommendation: 8.3 (95% CI 7.4 to 9.1)

No published data were identified that specifically addressed how imaging should be used to monitor RA disease activity. In the absence of this information, data were extracted on each factor separately.

Comparison of the ability of imaging to detect inflammation

Several studies compared ultrasound and MRI in the detection of joint inflammation, with MRI considered the reference technique. There seems to be significant association between these modalities,^{23–24} but aside from access to imaging, there may be advantages to using each technique in certain situations. For example, ultrasound has been shown to detect more joint and tendon sheath effusions than MRI,⁵⁸ whereas MRI appears to be more sensitive in identifying tenosynovitis.⁷⁴ Comparisons of conventional high-field MRI with dedicated, low-field extremity MRI have shown high agreement for synovitis, with lower agreement for BM oedema and tenosynovitis detected by low-field MRI, with high-field MRI as reference.^{75–76} Low-field MRI without contrast also demonstrates poor sensitivity in the detection of synovitis, compared with power Doppler ultrasound.⁷⁷ Only one study compared scintigraphy with more modern imaging techniques, and showed strong correlation between uptake on scintigraphy and inflammatory changes seen on MRI.⁷⁸

Responsiveness to change in inflammation

Ultrasound and MRI appear to show good responsiveness to change. A study of responsiveness of MRI and ultrasound to change in inflammation with treatment has shown that MRI synovitis (standardised response mean (SRM) -0.79 to -0.92), MRI tenosynovitis (SRM -0.70 to -1.02) and BM oedema (SRM -1.05 to -1.24) were responsive to change, but ultrasound inflammation (synovitis, tenosynovitis and effusion) was less responsive (SRM -0.37 to -0.54).²⁶ A study by Haavardsholm *et al*⁷⁹ reported MRI to have a higher potential to detect change in wrist BM oedema than in synovitis over 1 year. The smallest detectable difference for a range of ultrasound measures including power Doppler was low in a large 1-year observational multiple-reader study of RA patients treated with anti-TNF agents, demonstrating both the reliability of this measure and the ability to detect individual-level important

change. At the group level, there were significant changes in all ultrasound synovial assessments in parallel with DAS28 changes.⁸⁰ When comparing the changes in power Doppler and grey-scale ultrasound activity with response to treatment, grey-scale ultrasound appears to perform better,⁸¹ as does the addition of contrast enhancement.⁸²

Which joints to assess

Only one study directly compared the assessment of inflammation by imaging different areas; Calisir *et al*⁴⁰ described MRI synovitis and BM oedema in the hands and feet of patients with early RA and found no significant difference in MRI inflammation in these regions.

Recommendation 8: The periodic evaluation of joint damage, usually by radiographs of the hands and feet, should be considered. MRI (and possibly ultrasound) is more responsive to change in joint damage and can be used to monitor disease progression.

Strength of recommendation: 7.8 (95% CI 6.8 to 8.9)

As for the previous recommendation, there were no specific data on the recommended frequency of imaging in the assessment of progressive joint damage.

Comparison of the ability of imaging to detect damage

Dohn *et al*⁵² performed comparison studies of the ability of CR, CT, ultrasound and MRI to detect erosive damage.^{53–83} With CT as the reference technique, CR was shown to have an accuracy of 81%, MRI of 89% and ultrasound of 80%, with high specificities and lowest sensitivity for CR.^{52–83} A previous systematic review has described ultrasound to be more effective for erosion detection than CR, with comparable efficacy to MRI.⁸⁴ A summary of data comparing the different imaging modalities in the detection of erosions is given in table 3.^{24–26–29–39–43–52–58–75–76–83–85–102}

Studies assessing tendon damage have shown ultrasound to be more sensitive than MRI in the detection of finger extensor tendon tears later confirmed at surgery;¹⁰³ and moderate agreement between ultrasound and MRI (used as the reference technique) in the assessment of shoulder tendon involvement.¹⁰⁴

Responsiveness to change in damage

CR is the standard imaging technique used to detect and monitor joint damage. There are some data suggesting that CR

is responsive to change in erosions on an individual level, particularly after the first 12 months of disease.²⁶ Radiographic progression appears to be most rapid in the first 2 years of disease, with 75% of all damage seen in the first 5 years of a 10-year study.¹⁰⁵ MRI seems to be more responsive to change at earlier time points, but measures of annual progression rates are similar with MRI and CR.²⁶ This is supported by Østergaard *et al*,¹⁰⁶ who found that 78% of new radiographic bone erosions were seen at least 1 year earlier by MRI, in fact MRI detection of new erosions preceded CR by a median of 2 years.

Which joints to assess

Early erosive changes on CR appear to be more common in the feet than in the hands, but from year 3 onwards these areas are more equally affected.^{105–107}

Recommendation 9: Monitoring of functional instability of the cervical spine by lateral radiograph obtained in flexion and neutral should be performed in patients with clinical suspicion of cervical involvement. When the radiograph is positive or specific neurological symptoms and signs are present, MRI should be performed.

Strength of recommendation: 9.4 (95% CI 8.9 to 9.8)

Thirteen studies described the assessment of cervical spine involvement in RA, summarised in table 4.^{108–120} No studies explored the appropriate frequency for monitoring change in the cervical spine; Yurube *et al*¹¹⁸ investigated baseline features on CR predictive of future cervical instability and found that patients with baseline deforming hand changes, cervical vertical subluxation (VS), and subaxial subluxation showed more progression in VS and subaxial subluxation at 5 years, and Reijnierse *et al*¹²⁰ identified that baseline MRI atlas erosions and reduced subarachnoid space were associated with clinical neurological dysfunction at 1 year.

Comparison studies of different imaging modalities of the cervical spine have shown variation in the detection of the different pathologies, according to the imaging technique used. Fezoulidis *et al*¹⁰⁸ found CR and CT to be comparable and better than MRI in detecting atlanto-axial and atlanto-occipital lesions, but MRI to be superior in identifying odontoid lesions. MRI also seems to be better at showing erosions of the dens.¹¹⁷

Independent of the imaging modality used, dynamic lateral views of the cervical spine are more useful than static, neutral views in detecting atlanto-axial subluxation (AAS), in particular

Table 3 Recommendation 8: Summary of included studies comparing imaging in the detection of erosions

Comparator vs reference technique (article reference)	Sensitivity	Specificity	Accuracy	κ	Detection rate, mean (range)
Hand/wrist erosions:					
MRI vs CT ^{52–83–85–87}	0.61–0.68	0.92–0.96	0.77–0.89	0.63	0.71-fold (0.60–0.81-fold)
Ultrasound vs CT ^{52–83}	0.42–0.44	0.91–0.95	0.80–0.84	0.44	
CR vs CT ^{52–83–85–88}	0.14–0.54	0.92–1.0	0.63–0.81	0.29	0.34-fold (0.16–0.60-fold)
CR vs MRI ^{24–26–39–58–75–89–90–100}	0.0–0.55	0.5–1.0	0.23–0.92		0.38-fold (0.06–0.80-fold)
CR vs ultrasound ^{24–58–97–101}	0.48	1.0			0.60-fold (0.18–1.21-fold)
Ultrasound vs MRI ^{24–58–97–100}	0.33–0.87	0.68–1.0	correlation coefficient 0.68–0.9	p<0.0005–<0.001	0.77-fold (0.35–1.51-fold)
Low vs high-field MRI ^{75–76–91–95}	0.46–0.94	0.93–0.94	0.55–0.94		0.94-fold (0.46–1.16-fold)
Feet erosions:					
CR vs MRI ^{29–43}	0.32–0.80	0.85–0.98		0.65 p 0.002	1.19-fold (0.55–1.83-fold)
CR vs ultrasound ^{29–102}					0.53-fold (0.42–0.64-fold)
Ultrasound vs MRI ²⁹	0.79	0.97	0.96		1.3-fold
CR, conventional radiography.					

Recommendation

Table 4 Recommendation 9: Summary of included studies comparing imaging in the assessment of the cervical spine

Article year, (reference)	No. of subjects	Cervical spine imaging modality	Parameter assessed	Outcome
1989 ¹⁰⁸	55	CR (AP, lateral F/E, OM) MRI CT	Atlanto-axial lesions Atlanto-occipital lesions Odontoid lesions Odontoid fibro-ostosis	Atlanto-axial lesions: CR = CT > MRI Atlanto-occipital lesions: CR = CT > MRI Odontoid lesions: MRI > CR/CT Odontoid fibro-ostosis: CR = CT > MRI
2000 ¹⁰⁹	5 known AAS	CR (F/E) MRI (F/E)	AAS	More detail seen with MRI, and using F/E views
2005 ¹¹⁰	31	CR (F/E) MRI (F/E)	ADI Dense erosions	CR showed greater ADI in flexion than MRI, p 0.001 No significant difference in neutral/extension Assessment of dens erosions easier with MRI
1998 ¹¹¹	65 unstable AAS	CR (lateral N/F/E)	AAS	Significant difference between AAS in neutral and flexion/extension, p<0.0001
1998 ¹¹²	28 symptomatic	CR (AP, lateral N/F, OM) MRI CT	AAS Odontoid erosions/cysts	Combination on MRI with CR showed more involvement than CT with CR (1.25-fold more VS; 1.13-fold more erosions/cysts)
2000 ¹¹³	42 symptomatic	MRI (N/F)	Reduction in subarachnoid space Brainstem compression	Flexion views showed more: brainstem compression (1.17-fold) reduction in the subarachnoid space at the atlanto-axial level (1.06-fold) and below C2 (1.13-fold)
2000 ¹¹⁴	25	CR (AP, lateral F/E, OM)	Odontoid erosions	Lateral views showed more erosions (1.57-fold) than open mouth views
2011 ¹¹⁵	56 symptomatic	CR (lateral) CT	CT factors predictive of VS on CR	VS greater in presence of odontoid erosions, p<0.05 Odontoid erosions significantly associated with odontoid osteoporosis, p<0.05
1995 ¹¹⁶	136 symptomatic	CR (AP, lateral F/E) MRI	MRI findings in normal CR	All MRI abnormal with normal CR: Effusion: 28% Pannus: 62%
2009 ¹¹⁷	40	CR (lateral N/F/E, OM) MRI (N/F/E) CT	AAS Dens erosions	% patients with C-spine involvement on: CR 47.5%, MRI 70%, CT 28.2% Anterior AAS seen more in flexion on CR than MRI, p<0.005 CT best at detecting lateral AAS Dens erosions: CR 12.5%, MRI 67.5%, CT 41%
2011 ¹¹⁸	267	CR (lateral N/F/E)	Baseline features predictive of VS and SAS at 5 years	Prediction of VS: AAS, p 0.01; VS, p<0.01; SAS, p 0.06 Prediction of SAS: AAS, p 0.29; VS, p<0.01; SAS, p<0.01
1987 ¹¹⁹	18 symptomatic	CR (AP, lateral F/E) MRI	AAS CS SAS Dens erosions	MRI vs CR: AAS: 0.88-fold CS: 1.0-fold SAS: 0.5-fold Dens erosions: 1.27-fold
2001 ¹²⁰	46 symptomatic	CR (lateral N/F, OM) MRI	Baseline CR and MRI features predictive of clinical neurological dysfunction at 1 year	CR not predictive (odontoid erosions, AAS) Dysfunction according to MRI (OR): Dens erosion: 1.5; atlas erosion: 4.9 Decreased subarachnoid space: 12.0 Decreased atlanto-axial space: 2.4 Brainstem compression: 2.3

AAS, atlantoaxial subluxation; ADI, atlanto-dental interval; AP, anteroposterior; CR, conventional radiography; CS, craniovertebral settling; E, extension; F, flexion; N, neutral; OM, open mouth; SAS, subaxial subluxations; VS, vertical subluxations.

anterior AAS.¹¹¹ Flexion and neutral views are used commonly, with evidence to suggest greater change in the atlanto-dental interval with these views.¹¹⁰ The open mouth view is used for imaging the odontoid peg and to assess for lateral and rotatory AAS; whereas posterior AAS can be measured with neutral and extension views, and VS with a lateral neutral view, although these types of AAS are much less common than anterior AAS.¹¹⁷ When using CR to assess odontoid erosions, lateral cervical spine views appear to be more sensitive than open mouth views.¹¹⁴

Imaging in clinical remission:

Recommendation 10: Ultrasound and MRI can detect inflammation that predicts subsequent joint damage, even when clinical remission is present and can be used to assess persistent inflammation.

Strength of recommendation: 8.8 (95% CI 8.0 to 9.6)

The role of imaging in the detection of inflammation and subsequent prediction of outcome has been discussed previously (recommendation 5). There is good evidence to support the disparity between clinical remission and evidence of ongoing inflammation seen with various imaging modalities. Power Doppler activity has been found in 15–62% of patients in clinical remission according to DAS28, American College of Rheumatology or simplified disease activity index remission criteria,^{121–124} MRI synovitis in 96% and BM oedema in 52%.^{124 125} In one study, 60% of patients in disease activity score remission had increased uptake on scintigraphy.¹²⁶

The significance of persistent inflammation, shown in a number of studies, is summarised in table 5.^{127–133} The presence of ultrasound synovial hypertrophy, power Doppler activity and MRI synovitis at baseline in clinical remission has been shown to be significantly associated with structural progression at 1 year, even in asymptomatic joints.¹²⁷ Baseline ultrasound

Table 5 Recommendation 10: Summary of included studies describing outcome in the presence of image-detected inflammation in clinical remission

Article year (reference)	No. of subjects	Duration of follow-up (months)	Baseline assessment modality	Outcome parameter assessed	Results
2008 ¹²⁷	102	12	Ultrasound SH, PD synovitis	CR progression (Genant score)	SH: OR 2.31, p 0.032 PD synovitis: OR 12.21, p<0.001 OR 2.98, p 0.002
2011 ¹²⁸	94	12	MRI synovitis Ultrasound SH, PD synovitis, remissions (no SH or PD synovitis)	Relapse rate	% patients having flare: in ultrasound remission: 20.0% With ultrasound PD activity: 47.1%, p 0.009
2009 ¹²⁹	106	24	Ultrasound joint count, PD synovitis	Relapse rate	Unsustained remission vs sustained remission: higher PD: OR 12.8, p<0.05 Higher ultrasound joint count: OR 4.6, p<0.05
2005 ¹³⁰	32	12	Ultrasound RI	Relapse rate	Relapse rate higher with low RI se 0.80, sp 1.0, acc 0.96, p<0.01
2007 ¹³¹	169	24	Sustained ACR/DAS remission	CR progression (Larsen score)	Increase in Larsen score in (unsustained vs sustained): ACR remission: p 0.017 DAS remission: p<0.001
2004 ¹³²	187	24	Sustained ACR/DAS remission	CR progression (SHS)	Increase in SHS score in (unsustained vs sustained): ACR remission: p 0.053 DAS remission: p 0.017
2012 ¹³³	535	24	Remission according to DAS, SDAI, CDAI, ACR/EULAR	CR progression (SHS)	% patients with CR progression with baseline remission: DAS: 30% SDAI: 24% CDAI: 19% ACR/EULAR: 20%

ACR, American College of Rheumatology; CDAI, clinical disease activity index; CR, conventional radiography; DAS, disease activity score; EULAR, European League Against Rheumatism; PD, power Doppler; RI, resistive index; SDAI, simplified disease activity index; SH, synovial hypertrophy; SHS, Sharp/van der Heijde score.

inflammatory activity in clinical remission also seems predictive of future disease flare, with 20% of patients experiencing a flare within 12 months in the absence of baseline ultrasound power Doppler activity, compared with 47% in patients with baseline power Doppler activity (p 0.009).¹²⁸ Although radiographic progression can still be seen in clinical remission, individuals with sustained clinical remission show fewer signs of structural progression compared with patients with clinically relapsing disease.^{131–133}

Future research agenda

The most important topics for future research according to currently available evidence and clinical practice were formulated by the group, shown in table 6.

Table 6 Future research agenda

Research agenda
1 Further evaluation of the specific joints to be assessed, timing of assessment(s) and the evaluation system to be employed in order to optimise the role of modern imaging modalities in diagnosis, prognosis and outcome measurement of RA
2 To assess algorithms using established and modern imaging modalities to examine their cost-effectiveness in clinical practice diagnosis, prognosis and outcome measurement of RA
3 To elucidate further the importance of subclinical (imaging-alone detected) inflammation, including synovitis, bone marrow oedema and tenosynovitis, especially in low disease activity states and to define key thresholds to guide intervention
4 To assess further the importance of imaging, in particular MRI and ultrasound, in the evaluation of damage, including joint space narrowing and cartilage loss
5 Assessing the feasibility, costs and appropriate training required to use ultrasound and MRI in clinical practice

RA, rheumatoid arthritis.

DISCUSSION

These are the first recommendations produced by a EULAR task force on imaging in RA clinical practice. The recommendations were developed by an international group of experts with detailed literature review, and aimed to address clinical questions relevant to current practice. We acknowledge there is still a large amount of research required to optimise the use of imaging tools in routine clinical practice, in particular which joints should be used for disease assessment and monitoring and consideration of the feasibility, costs and appropriate training required to use ultrasound and MRI in clinical practice. In view of a lack of literature at the time of the review, these recommendations have not focused on detecting joint space narrowing, which is important to consider in view of the impact on functional status.¹³⁴ We have made specific reference to this in our proposed future research agenda.

In summary, we have developed 10 recommendations on various aspects of imaging in RA. These are based on the best available evidence and clinical expertise supported by an international panel of experts. We aimed to produce recommendations that are practical and valuable to clinical practice.

Author affiliations

¹Department of Rheumatology, University Hospital Southampton, Southampton, UK

²Department of Rheumatology, Yeovil District Hospital, Yeovil, UK

³Copenhagen Center for Arthritis Research, Center of Rheumatology and Spine Diseases, Copenhagen University Hospital at Glostrup, Copenhagen, Denmark

⁴Department of Rheumatology, Leiden University Medical Center, Leiden, The Netherlands

⁵3rd Department of Rheumatology, National Institute of Rheumatology and Physiotherapy, Budapest, Hungary

⁶Department of Rheumatology, Ambroise Paré Hospital, Boulogne-Billancourt, France

⁷Department of Medicine, Section of Rheumatology, Helsingborg Hospital, Helsingborg, Sweden

⁸Section of Rheumatology, Institution of Clinical Science, University Hospital, Lund, Sweden

⁹Department of Rheumatology, Università Politecnica delle Marche, Ancona, Italy

¹⁰Department of Rheumatology, Diakonhjemmet Hospital, Oslo, Norway

Recommendation

- ¹¹Department of Rheumatology, Hospital of Southern Norway, Kristiansand, Norway
¹²Department of Radiology, Aarhus University Hospital, Aarhus, Denmark
¹³Department of Clinical immunology and Rheumatology, Academic Medical Centre, Amsterdam, The Netherlands
¹⁴Rheumatology Department, Hospital General Universitario Gregorio Marañón, Madrid, Spain
¹⁵Department of Radiology, Leeds General Infirmary, Leeds, UK
¹⁶Centre for Rheumatology, Heinrich-Heine University of Düsseldorf, Düsseldorf, Germany
¹⁷Institute of Diagnostic and Interventional Radiology, University Hospital Center Zagreb, Zagreb, Croatia
¹⁸Immanuel Krankenhaus Berlin, Medical Centre for Rheumatology Berlin-Buch, Berlin, Germany
¹⁹Division of Rheumatology, Medical University of Vienna, Vienna, Austria
²⁰Rheumatology Department, Clinic of Heart and Rheumatic Diseases, Clinical Center University of Sarajevo, Sarajevo, Bosnia and Herzegovina
²¹Division of Musculoskeletal Disease, Section of Musculoskeletal Disease, University of Leeds & NIHR Leeds Musculoskeletal Biomedical Research Unit, Leeds, UK

Acknowledgements The authors would like to thank Louise Falzon for her work in the development of the literature search strategy.

Contributors ANC and CJE performed the literature review and produced drafts of the manuscript with advice from PGC and MO. All authors were involved in the production of the recommendations, and have reviewed the final manuscript.

Funding The authors would like to thank EULAR for financial support for this work.

Competing interests ANC, MØ, DvdH, PVB, KF, WG, EAH, GH, AGJ, RBML, EN, PJO'C, BO, KP, WAS, JSS, SS, IW: none declared. CJE: Speakers bureau for Roche, BMS, Pfizer, Abbott, UCB, Samsung, MSD, GSK; MADA: Consulting fees and PI of international multicentre study on ultrasound for Bristol-Myers Squibb; speakers bureau for Roche, BMS, Pfizer, Abbott and UCB; research grant on ultrasound from PHRC; book royalties from Elsevier; PGC: speakers bureau or advisory boards for BMS, Pfizer and Roche.

Provenance and peer review Not commissioned; externally peer reviewed.

REFERENCES

- Nell VP, Machold KP, Eberl G, *et al.* Benefit of very early referral and very early therapy with disease-modifying anti-rheumatic drugs inpatients with early rheumatoid arthritis. *Rheumatology (Oxford)* 2004;**43**:906–14.
- Finckh A, Liang MH, van Herckenrode CM, *et al.* Long-term impact of early treatment on radiographic progression in rheumatoid arthritis: a meta-analysis. *Arthritis Rheum* 2006;**55**:864–72.
- Saraux A, Berthelot JM, Chales G, *et al.* Ability of the American College of Rheumatology 1987 criteria to predict rheumatoid arthritis in patients with early arthritis and classification of these patients two years later. *Arthritis Rheum* 2001;**44**:2485–91.
- Østergaard M, Pedersen SJ, Dohn UM. Imaging in rheumatoid arthritis—status and recent advances for magnetic resonance imaging, ultrasonography, computed tomography and conventional radiography. *Best Pract Res Clin Rheumatol* 2008;**22**:1019–44.
- Dougados M, Betteridge N, Burmester GR, *et al.* EULAR standardised operating procedures for the elaboration, evaluation, dissemination, and implementation of recommendations endorsed by the EULAR standing committees. *Ann Rheum Dis* 2004;**63**:1172–6.
- Shekelle PG, Woolf SH, Eccles M, *et al.* Clinical guidelines: developing guidelines. *BMJ* 1999;**318**:593–6.
- Matsos MP, Khalidi N, Zia P, *et al.* Ultrasound of the hands and feet for rheumatological disorders: influence on clinical diagnostic confidence and patient management. *Skeletal Radiol* 2009;**38**:1049–54.
- Agrawal S, Bhagat SS, Dasgupta B. Improvement in diagnosis and management of musculoskeletal conditions with one-stop clinic-based ultrasonography. *Mod Rheumatol* 2009;**19**:53–6.
- Sugimoto H, Takeda A, Masuyama J, *et al.* Early-stage rheumatoid arthritis: diagnostic accuracy of MR imaging. *Radiology* 1996;**198**:185–92.
- Sugimoto H, Takeda A, Hyodoh K. Early-stage rheumatoid arthritis: prospective study of the effectiveness of MR imaging for diagnosis. *Radiology* 2000;**216**:569–75.
- Narváez J, Sirvent E, Narváez JA, *et al.* Usefulness of magnetic resonance imaging of the hand versus anticyclic citrullinated peptide antibody testing to confirm the diagnosis of clinically suspected early rheumatoid arthritis in the absence of rheumatoid factor and radiographic erosions. *Semin Arthritis Rheum* 2008;**38**:101–9.
- Machado PMMC, Koevoets R, Bombardier C, *et al.* The value of magnetic resonance imaging and ultrasound in undifferentiated arthritis: a systematic review. *J Rheumatol* 2011;**87**:31–7.
- Duer-Jensen A, Horslev-Petersen K, Hetland ML, *et al.* MRI bone edema is an independent predictor of development of rheumatoid arthritis in patients with early undifferentiated arthritis. *Arthritis Rheum* 2011;**63**:2192–202.
- Eshed I, Feist E, Althoff CE, *et al.* Tenosynovitis of the flexor tendons of the hand detected by MRI: an early indicator of rheumatoid arthritis. *Rheumatology (Oxford)* 2009;**48**:887–91.
- van der Helm-van Mil AH, le Cessie S, van Dongen H, *et al.* A prediction rule for disease outcome in patients with recent-onset undifferentiated arthritis: how to guide individual treatment decisions. *Arthritis Rheum* 2007;**56**:433–40.
- Filer A, De Pablo P, Allen G, *et al.* Utility of ultrasound joint counts in the prediction of rheumatoid arthritis in patients with very early synovitis. *Ann Rheum Dis* 2011;**70**:500–7.
- Salaffi F, Ciapetti A, Gasparini S, *et al.* A clinical prediction rule combining routine assessment and power Doppler ultrasonography for predicting progression to rheumatoid arthritis from early-onset undifferentiated arthritis. *Clin Exp Rheumatol* 2010;**28**:686–94.
- Filippucci E, Iagnocco A, Salaffi F, *et al.* Power Doppler sonography monitoring of synovial perfusion at the wrist joints in patients with rheumatoid arthritis treated with adalimumab. *Ann Rheum Dis* 2006;**65**:1433–7.
- Krejza J, Kurylszyn-Moskal A, Sierakowski S, *et al.* Ultrasonography of the periparticular changes in patients with early active rheumatoid arthritis. *Med Sci Monit* 1998;**4**:366–9.
- Ribbens C, André B, Marcelis S, *et al.* Rheumatoid hand joint synovitis: gray-scale and power Doppler US quantifications following anti-tumor necrosis factor- α treatment: pilot study. *Radiology* 2003;**229**:562–9.
- Horikoshi M, Suzuki T, Sugihara M, *et al.* Comparison of low-field dedicated extremity magnetic resonance imaging with articular ultrasonography in patients with rheumatoid arthritis. *Mod Rheumatol* 2010;**20**:556–60.
- Szkudlarek M, Court-Payen M, Strandberg C, *et al.* Power Doppler ultrasonography for assessment of synovitis in the metacarpophalangeal joints of patients with rheumatoid arthritis: a comparison with dynamic magnetic resonance imaging. *Arthritis Rheum* 2001;**44**:2018–23.
- Terslev L, von der Recke P, Savnik A, *et al.* Diagnostic sensitivity and specificity of Doppler ultrasound in rheumatoid arthritis. *J Rheumatol* 2008;**35**:49–53.
- Szkudlarek M, Jensen K, Thomsen H, *et al.* Ultrasonography of the metacarpophalangeal and proximal interphalangeal joints in rheumatoid arthritis: a comparison with magnetic resonance imaging, conventional radiography and clinical examination. *Arthritis Res Ther* 2006;**8**:R52.
- Hmamouchi I, Bahiri R, Sifri N, *et al.* A comparison of ultrasound and clinical examination in the detection of flexor tenosynovitis in early arthritis. *BMC Musculoskelet Disord* 2011;**12**:91.
- Haavardsholm EA, Østergaard M, Hammer HB, *et al.* Monitoring anti-TNF alpha treatment in rheumatoid arthritis: responsiveness of magnetic resonance imaging and ultrasonography of the dominant wrist joint compared with conventional measures of disease activity and structural damage. *Ann Rheum Dis* 2009;**68**:1572–9.
- Riente L, Delle Sedie A, Scirè CA, *et al.* Ultrasound imaging for the rheumatologist. XXXI. Sonographic assessment of the foot in patients with rheumatoid arthritis. *Clin Exp Rheumatol* 2011;**29**:1–5.
- Luukkainen RK, Saltyshov M, Koski JM, *et al.* Relationship between clinically detected joint swelling and effusion diagnosed by ultrasonography in metatarsophalangeal and talocrural joints in patients with rheumatoid arthritis. *Clin Exp Rheumatol* 2003;**21**:632–4.
- Szkudlarek M, Narvestad E, Klarlund M, *et al.* Ultrasonography of the metatarsophalangeal joints in rheumatoid arthritis: comparison with magnetic resonance imaging, conventional radiography, and clinical examination. *Arthritis Rheum* 2004;**50**:2103–12.
- Wakefield RJ, Freeston JE, O'Connor P, *et al.* The optimal assessment of the rheumatoid arthritis hindfoot: a comparative study of clinical examination, ultrasound and high field MRI. *Ann Rheum Dis* 2008;**67**:1678–82.
- Andonopoulos AP, Yarmenitis S, Sfountouris H, *et al.* Baker's cyst in rheumatoid arthritis: an ultrasonographic study with a high resolution technique. *Clin Exp Rheumatol* 1995;**13**:633–6.
- Chávez-López MA, Naredo E, Acebes-Cachafeiro JC, *et al.* Diagnostic accuracy of physical examination of the knee in rheumatoid arthritis: clinical and ultrasonographic study of joint effusion and Baker's cyst. *Rheumatol Clin* 2007;**3**:98–100.
- Kane D, Balint PV, Sturrock RD, *et al.* Ultrasonography is superior to clinical examination in the detection and localization of knee joint effusion in rheumatoid arthritis. *J Rheumatol* 2003;**30**:966–71.
- Riente L, Delle Sedie A, Filippucci E, *et al.* Ultrasound Imaging for the rheumatologist XXVII. Sonographic assessment of the knee in patients with rheumatoid arthritis. *Clin Exp Rheumatol* 2010;**28**:300–3.
- Batalov A, Kuzmanova S, Atanasov A. Ultrasound follow-up study of arthroscopied patients with gonitis. *Folia Med* 1999;**41**:63–70.
- Carotti M, Salaffi F, Manganelli P, *et al.* Power Doppler sonography in the assessment of synovial tissue of the knee joint in rheumatoid arthritis: a preliminary experience. *Ann Rheum Dis* 2002;**61**:877–82.

37. **Tamai M**, Kawakami A, Iwamoto N, *et al*. Comparative study of the detection of joint injury in early-stage rheumatoid arthritis by magnetic resonance imaging of the wrist and finger joints and physical examination. *Arthritis Care Res* 2011;**63**:436–9.
38. **Goupille P**, Roulot B, Akoka S, *et al*. Magnetic resonance imaging: a valuable method for the detection of synovial inflammation in rheumatoid arthritis. *J Rheumatol* 2001;**28**:35–40.
39. **Tonolli-Serabian I**, Poet JL, Dufour M, *et al*. Magnetic resonance imaging of the wrist in rheumatoid arthritis: comparison with other inflammatory joint diseases and control subjects. *Clin Rheumatol* 1996;**15**:137–42.
40. **Calisir C**, Murat Aynaci AI, Korkmaz C. The accuracy of magnetic resonance imaging of the hands and feet in the diagnosis of early rheumatoid arthritis. *Joint Bone Spine* 2007;**74**:362–7.
41. **Roimicher L**, Lopes FPPL, de Souza SAL, *et al*. ^{99m}Tc-anti-TNF- α scintigraphy in RA: a comparison pilot study with MRI and clinical examination. *Rheumatology (Oxford)* 2011;**50**:2044–50.
42. **Emery P**, van der Heijde D, Østergaard M, *et al*. Exploratory analyses of the association of MRI with clinical, laboratory and radiographic findings in patients with rheumatoid arthritis. *Ann Rheum Dis* 2011;**70**:2126–30.
43. **Forslind K**, Johanson A, Larsson EM, *et al*. Magnetic resonance imaging of the fifth metatarsophalangeal joint compared with conventional radiography in patients with early rheumatoid arthritis. *Scand J Rheumatol* 2003;**32**:131–7.
44. **Forslind K**, Larsson EM, Eberhardt K, *et al*. Magnetic resonance imaging of the knee: a tool for prediction of joint damage in early rheumatoid arthritis? *Scand J Rheumatol* 2004;**33**:154–61.
45. **Möttönen TT**, Hannonen P, Toivanen J, *et al*. Scintigraphy of rheumatoid peripheral joints. Reliability of visual assessment vs. computerized methods. *Scand J Rheumatol* 1987;**16**:421–7.
46. **Remans J**, Berghs H, Drieskens L, *et al*. Proximal interphalangeal arthroscintigraphy in rheumatoid arthritis. *Ann Rheum Dis* 1978;**37**:440–3.
47. **de Bois MH**, Tak PP, Arndt JW, *et al*. Joint scintigraphy for quantification of synovitis with ^{99m}Tc-labelled human immunoglobulin G compared to histological examination. *Clin Exp Rheumatol* 1995;**13**:155–9.
48. **Hetland ML**, Ejbjerg B, Hørslev-Petersen K, *et al*. MRI bone oedema is the strongest predictor of subsequent radiographic progression in early rheumatoid arthritis. Results from a 2-year randomised controlled trial (CIMESTRA). *Ann Rheum Dis* 2009;**68**:384–90.
49. **Hetland ML**, Stengaard-Pedersen K, Junker P, *et al*. Radiographic progression and remission rates in early rheumatoid arthritis—MRI bone oedema and anti-CCP predicted radiographic progression in the 5-year extension of the double-blind randomised CIMESTRA trial. *Ann Rheum Dis* 2010;**69**:1789–95.
50. **Haavardsholm EA**, Bøyesen P, Østergaard M, *et al*. Magnetic resonance imaging findings in 84 patients with early rheumatoid arthritis: bone marrow oedema predicts erosive progression. *Ann Rheum Dis* 2008;**67**:794–800.
51. **McQueen FM**, Stewart N, Crabbe J, *et al*. Magnetic resonance imaging of the wrist in early rheumatoid arthritis reveals progression of erosions despite clinical improvement. *Ann Rheum Dis* 1999;**8**:156–63.
52. **Dohn UM**, Ejbjerg B, Boonen A, *et al*. No overall progression and occasional repair of erosions despite persistent inflammation in adalimumab-treated rheumatoid arthritis patients: results from a longitudinal comparative MRI, ultrasonography, CT and radiography study. *Ann Rheum Dis* 2011;**70**:252–8.
53. **Bøyesen P**, Haavardsholm EA, van der Heijde D, *et al*. Prediction of MRI erosive progression: a comparison of modern imaging modalities in early rheumatoid arthritis patients. *Ann Rheum Dis* 2011;**70**:176–9.
54. **Conaghan PG**, O'Connor P, McGonagle D, *et al*. Elucidation of the relationship between synovitis and bone damage: a randomized magnetic resonance imaging study of individual joints in patients with early rheumatoid arthritis. *Arthritis Rheum* 2003;**48**:64–71.
55. **Lillegraven S**, Bøyesen P, Berner Hammer H, *et al*. Tenosynovitis of the extensor carpi ulnaris tendon predicts erosive progression in early rheumatoid arthritis. *Ann Rheum Dis* 2011;**70**:2049–50.
56. **Bøyesen P**, Haavardsholm EA, Østergaard M, *et al*. MRI in early rheumatoid arthritis: synovitis and bone marrow oedema are independent predictors of subsequent radiographic progression. *Ann Rheum Dis* 2011;**70**:428–33.
57. **McQueen F**, Beckley V, Crabbe J, *et al*. Magnetic resonance imaging evidence of tendinopathy in early rheumatoid arthritis predicts tendon rupture at six years. *Arthritis Rheum* 2005;**52**:744–51.
58. **Hoving JL**, Buchbinder R, Hall S, *et al*. A comparison of magnetic resonance imaging, sonography, and radiography of the hand in patients with early rheumatoid arthritis. *J Rheumatol* 2004;**31**:663–75.
59. **Kamishima T**, Tanimura K, Shimizu M, *et al*. Monitoring anti-interleukin 6 receptor antibody treatment for rheumatoid arthritis by quantitative magnetic resonance imaging of the hand and power Doppler ultrasonography of the finger. *Skeletal Radiol* 2011;**40**:745–55.
60. **Lindgaard HM**, Valløe J, Hørslev-Petersen K, *et al*. Low-cost, low-field dedicated extremity magnetic resonance imaging in early rheumatoid arthritis: a 1-year follow-up study. *Ann Rheum Dis* 2006;**65**:1208–12.
61. **Mundwiler ML**, Maranian P, Brown DH, *et al*. The utility of MRI in predicting radiographic erosions in the metatarsophalangeal joints of the rheumatoid foot: a prospective longitudinal cohort study. *Arthritis Res Ther* 2009;**11**:R94.
62. **McQueen FM**, Benton N, Crabbe J, *et al*. What is the fate of erosions in early rheumatoid arthritis? Tracking individual lesions using x rays and magnetic resonance imaging over the first two years of disease. *Ann Rheum Dis* 2001;**60**:859–68.
63. **Courvoisier N**, Dougados M, Cantagrel A, *et al*. Prognostic factors of 10-year radiographic outcome in early rheumatoid arthritis: a prospective study. *Arthritis Res Ther* 2008;**10**:R106.
64. **Dixey J**, Solymossy C, Young A. Is it possible to predict radiological damage in early rheumatoid arthritis (RA)? A report on the occurrence, progression, and prognostic factors of radiological erosions over the first 3 years in 866 patients from the early RA study (ERAS). *J Rheumatol* 2004;**31**:48–54.
65. **Markatseli TE**, Voulgari PV, Alamanos Y, *et al*. Prognostic factors of radiological damage in rheumatoid arthritis: a 10-year retrospective study. *J Rheumatol* 2011;**38**:44–52.
66. **Hoff M**, Haugeberg G, Ødegård S, *et al*. Cortical hand bone loss after 1 year in early rheumatoid arthritis predicts radiographic hand joint damage at 5-year and 10-year follow-up. *Ann Rheum Dis* 2009;**68**:324–9.
67. **Kapetanovic MC**, Lindqvist E, Alguin J, *et al*. Early changes in bone mineral density measured by digital X-ray radiogrammetry predict up to 20 years radiological outcome in rheumatoid arthritis. *Arthritis Res Ther* 2011;**13**:R31.
68. **Zhang J**, Redden DT, McGwin G, *et al*. Generalized bone loss as a predictor of three-year radiographic damage in African American patients with recent-onset rheumatoid arthritis. *Arthritis Rheum* 2010;**62**:2219–26.
69. **Möttönen TT**, Hannonen P, Toivanen J, *et al*. Value of joint scintigraphy in the prediction of erosiveness in early rheumatoid arthritis. *Ann Rheum Dis* 1988;**47**:183–9.
70. **de Bois MH**, Westedt ML, Arndt JW, *et al*. Value of ^{99m}Tc-IgG scintigraphy in the prediction of joint destruction in patients with rheumatoid arthritis of recent onset. *Rheumatol Int* 1995;**15**:155–8.
71. **Palosaari K**, Vuotila J, Takalo R, *et al*. Bone oedema predicts erosive progression on wrist MRI in early RA—a 2-yr observational MRI and NC scintigraphy study. *Rheumatology (Oxford)* 2006;**45**:1542–8.
72. **Ellegaard K**, Christensen R, Torp-Pedersen S, *et al*. Ultrasound Doppler measurements predict success of treatment with anti-TNF- α drug in patients with rheumatoid arthritis: a prospective cohort study. *Rheumatology (Oxford)* 2011;**50**:506–12.
73. **Elzinga EH**, Van Der Laken CJ, Comans EFL, *et al*. ¹⁸F-FDG PET as a tool to predict the clinical outcome of infliximab treatment of rheumatoid arthritis: an explorative study. *J Nucl Med* 2011;**52**:77–80.
74. **Wakefield RJ**, O'Connor PJ, Conaghan PG, *et al*. Finger tendon disease in untreated early rheumatoid arthritis: a comparison of ultrasound and magnetic resonance imaging. *Arthritis Care Res* 2007;**57**:1158–64.
75. **Ejbjerg BJ**, Narvestad E, Jacobsen S, *et al*. Optimised, low cost, low field dedicated extremity MRI is highly specific and sensitive for synovitis and bone erosions in rheumatoid arthritis wrist and finger joints: comparison with conventional high field MRI and radiography. *Ann Rheum Dis* 2005;**64**:1280–7.
76. **Schirmer C**, Scheel AK, Althoff CE, *et al*. Diagnostic quality and scoring of synovitis, tenosynovitis and erosions in low-field MRI of patients with rheumatoid arthritis: a comparison with conventional MRI. *Ann Rheum Dis* 2007;**66**:522–9.
77. **Freeston JE**, Brown AK, Hensor EMA, *et al*. Extremity magnetic resonance imaging assessment of synovitis (without contrast) in rheumatoid arthritis may be less accurate than power Doppler ultrasound. *Ann Rheum Dis* 2008;**67**:1351.
78. **Palosaari K**, Vuotila J, Takalo R, *et al*. Contrast-enhanced dynamic and static MRI correlates with quantitative ^{99m}Tc-labelled nanocolloid scintigraphy. Study of early rheumatoid arthritis patients. *Rheumatology (Oxford)* 2004;**43**:1364–73.
79. **Haavardsholm EA**, Østergaard M, Ejbjerg BJ, *et al*. Reliability and sensitivity to change of the OMERACT rheumatoid arthritis magnetic resonance imaging score in a multireader, longitudinal setting. *Arthritis Rheum* 2005;**52**:3860–7.
80. **Naredo E**, Möller I, Cruz A, *et al*. Power Doppler ultrasonographic monitoring of response to anti-tumor necrosis factor therapy in patients with rheumatoid arthritis. *Arthritis Rheum* 2008;**58**:2248–56.
81. **Ziswiler HR**, Aeberli D, Villier PM, *et al*. High-resolution ultrasound confirms reduced synovial hyperplasia following rituximab treatment in rheumatoid arthritis. *Rheumatology (Oxford)* 2009;**48**:939–43.
82. **Klauser A**, Demharter J, De Marchi A, *et al*. Contrast enhanced gray-scale sonography in assessment of joint vascularity in rheumatoid arthritis: results from the IACUS study group. *Eur Radiol* 2005;**15**:2404–10.
83. **Dohn UM**, Ejbjerg BJ, Court-Payen M, *et al*. Are bone erosions detected by magnetic resonance imaging and ultrasonography true erosions? A comparison with computed tomography in rheumatoid arthritis metacarpophalangeal joints. *Arthritis Res Ther* 2006;**8**:R110.
84. **Baillet A**, Gaujoux-Viala C, Mouterde G. Comparison of the efficacy of sonography, magnetic resonance imaging and conventional radiography for the detection of bone erosions in rheumatoid arthritis patients: a systematic review and meta-analysis. *Rheumatology (Oxford)* 2011;**50**:1137–47.

85. **Døhn UM**, Ejbjerg BJ, Hasselquist M, *et al.* Detection of bone erosions in rheumatoid arthritis wrist joints with magnetic resonance imaging, computed tomography and radiography. *Arthritis Res Ther* 2008;**10**:R25.
86. **Døhn UM**, Ejbjerg BJ, Hasselquist M, *et al.* Rheumatoid arthritis bone erosion volumes on CT and MRI: reliability and correlations with erosion scores on CT, MRI and radiography. *Ann Rheum Dis* 2007;**66**:1388–92.
87. **Perry D**, Stewart N, Benton N, *et al.* detection of erosions in the rheumatoid hand; a comparative study of multidetector computerized tomography versus magnetic resonance scanning. *J Rheumatol* 2005;**32**:256–67.
88. **Canella C**, Philippe P, Pansini V, *et al.* Use of tomosynthesis for erosion evaluation in rheumatoid arthritic hands and wrists. *Radiology* 2010;**258**:199–205.
89. **Corvetta A**, Giovagnoni A, Baldelli S, *et al.* MR imaging of rheumatoid hand lesions: comparison with conventional radiology in 31 patients. *Clin Exp Rheumatol* 1992;**10**:217–22.
90. **Duer-Jensen A**, Vestergaard A, Døhn UM, *et al.* Detection of rheumatoid arthritis bone erosions by two different dedicated extremity MRI units and conventional radiography. *Ann Rheum Dis* 2008;**67**:998–1003.
91. **Freeston JE**, Conaghan PG, Dass S, *et al.* Does extremity-MRI improve erosion detection in severely damaged joints? A study of long-standing rheumatoid arthritis using three imaging modalities. *Ann Rheum Dis* 2007;**66**:1538–40.
92. **Gaylis NB**, Needell SD, Rudensky D, *et al.* Comparison of in-office magnetic resonance imaging versus conventional radiography in detecting changes in erosions after one year of infliximab therapy in patients with rheumatoid arthritis. *Mod Rheumatol* 2007;**17**:273–8.
93. **Klarlund M**, Østergaard M, Gideon P, *et al.* Wrist and finger joint MR imaging in rheumatoid arthritis. *Acta Radiol* 1999;**40**:400–9.
94. **McQueen FM**, Stewart N, Crabbe J, *et al.* Magnetic resonance imaging of the wrist in early rheumatoid arthritis reveals a high prevalence of erosions at four months after symptom onset. *Ann Rheum Dis* 1998;**57**:350–6.
95. **Taouli B**, Zaim S, Peterfy CG, *et al.* Rheumatoid arthritis of the hand and wrist: comparison of three imaging techniques. *AJR Am J Roentgenol* 2004;**182**:937–43.
96. **Magnani M**, Salizzoni E, Mulè R, *et al.* Ultrasonography detection of early bone erosions in the metacarpophalangeal joints of patients with rheumatoid arthritis. *Clin Exp Rheumatol* 2004;**22**:743–8.
97. **Ciechomska A**, Andrysiak R, Serafin-Król M, *et al.* Ultrasonography, magnetic resonance imaging and conventional radiography of bone erosions in rheumatoid arthritis—a comparative study. *Rheumatologia* 2005;**43**:301–9.
98. **Rahmani M**, Chegini H, Najafizadeh SR, *et al.* Detection of bone erosion in early rheumatoid arthritis: ultrasonography and conventional radiography versus non-contrast magnetic resonance imaging. *Clin Rheumatol* 2010;**29**:883–91.
99. **Scheel AK**, Hermann K-GA, Ohndorf S, *et al.* Prospective 7 year follow up imaging study comparing radiography, ultrasonography, and magnetic resonance imaging in rheumatoid arthritis finger joints. *Ann Rheum Dis* 2006;**65**:595–600.
100. **Wakefield RJ**, Gibbon WW, Conaghan PG, *et al.* The value of sonography in the detection of bone erosions in patients with rheumatoid arthritis: a comparison with conventional radiography. *Arthritis Rheum* 2000;**43**:2762–70.
101. **Weidekamm C**, Köller M, Weber M, *et al.* Diagnostic value of high-resolution B-mode and Doppler sonography for imaging of hand and finger joints in rheumatoid arthritis. *Arthritis Rheum* 2003;**48**:325–33.
102. **Sheane BJ**, Beddy P, O'Connor M, *et al.* Targeted ultrasound of the fifth metatarsophalangeal joint in an early inflammatory arthritis cohort. *Arthritis Care Res* 2009;**61**:1004–8.
103. **Swen WAA**, Jacobs JWG, Hubach PCG, *et al.* Comparison of sonography and magnetic resonance imaging for the diagnosis of partial tears of finger extensor tendons in rheumatoid arthritis. *Rheumatology (Oxford)* 2000;**39**:55–62.
104. **Bruyn GAW**, Naredo E, Möller I, *et al.* Reliability of ultrasonography in detecting shoulder disease in patients with rheumatoid arthritis. *Ann Rheum Dis* 2009;**68**:357–61.
105. **Lindqvist E**, Jonsson K, Saxne T, *et al.* Course of radiographic damage over 10 years in a cohort with early rheumatoid arthritis. *Ann Rheum Dis* 2003;**62**:611–16.
106. **Østergaard M**, Hansen M, Stoltenberg M, *et al.* New radiographic bone erosions in the wrists of patients with rheumatoid arthritis are detectable with magnetic resonance imaging a median of two years earlier. *Arthritis Rheum* 2003;**48**:2128–31.
107. **Paimela L**, Laasonen L, Helve T, *et al.* Comparison of the original and the modified Larsen methods and the sharp method in scoring radiographic progression in early rheumatoid arthritis. *J Rheumatol* 1998;**25**:1063–6.
108. **Fezoulidis I**, Neuhold A, Wicke L, *et al.* Diagnostic imaging of the occipito-cervical junction in a patients with rheumatoid arthritis. *Eur J Radiol* 1989;**9**:5–11.
109. **Jacobsen EA**, Riise T. MRI of cervical spine with flexion and extension used in patients with rheumatoid arthritis. *Scand J Rheumatol* 2000;**29**:249–54.
110. **Karhu JO**, Parkkola RK, Koskinen SK. Evaluation of flexion/extension of the upper cervical spine in patients with rheumatoid arthritis: an MRI study with a dedicated positioning device compared to conventional radiographs. *Acta Radiol* 2005;**46**:55–66.
111. **Kauppi M**, Neva MH. Sensitivity of lateral view cervical spine radiographs taken in the neutral position in atlantoaxial subluxation in rheumatic diseases. *Clin Rheumatol* 1998;**17**:511–14.
112. **Oostveen JCM**, Roozeboom AR, van de Laar MAFJ, *et al.* Functional turbo spin echo magnetic resonance imaging versus tomography for evaluating cervical spine involvement in rheumatoid arthritis. *Spine* 1998;**23**:1237–44.
113. **Reijnierse M**, Breedveld FC, Kroon HM, *et al.* Are magnetic resonance flexion views useful in evaluating the cervical spine of patients with rheumatoid arthritis? *Skeletal Radiol* 2000;**29**:85–9.
114. **Richards JS**, Kerr GS, Nashel DJ. Odontoid erosions in rheumatoid arthritis: utility of the open mouth view. *J Clin Rheumatol* 2000;**6**:309–12.
115. **Shimada H**, Abematsu M, Ishiso Y, *et al.* Classification of odontoid destruction in patients with rheumatoid arthritis using reconstructed computed tomography: reference to vertical migration. *J Rheumatol* 2011;**38**:863–7.
116. **Stiskal MA**, Neuhold A, Szolar OH, *et al.* Rheumatoid arthritis of the craniocervical region by MR imaging: detection and characterization. *AJR Am J Roentgenol* 1995;**165**:585–92.
117. **Younes M**, Belghali S, Kriâa S, *et al.* Compared imaging of the rheumatoid cervical spine: prevalence study and associated factors. *Joint Bone Spine* 2009;**76**:361–8.
118. **Yurube T**, Sumi M, Nishida K, *et al.* Progression of cervical spine instabilities in rheumatoid arthritis: a prospective cohort study of outpatients over 5 years. *Spine* 2011;**36**:647–53.
119. **Aisen AM**, Martel W, Ellis JH, *et al.* Cervical spine involvement in rheumatoid arthritis: MR imaging. *Radiology* 1987;**165**:159–63.
120. **Reijnierse M**, Dijkman BA, Hansen B, *et al.* Neurologic dysfunction in patients with rheumatoid arthritis of the cervical spine. Predictive value of clinical, radiographic and MR imaging parameters. *Eur Radiol* 2001;**11**:467–73.
121. **Saleem B**, Brown AK, Keen H, *et al.* Should imaging be a component of rheumatoid arthritis remission criteria? A comparison between traditional and modified composite remission scores and imaging assessments. *Ann Rheum Dis* 2011;**70**:792–8.
122. **Ozgocmen S**, Ozdemir H, Kiris A, *et al.* Clinical evaluation and power Doppler sonography in rheumatoid arthritis: evidence for ongoing synovial inflammation in clinical remission. *South Med J* 2008;**101**:240–5.
123. **Wakefield RJ**, Freeston JE, Hensor EMA, *et al.* Delay in imaging versus clinical response: a rationale for prolonged treatment with anti-tumor necrosis factor medication in early rheumatoid arthritis. *Arthritis Rheum* 2007;**57**:1564–7.
124. **Brown AK**, Quinn MA, Karim Z, *et al.* Presence of significant synovitis in rheumatoid arthritis patients with disease-modifying antirheumatic drug-induced clinical remission: evidence from an imaging study may explain structural progression. *Arthritis Rheum* 2006;**54**:3761–73.
125. **Gandjbakhch F**, Conaghan PG, Ejbjerg B, *et al.* Synovitis and osteitis are very frequent in rheumatoid arthritis clinical remission: results from an MRI study of 294 patients in clinical remission or low disease activity state. *J Rheumatol* 2011;**38**:2039–44.
126. **Tishler M**, Lysy O, Levy O, *et al.* ^{99m}Tc-albumin nanocolloid joint scintigraphy in rheumatoid arthritis patients who are in clinical remission—is remission real? *Clin Exp Rheumatol* 2010;**28**:360–4.
127. **Brown AK**, Conaghan PG, Karim Z, *et al.* An explanation for the apparent dissociation between clinical remission and continued structural deterioration in rheumatoid arthritis. *Arthritis Rheum* 2008;**58**:2958–67.
128. **Peluso G**, Michelutti A, Bosello S, *et al.* Clinical and ultrasonographic remission determines different chances of relapse in early and long standing rheumatoid arthritis. *Ann Rheum Dis* 2011;**70**:172–5.
129. **Scirè CA**, Montecucco C, Codullo V, *et al.* Ultrasonographic evaluation of joint involvement in early rheumatoid arthritis in clinical remission: power Doppler signal predicts short-term relapse. *Rheumatology (Oxford)* 2009;**48**:1092–7.
130. **Varsamidis K**, Varsamidou E, Tjetjis V, *et al.* Doppler sonography in assessing disease activity in rheumatoid arthritis. *Ultrasound Med Biol* 2005;**31**:739–43.
131. **Mäkinen H**, Kautiainen H, Hannonen P, *et al.* Sustained remission and reduced radiographic progression with combination disease modifying antirheumatic drugs in early rheumatoid arthritis. *J Rheumatol* 2007;**34**:316–21.
132. **Molenaar ETH**, Voskuyl AE, Dinant HJ, *et al.* Progression of radiologic damage in patients with rheumatoid arthritis in clinical remission. *Arthritis Rheum* 2004;**50**:36–42.
133. **Lillegraven S**, Prince FHM, Shadick NA, *et al.* Remission and radiographic outcome in rheumatoid arthritis: application of the 2011 ACR/EULAR remission criteria in an observational cohort. *Ann Rheum Dis* 2012;**71**:681–6.
134. **Lillegraven S**, van der Heijde D, Uhlig T, *et al.* What is the clinical relevance of erosions and joint space narrowing in RA? *Nat Rev Rheumatol* 2012;**8**:117–20.

SUPPLEMENTARY MATERIAL

S1. Research questions

Making a diagnosis of rheumatoid arthritis

Q1- What is the evidence for the differential diagnostic value of individual imaging modalities for RA?

Q2- What is the evidence for the diagnostic value above clinical criteria of individual imaging modalities for RA

Detecting inflammation and damage

Q3- What is the evidence for the added value (sensitivity, specificity etc) of individual imaging modalities in detecting inflammation (synovitis, tenosynovitis, osteitis, bursitis, enthesitis) above clinical evaluation?

Q4- What is the evidence of the added value above clinical examination for the comparative value (sensitivity, specificity etc) of individual imaging modalities in detecting tissue damage (bone, cartilage, tendons, ligaments)?

Predicting prognosis in RA: Outcome

Q5- What is the evidence for the prognostic (prediction of outcome) value of individual imaging modalities for RA?

Q6- What is the evidence for the prognostic (prediction of outcome) value above other known prognostic markers of individual imaging modalities for RA?

(Outcome: activity, damage, QoI, HAQ, mortality, surgery, HE, cumulative/AUC/temporal change)

Predicting prognosis in RA: Response to treatment

Q7- What is the evidence for the prognostic (prediction of therapeutic response) value of individual imaging modalities for RA?

Q8- What is the evidence for the prognostic (prediction of therapeutic response) value above other known prognostic markers of individual imaging modalities for RA?

(Outcome: activity, damage, QoL, HAQ, mortality, surgery, HE, cumulative/AUC/temporal change)

Monitoring disease progression

Q9- When (time and under what clinical circumstances), where (which joints), how (modality specifics) and how often, and with what imaging modality should we monitor RA disease inflammation?

Q10- When (time and under what clinical circumstances), where (which joints), how (modality specifics) and how often, and with what imaging modality should we monitor RA disease damage?

Q11- When (time and under what clinical circumstances), where (which joints), how (modality specifics) how often, and with what imaging modality do we need to image the spine in RA?

Imaging in clinical remission

Q12- What is the relationship between individual imaging modalities and clinical remission in RA?

Q13- What is the impact with respect to outcome of imaging-detected inflammation /damage in the patient in clinical remission?

S2. Details of search strategy performed using EMBASE (1980 to June 2011); MEDLINE (1948 to June 2011); and the Cochrane Central Register of Controlled Trials (CENTRAL, The Cochrane Library, second quarter 2011) without language restrictions. The Cochrane Database of Systematic Reviews (CDSR) and the Database of Abstracts of Reviews of Effects (DARE) were also searched to ensure all potential studies were identified.

Search strategy, MEDLINE

1. exp arthritis, rheumatoid/
2. ((rheumat\$ or reumat\$) adj3 (arthrit\$ or artrit\$ or diseas\$ or condition\$ or nodule\$)).tw.
3. 1 or 2
4. Diagnostic Imaging/
5. Radiography/
6. exp Magnetic Resonance Imaging/
7. magnetic resonance.tw.
8. mri\$.tw.
9. exp Ultrasonography/
10. (ultrasonic adj (diagnos\$ or tomography or imaging\$)).tw.
11. echotomograph\$.tw.
12. echograph\$.tw.
13. ultrasonography\$.tw.
14. ultrasound.tw.
15. sonograph\$.tw.
16. exp Tomography, X-Ray Computed/
17. exp Contrast Media/
18. computed adj2 tomography.tw.
19. cat scan\$.tw.
20. ct.tw.
21. X-Rays/
22. xray\$.tw.

23. (roentgen adj ray\$.tw.
24. Absorptiometry, Photon/
25. Absorptiometr\$.tw.
26. ((dxa or dxa) adj scan\$.tw.
27. radiogram\$.tw.
28. dxr.tw.
29. Radionuclide Imaging/
30. (Scintigraph\$ or scintiphotograph\$.tw.
31. ((gamma camera or radionuclide) adj imag\$.tw.
32. radioisotope scan\$.tw.
33. Positron-Emission Tomography/
34. Positron emission tomograp\$.tw.
35. pet scan\$.tw.
36. or/4-35
37. 3 and 36
38. randomized controlled trial.pt.
39. controlled clinical trial.pt.
40. randomized.ab.
41. placebo.ab.
42. drug therapy.fs.
43. randomly.ab.
44. trial.ab.
45. groups.ab.
46. or/38-45
47. (animals not (humans and animals)).sh.
48. 46 not 47
49. 37 and 48
50. exp cohort studies/
51. cohort\$.tw.
52. controlled clinical trial.pt.

53. epidemiologic methods/
54. limit 53 to yr=1966-1989
55. exp case-control studies/
56. (case\$ and control\$).tw.
57. or/50-52,54-56
58. 37 and 57
59. ("review" or "review academic" or "review tutorial").pt.
60. (medline or medlars or embase or pubmed).tw,sh.
61. (scisearch or psychinfo or psycinfo).tw,sh.
62. (psychlit or psyclit).tw,sh.
63. cinahl.tw,sh.
64. ((hand adj2 search\$) or (manual\$ adj2 search\$)).tw,sh.
65. (electronic database\$ or bibliographic database\$ or computeri?ed database\$ or online database\$).tw,sh.
66. (pooling or pooled or mantel haenszel).tw,sh.
67. (retraction of publication or retracted publication).pt.
68. (peto or dersimonian or der simonian or fixed effect).tw,sh.
69. or/60-68
70. 59 and 69
71. meta-analysis.pt.
72. meta-analysis.sh.
73. (meta-analys\$ or meta analys\$ or metaanalys\$).tw,sh.
74. (systematic\$ adj5 review\$).tw,sh.
75. (systematic\$ adj5 overview\$).tw,sh.
76. (quantitativ\$ adj5 review\$).tw,sh.
77. (quantitativ\$ adj5 overview\$).tw,sh.
78. (quantitativ\$ adj5 synthesis\$).tw,sh.
79. (methodologic\$ adj5 review\$).tw,sh.
80. (methodologic\$ adj5 overview\$).tw,sh.
81. (integrative research review\$ or research integration).tw.

82. or/71-81

83. 37 and 82

84. limit 37 to "diagnosis (best balance of sensitivity and specificity)"

85. or/49,58,83-84

Search strategy, EMBASE

1. exp rheumatoid arthritis/

2. ((rheumat\$ or reumat\$) adj3 (arthrit\$ or artrit\$ or diseas\$ or condition\$ or nodule\$)).tw.

3. 1 or 2

4. diagnostic imaging/

5. radiography/

6. exp nuclear magnetic resonance imaging/

7. magnetic resonance.tw.

8. mri\$.tw.

9. exp echography/

10. (ultrasonic adj (diagnos\$ or tomography or imaging\$)).tw.

11. echotomograph\$.tw.

12. echograph\$.tw.

13. ultrasonography\$.tw.

14. ultrasound.tw.

15. sonograph\$.tw.

16. exp computer assisted tomography/

17. exp contrast medium/

18. (computed adj2 tomography).tw.

19. cat scan\$.tw.

20. ct.tw.

21. X ray/

22. xray\$.tw.

23. (roentgen adj ray\$).tw.

24. photon absorptiometry/

25. Absorptiometr\$.tw.
26. ((dxa or dxa) adj scan\$.tw.
27. radiogram\$.tw.
28. dxr.tw.
29. scintiscanning/
30. (Scintigraph\$ or scintiphotograph\$.tw.
31. ((gamma camera or radionuclide) adj imag\$.tw.
32. radioisotope scan\$.tw.
33. positron emission tomography/
34. Positron emission tomograp\$.tw.
35. pet scan\$.tw.
36. or/4-35
37. 3 and 36
38. (random\$ or placebo\$.ti,ab.
39. ((single\$ or double\$ or triple\$ or treble\$) and (blind\$ or mask\$)).ti,ab.
40. controlled clinical trial\$.ti,ab.
41. RETRACTED ARTICLE/
42. or/38-41
43. (animal\$ not human\$.sh,hw.
44. 42 not 43
45. 37 and 44
46. exp cohort analysis/
47. exp longitudinal study/
48. exp prospective study/
49. exp follow up/
50. cohort\$.tw.
51. exp case control study/
52. (case\$ and control\$.tw.
53. or/46-52
54. 37 and 53

55. exp review/
56. (literature adj3 review\$).ti,ab.
57. exp meta analysis/
58. exp "Systematic Review"/
59. or/55-58
60. (medline or medlars or embase or pubmed or cinahl or amed or psychlit or psyclit or psychinfo or psycinfo or scisearch or cochrane).ti,ab.
61. RETRACTED ARTICLE/
62. 60 or 61
63. 59 and 62
64. (systematic\$ adj2 (review\$ or overview)).ti,ab.
65. (meta?anal\$ or meta anal\$ or meta-anal\$ or metaanal\$ or metanal\$).ti,ab.
66. or/63-65
67. 37 and 66
68. limit 37 to "diagnosis (best balance of sensitivity and specificity)"
69. or/45,54,67-68

Search strategy, The Cochrane Library

- #1 MeSH descriptor Arthritis, Rheumatoid explode all trees
- #2 ((rheumat* or reumat*) near/3 (arthrit* or artrit* or diseas* or condition* or nodule*)):ti,ab
- #3 (#1 OR #2)
- #4 MeSH descriptor Diagnostic Imaging, this term only
- #5 MeSH descriptor Radiography, this term only
- #6 MeSH descriptor Magnetic Resonance Imaging explode all trees
- #7 "magnetic resonance":ti,ab
- #8 mri*:ti,ab
- #9 MeSH descriptor Ultrasonography explode all trees
- #10 (ultrasonic next (diagnos* or tomography or imaging*)):ti,ab
- #11 echotomograph*:ti,ab

- #12 echograph*:ti,ab
- #13 ultrasonography:ti,ab
- #14 ultrasound:ti,ab
- #15 sonograph*:ti,ab
- #16 MeSH descriptor Tomography, X-Ray Computed explode all trees
- #17 MeSH descriptor Contrast Media explode all trees
- #18 "computed tomography":ti,ab
- #19 "Cat scan*":ti,ab
- #20 ct:ti,ab
- #21 MeSH descriptor X-Rays, this term only
- #22 xray*:ti,ab
- #23 (roentgen next ray*):ti,ab
- #24 MeSH descriptor Absorptiometry, Photon, this term only
- #25 Absorptiometr*:ti,ab
- #26 ((dxa or dexta) next scan*):ti,ab
- #27 radiogram*:ti,ab
- #28 dxr:ti,ab
- #29 MeSH descriptor Radionuclide Imaging, this term only
- #30 (Scintigraph* or scintiphotograph*):ti,ab
- #31 ((gamma camera or radionuclide) next imag*):ti,ab
- #32 "radioisotope scan*":ti,ab
- #33 MeSH descriptor Positron-Emission Tomography, this term only
- #34 "Positron emission tomograp*":ti,ab
- #35 "pet scan*":ti,ab
- #36 (#4 OR #5 OR #6 OR #7 OR #8 OR #9 OR #10 OR #11 OR #12 OR #13 OR #14 OR
#15 OR #16 OR #17 OR #18 OR #19 OR #20 OR #21 OR #22 OR #23 OR #24 OR #25 OR
#26 OR #27 OR #28 OR #29 OR #30 OR #31 OR #32 OR #33 OR #34 OR #35)
- #37 (#3 AND #36)

Figure S3. Flowchart showing the literature search of 6888 articles, from which 346 articles were selected for detailed review; 199 articles met the inclusion criteria.

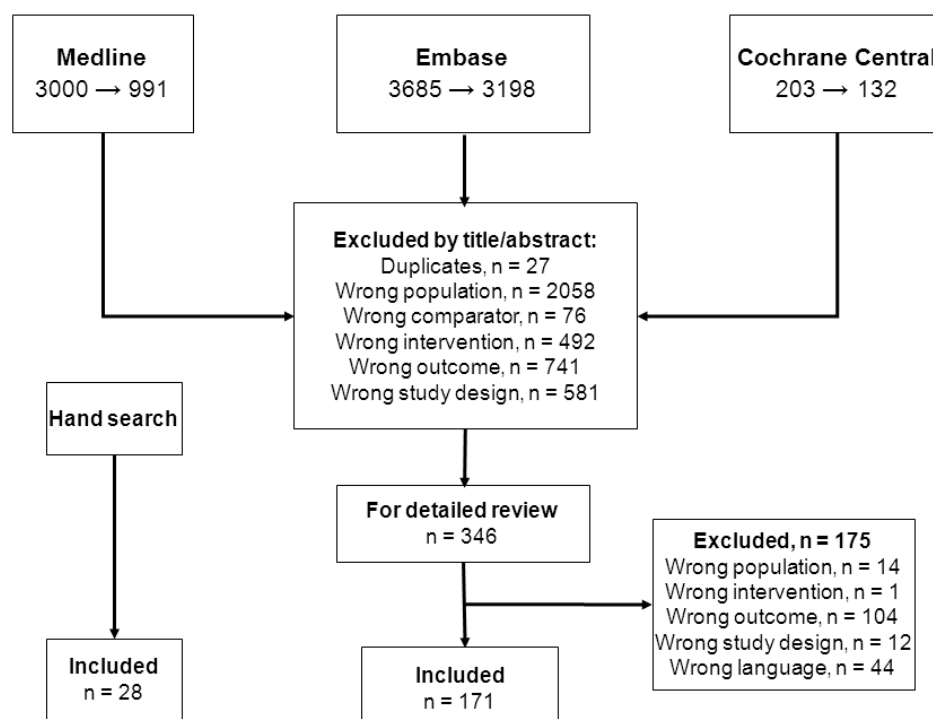


Table S4. Number of included articles per question

	Number of included articles
Q1- What is the evidence for the differential diagnostic value of individual imaging modalities for RA?	3
Q2- What is the evidence for the diagnostic value above clinical criteria of individual imaging modalities for RA?	15
Q3- What is the evidence for the added value (sensitivity , specificity etc) of individual imaging modalities in detecting inflammation (synovitis, tenosynovitis, osteitis, bursitis, enthesitis) above clinical evaluation?	51
Q4- What is the evidence of the added value above clinical examination for the comparative value (sensitivity, specificity etc) of individual imaging modalities in detecting tissue damage (bone, cartilage, tendons, ligaments)?	3
Q5- What is the evidence for the prognostic (prediction of outcome) value of individual imaging modalities for RA?	12
Q6- What is the evidence for the prognostic (prediction of outcome) value above other known prognostic markers of individual imaging modalities for RA?	38
Q7- What is the evidence for the prognostic (prediction of therapeutic response) value of individual imaging modalities for RA?	0
Q8- What is the evidence for the prognostic (prediction of therapeutic response) value above other known prognostic markers of individual imaging modalities for RA?	2
Q9- When (time and under what clinical circumstances), where (which joints), how (modality specifics) and how often, and with	23

what imaging modality should we monitor RA disease inflammation?	
Q10- When (time and under what clinical circumstances), where (which joints), how (modality specifics) and how often, and with what imaging modality should we monitor RA disease damage?	55
Q11- When (time and under what clinical circumstances), where (which joints), how (modality specifics) how often, and with what imaging modality do we need to image the spine in RA?	13
Q12- What is the relationship between individual imaging modalities and clinical remission in RA?	7
Q13- What is the impact with respect to outcome of imaging-detected inflammation /damage in the patient in clinical remission?	7

S5. Reference list of included articles per recommendation

Recommendation 1. (in patients with at least one joint with definite clinical synovitis)

When there is diagnostic doubt, conventional radiography, US or MRI can be used to improve the certainty of a diagnosis of RA above clinical criteria alone.

1. Agrawal S, Bhagat SS, Dasgupta B. Improvement in diagnosis and management of musculoskeletal conditions with one-stop clinic-based ultrasonography. *Mod Rheumatol* 2009;**19**:53-56.
2. Matsos MP, Khalidi N, Zia P, et al. Ultrasound of the hands and feet for rheumatological disorders: influence on clinical diagnostic confidence and patient management. *Skeletal Radiol* 2009;**38**:1049–1054.
3. Narváez J, Sirvent E, Narváez JA, et al. Usefulness of magnetic resonance imaging of the hand versus anticyclic citrullinated peptide antibody testing to confirm the diagnosis of clinically suspected early rheumatoid arthritis in the absence of rheumatoid factor and radiographic erosions. *Semin Arthritis Rheum* 2008;**38**:101-109.
4. Sugimoto H, Takeda A, Masuyama J, et al. Early-stage rheumatoid arthritis: diagnostic accuracy of MR imaging. *Radiology* 1996;**198**:185-192.
5. Sugimoto H, Takeda A, Hyodoh K. Early-stage rheumatoid arthritis: Prospective study of the effectiveness of MR imaging for diagnosis. *Radiology* 2000;**216**:569-575.

Recommendation 2. The presence of inflammation seen with US or MRI can be used to predict the progression to clinical RA from undifferentiated inflammatory arthritis

1. de Bois MHW, Arndt JW, Speyer I, et al. Technetium-99m labelled human immunoglobulin scintigraphy predicts rheumatoid arthritis in patients with arthralgia. *Scand J Rheumatol* 1996;**25**:155-158.

2. Duer A, Østergaard M, Hørslev-Petersen K, et al. Magnetic resonance imaging and bone scintigraphy in the differential diagnosis of unclassified arthritis. *Ann Rheum Dis* 2008;**67**:48-51.
3. Duer-Jensen A, Hørslev-Petersen K, Hetland ML, et al. MRI bone edema is an independent predictor of development of rheumatoid arthritis in patients with early undifferentiated arthritis. *Arthritis Rheum* 2011;**63**:2192–2202.
4. Eshed I, Feist E, Althoff CE, et al. Tenosynovitis of the flexor tendons of the hand detected by MRI: an early indicator of rheumatoid arthritis *Rheumatology (Oxford)* 2009;**48**:887-891.
5. Filer A, De Pablo P, Allen G, et al. Utility of ultrasound joint counts in the prediction of rheumatoid arthritis in patients with very early synovitis. *Ann Rheum Dis* 2011;**70**:500-507.
6. Mori G, Tokunaga D, Takahashi KA, et al. Maximum intensity projection as a tool to diagnose early rheumatoid arthritis. *Mod Rheumatol* 2008;**18**:247–251.
7. Ozgul A, Yasar E, Arslan N, et al. The comparison of ultrasonographic and scintigraphic findings of early arthritis in revealing rheumatoid arthritis according to criteria of American College of Rheumatology. *Rheumatol Int* 2009;**29**:765–768.
8. Petre MA, Cheng CK, Boire G, et al. Prognostic value of patient history, radiography and serology on poor outcomes in undifferentiated inflammatory arthritis patients (abstract). *Arthritis Rheum* 2009;**60 Suppl 10**:1191.
9. Salaffi F, Ciapetti A, Gasparini S, et al. A clinical prediction rule combining routine assessment and power Doppler ultrasonography for predicting progression to rheumatoid arthritis from early-onset undifferentiated arthritis. *Clin Exp Rheumatol* 2010;**28**: 686-694.

10. Solou-Gervais E, Legrand J-L, Cortet B, et al. Magnetic resonance imaging of the hand for the diagnosis of rheumatoid arthritis in the absence of anti-cyclic citrullinated peptide antibodies: a prospective study. *J Rheumatol* 2006;**33**:1760–1765.
11. Tamai M, Kawakami A, Uetani M, et al. A prediction rule for disease outcome in patients with undifferentiated arthritis using magnetic resonance imaging of the wrists and finger joints and serologic autoantibodies. *Arthritis Rheum* 2009;**61**, No. 6;772–778.
12. Zhang L, Li J, He W, et al. The prediction and evaluation of the progression to rheumatoid arthritis in 157 patients with undifferentiated arthritis (abstract). *Int J Rheum Dis* 2010;**13 Suppl 1**:0908.

Recommendation 3. US and MRI are superior to clinical examination in the detection of joint inflammation; these techniques should be considered for more accurate assessment of inflammation

1. Andonopoulos AP, Yarmenitis S, Sfountouris H, et al. Baker's cyst in rheumatoid arthritis: an ultrasonographic study with a high resolution technique. *Clin Exp Rheumatol* 1995;**13**:633-636.
2. Bajaj S, Lopez-Ben R, Oster R, Alarcón GS. Ultrasound detects rapid progression of erosive disease in early rheumatoid arthritis: a prospective longitudinal study. *Skeletal Radiol* 2007;**36**:123–128.
3. Batalov A, Kuzmanova S, Atanasov. Ultrasound follow-up study of arthroscoped patients with gonitis. *Folia Medica* 1999;**41**:63-70.
4. Beckers C, Ribbens C, André B, et al. Assessment of disease activity in rheumatoid arthritis with ¹⁸F-FDG PET. *J Nucl Med* 2004;**45**:956-964.

5. Calisir C, Murat Aynaci AI, Korkmaz C. The accuracy of magnetic resonance imaging of the hands and feet in the diagnosis of early rheumatoid arthritis. *Joint Bone Spine* 2007;**74**:362-7.
6. Carotti M, Salaffi F, Manganelli P, et al. Power Doppler sonography in the assessment of synovial tissue of the knee joint in rheumatoid arthritis: a preliminary experience. *Ann Rheum Dis* 2002;**61**:877-882.
7. Chávez-López MA, Naredo E, Acebes-Cachafeiro JC, et al. Diagnostic accuracy of physical examination of the knee in rheumatoid arthritis: Clinical and ultrasonographic study of joint effusion and Baker's cyst. *Reumatol Clin* 2007;**3**:98-100.
8. Cheung PP, Ruysse-Witrand A, Gossec L, et al. Reliability of patient self-evaluation of swollen and tender joints in rheumatoid arthritis: a comparison study with ultrasonography, physician, and nurse assessments. *Arthritis Care Res* 2010;**62**:1112-1119.
9. Cindaş A, Gökçe-Kutsal Y, Özgen Kirth P, et al. Scintigraphic evaluation of synovial inflammation in rheumatoid arthritis with ^{99m}Tc-labelled human polyclonal immunoglobulin G. *Rheumatol Int* 2001;**20**:71-77.
10. Damjanov N, Radunović G, Prodanović S, et al. Construct validity and reliability of ultrasound disease activity score in assessing joint inflammation in RA: comparison with DAS-28. *Rheumatology (Oxford)* 2012;**51**:120-128.
11. de Bois MH, Tak PP, Arndt JW, et al. Joint scintigraphy for quantification of synovitis with ^{99m}Tc-labelled human immunoglobulin G compared to histological examination. *Clin Exp Rheumatol* 1995;**13**:155-159.
12. Emery P, van der Heijde D, Østergaard M, et al. Exploratory analyses of the association of MRI with clinical, laboratory and radiographic findings in patients with rheumatoid arthritis. *Ann Rheum Dis* 2011;**70**:2126–2130.

13. Filippucci E, Iagnocco A, Salaffi F, et al. Power Doppler sonography monitoring of synovial perfusion at the wrist joints in patients with rheumatoid arthritis treated with adalimumab. *Ann Rheum Dis* 2006;**65**:1433-1437.
14. Forslind K, Johanson A, Larsson EM et al. Magnetic resonance imaging of the fifth metatarsophalangeal joint compared with conventional radiography in patients with early rheumatoid arthritis. *Scand J Rheumatol* 2003;**32**:131-137.
15. Forslind K, Larsson EM, Eberhardt K, et al. Magnetic resonance imaging of the knee: a tool for prediction of joint damage in early rheumatoid arthritis? *Scand J Rheumatol* 2004;**33**:154–161.
16. Goerres GW, Forster A, Uebelhart D, et al. F-18 FDG whole-body PET for the assessment of disease activity in patients with rheumatoid arthritis. *Clin Nucl Med* 2006;**31**: 386–390.
17. Goupille P, Roulot B, Akoka S, et al. Magnetic resonance imaging: a valuable method for the detection of synovial inflammation in rheumatoid arthritis. *J Rheumatol* 2001;**28**:35-40.
18. Haavardsholm EA, Ostergaard M, Hammer HB, et al. Monitoring anti-TNF alpha treatment in rheumatoid arthritis: responsiveness of magnetic resonance imaging and ultrasonography of the dominant wrist joint compared with conventional measures of disease activity and structural damage. *Ann Rheum Dis* 2009;**68**:1572-1579.
19. Hammer HB, Sveinsson M, Kongtorp AK, et al. A 78-joints ultrasonographic assessment is associated with clinical assessments and is highly responsive to improvement in a longitudinal study of patients with rheumatoid arthritis starting adalimumab treatment. *Ann Rheum Dis* 2010;**69**:1349–1351.
20. Hmamouchi I, Bahiri R, Srifi N, et al. A comparison of ultrasound and clinical examination in the detection of flexor tenosynovitis in early arthritis. *BMC Musculoskelet Disord* 2011;**12**:91.

21. Horikoshi M, Suzuki T, Sugihara M, et al. Comparison of low-field dedicated extremity magnetic resonance imaging with articular ultrasonography in patients with rheumatoid arthritis. *Mod Rheumatol* 2010;**20**:556-560.
22. Jamar F, Manicourt D-H, Leners N, et al. Evaluation of disease activity in rheumatoid arthritis and other arthritides using ^{99m}Tc-labelled nonspecific human immunoglobulin. *J Rheumatol* 1995;**22**:850-854.
23. Kane D, Balint PV, Sturrock RD, et al. Ultrasonography is superior to clinical examination in the detection and localization of knee joint effusion in rheumatoid arthritis. *J Rheumatol* 2003;**30**:966-971.
24. Kaya M, Tuna H, Fatih Firat M, et al. ^{99m}Tc-dextran scintigraphy to detect disease activity in patients with rheumatoid arthritis. *Nucl Med Commun* 2004;**25**:597-601.
25. Krejza J, Kuryliszyn-Moskal A, Sierakowski S, et al. Ultrasonography of the periarticular changes in patients with early active rheumatoid arthritis. *Med Sci Monit* 1998;**4**:366-369.
26. Luukkainen RK, Saltyshev M, Koski JM, et al. Relationship between clinically detected joint swelling and effusion diagnosed by ultrasonography in metatarsophalangeal and talocrural joints in patients with rheumatoid arthritis. *Clin Exp Rheumatol* 2003;**21**:632-634.
27. Luukainen R, Sanila MT, Saltyshev M, et al. Relationship between clinically detected joint swelling and effusion diagnosed by ultrasonography in elbow joints in patients with rheumatoid arthritis. *Clin Rheumatol* 2005;**24**:228-231.
28. Luukainen R, Sanila MT, Luukainen P. Poor relationship between joint swelling detected on physical examination and effusion diagnosed by ultrasonography in glenohumeral joints in patients with rheumatoid arthritis. *Clin Rheumatol* 2007;**26**:865-867.

29. Martins FPP, Gutfilen B, de Souza SAL, et al. Monitoring rheumatoid arthritis synovitis with ^{99m}Tc -anti-CD3. *B J Radiol* 2008;**81**:25–29.
30. Möttönen TT, Hannonen P, Toivanen J, et al. Scintigraphy of rheumatoid peripheral joints. Reliability of visual assessment vs. computerized methods. *Scand J Rheumatol* 1987;**16**:421-427.
31. Naredo E, Bonilla G, Gamero F, et al. Assessment of inflammatory activity in rheumatoid with grey scale and power Doppler ultrasonography arthritis: a comparative study of clinical evaluation. *Ann Rheum Dis* 2005;**64**:375-381.
32. Pons F, Moyá F, Herranz R, et al. Detection and quantitative analysis of joint activity inflammation with $^{99\text{Tc}}$ m-polyclonal human immunoglobulin G. *Nucl Med Commun* 1993;**14**:225-231.
33. Pons F, Sanmarti R, Herranz R, et al. Scintigraphic evaluation of the severity of inflammation of the joints with $^{99\text{Tc}}$ m-HIG in rheumatoid arthritis. *Nucl Med Commun* 1996;**17**:523-528.
34. Remans J, Berghs H, Drieskens L, et al. Proximal interphalangeal arthroscintigraphy in rheumatoid arthritis. *Ann Rheum Dis* 1978;**37**:440-443.
35. Ribbens C, André B, Marcelis S, et al. Rheumatoid hand joint synovitis: gray-scale and power Doppler US quantifications following anti-tumor necrosis factor- α treatment: pilot study. *Radiology* 2003;**229**:562–569.
36. Riente L, Delle Sedie A, Filippucci E, et al. Ultrasound Imaging for the rheumatologist XXVII. Sonographic assessment of the knee in patients with rheumatoid arthritis. *Clin Exp Rheumatol* 2010;**28**:300-303.
37. Riente L, Delle Sedie A, Scirè CA et al. Ultrasound imaging for the rheumatologist. XXXI. Sonographic assessment of the foot in patients with rheumatoid arthritis. *Clin Exp Rheumatol* 2011;**29**:1-5.

38. Roimicher L, Lopes FPPL, de Souza SAL, et al. ^{99m}Tc -anti-TNF- α scintigraphy in RA: a comparison pilot study with MRI and clinical examination. *Rheumatology (Oxford)* 2011;**50**:2044-2050.
39. Salaffi F, Filippucci E, Carotti M, et al. Inter-observer agreement of standard joint counts in early rheumatoid arthritis: a comparison with grey scale ultrasonography - a preliminary study. *Rheumatology (Oxford)* 2008;**47**:54–58.
40. Sewell KL, Ruthazer R, Parker JA. The correlation of indium-111 joint scans with clinical synovitis in rheumatoid arthritis. *J Rheumatol* 1993;**20**:2015-2019.
41. Shmerling RH, Parker JA, Johns WD, et al. Measurement of joint inflammation in rheumatoid arthritis with indium-111 chloride. *Ann Rheum Dis* 1990;**49**: 88-92.
42. Spiegel TM, King W, Weiner SR, et al. Measuring disease activity: comparison of joint tenderness, swelling, and ultrasonography in rheumatoid arthritis. *Arthritis Rheum* 1987;**30**:1283-1288.
43. Szkudlarek M, Court-Payen M, Strandberg C, et al. Power Doppler ultrasonography for assessment of synovitis in the metacarpophalangeal joints of patients with rheumatoid arthritis: a comparison with dynamic magnetic resonance imaging. *Arthritis Rheum* 2001;**44**:2018-2023.
44. Szkudlarek M, Jensen K, Thomsen H, et al. Ultrasonography of the metacarpophalangeal and proximal interphalangeal joints in rheumatoid arthritis: a comparison with magnetic resonance imaging, conventional radiography and clinical examination. *Arthritis Res Ther* 2006;**8**:R52.
45. Tamai M, Kawakami A, Iwamoto N, et al. Comparative study of the detection of joint injury in early-stage rheumatoid arthritis by magnetic resonance imaging of the wrist and finger joints and physical examination. *Arthritis Care Res* 2011;**63**:436–439.
46. Tannenbaum H, Rosenthal L. A prospective study comparing the clinical examination

of peripheral joints with radionuclide scintigraphy in patients with rheumatoid arthritis. *Clin Exp Rheumatol* 1987;**5**:11-16.

47. Terslev L, von der Recke P, Savnik A, et al. Diagnostic sensitivity and specificity of Doppler ultrasound in rheumatoid arthritis. *J Rheumatol* 2008;**35**:49-53.
48. Tonolli-Serabian I, Poet JL, Dufour M, et al. Magnetic resonance imaging of the wrist in rheumatoid arthritis: comparison with other inflammatory joint diseases and control subjects. *Clin Rheumatol* 1996;**15**:137-142.
49. Wakefield RJ, Freeston JE, O'Connor P, et al. The optimal assessment of the rheumatoid arthritis hindfoot: a comparative study of clinical examination, ultrasound and high field MRI. *Ann Rheum Dis* 2008;**67**:1678-1682.
50. Weissberg DL, Resnick D, Taylor A, et al. Rheumatoid arthritis and its variants: analysis of scintiphotographic, radiographic, and clinical examinations. *Am J Roentgenol* 1978;**131**:665-673.

Recommendation 4. Conventional radiography of the hands and feet should be used as the initial imaging technique to detect damage. However, US and/or MRI should be considered if conventional radiographs do not show damage and may be used to detect damage at an earlier time point (especially in early RA)

1. Bayar N, Altan Kara S, Keles I, et al. Temporomandibular joint involvement in rheumatoid arthritis: a radiological and clinical study. *Cranio* 2002;**20**:105-110.
2. Forslind K, Johanson A, Larsson EM et al. Magnetic resonance imaging of the fifth metatarsophalangeal joint compared with conventional radiography in patients with early rheumatoid arthritis. *Scand J Rheumatol* 2003;**32**:131-137.
3. Forslind K, Larsson EM, Eberhardt K, et al. Magnetic resonance imaging of the knee: a tool for prediction of joint damage in early rheumatoid arthritis? *Scand J Rheumatol* 2004;**33**:154–161.

Recommendation 5. MRI bone oedema is a strong independent predictor of subsequent radiographic progression in early RA and should be considered for use as a prognostic indicator. Joint inflammation (synovitis) detected by MRI or US as well as joint damage detected by conventional radiographs, MRI or US can also be considered for the prediction of further joint damage

1. Bansbank N, Young A, Brennan A, et al. A prognostic model for functional outcome in early rheumatoid arthritis. *J Rheumatol* 2006;**33**:1503–10.
2. Benton N, Stewart N, Crabbe J, et al. MRI of the wrist in early rheumatoid arthritis can be used to predict functional outcome at 6 years. *Ann Rheum Dis* 2004;**63**:555-561.
3. Bøyesen P, Haavardsholm EA, Østergaard M, et al. MRI in early rheumatoid arthritis: Synovitis and bone marrow oedema are independent predictors of subsequent radiographic progression. *Ann Rheum Dis* 2011;**70**:428-433.
4. Bøyesen P, Haavardsholm EA, van der Heijde D, et al. Prediction of MRI erosive progression: A comparison of modern imaging modalities in early rheumatoid arthritis patients. *Ann Rheum Dis* 2011;**70**:176-179.
5. Cavet G, Shen Y, Abraham S, et al. Predicting radiographic progression in rheumatoid arthritis with ultrasound and biomarkers (abstract). *Arthritis Rheum* 2009;**60 Suppl 10**:1464.
6. Conaghan PG, O'Connor P, McGonagle D, et al. Elucidation of the relationship between synovitis and bone damage: a randomized magnetic resonance imaging study of individual joints in patients with early rheumatoid arthritis. *Arthritis Rheum* 2003;**48**:64-71.
7. Coombe B, Dougados M, Goupille P, et al. Prognostic factors for radiographic damage in early rheumatoid arthritis: a multiparameter prospective study. *Arthritis Rheum* 2001;**44**:1736–1743.

8. Courvoisier N, Dougados M, Cantagrel A, et al. Prognostic factors of 10-year radiographic outcome in early rheumatoid arthritis: a prospective study. *Arthritis Res Ther* 2008;**10**:R106.
9. de Bois MH, Westedt ML, Arndt JW, et al. Value of ^{99m}Tc-IgG scintigraphy in the prediction of joint destruction in patients with rheumatoid arthritis of recent onset. *Rheumatol Int* 1995;**15**:155-158.
10. Dixey J, Solymossy C, Young A. Is it possible to predict radiological damage in early rheumatoid arthritis (RA)? A report on the occurrence, progression, and prognostic factors of radiological erosions over the first 3 years in 866 patients from the early RA study (ERAS). *J Rheumatol* 2004;**31**:48-54.
11. Dohn UM, Ejbjerg B, Boonen A, et al. No overall progression and occasional repair of erosions despite persistent inflammation in adalimumab-treated rheumatoid arthritis patients: Results from a longitudinal comparative MRI, ultrasonography, CT and radiography study. *Ann Rheum Dis* 2011;**70**:252-258.
12. Forslind K, Larsson EM, Eberhardt K, et al. Magnetic resonance imaging of the knee: a tool for prediction of joint damage in early rheumatoid arthritis? *Scand J Rheumatol* 2004;**33**:154–161.
13. Forslind K, Boonen A, Albertsson K, et al. Hand bone loss measured by digital X-ray radiogrammetry is a predictor of joint damage in early rheumatoid arthritis. *Scand J Rheumatol* 2009;**38**:431-438.
14. Gandjbakhch F, Foltz V, Mallet A, et al. Bone marrow oedema predicts structural progression in a 1-year follow-up of 85 patients with RA in remission or with low disease activity with low-field MRI. *Ann Rheum Dis* 2011;**70**:2159-2162.
15. Gossec L, Dougados M, Goupille P, et al. Prognostic factors for remission in early rheumatoid arthritis: a multiparameter prospective study. *Ann Rheum Dis* 2004;**63**:675–680.

16. Güler-Yüksel M, Klarenbeek NB, Yvonne PM Goekoop-Ruiterman YPM, et al. Accelerated hand bone mineral density loss is associated with progressive joint damage in hands and feet in recent-onset rheumatoid arthritis. *Arthritis Res Ther* 2010;**12**:R96.
17. Haavardsholm EA, Bøyesen P, Østergaard M, et al. Magnetic resonance imaging findings in 84 patients with early rheumatoid arthritis: Bone marrow oedema predicts erosive progression. *Ann Rheum Dis* 2008;**67**:794-800.
18. Hetland ML, Ejbjerg B, Hørslev-Petersen K, et al. MRI bone oedema is the strongest predictor of rheumatoid arthritis. Results from a 2-year randomised controlled trial (CIMESTRA). *Ann Rheum Dis* 2009;**68**:384-390.
19. Hetland ML, Stengaard-Pedersen K, Junker P, et al. Radiographic progression and remission rates in early rheumatoid arthritis – MRI bone oedema and anti-CCP predicted radiographic progression in the 5-year extension of the double-blind randomised CIMESTRA trial. *Ann Rheum Dis* 2010;**69**:1789–1795.
20. Hoff M, Haugeberg G, Ødegård S, et al. Cortical hand bone loss after 1 year in early rheumatoid arthritis predicts radiographic hand joint damage at 5-year and 10-year follow-up. *Ann Rheum Dis* 2009;**68**:324-329.
21. Hoving JL, Buchbinder R, Hall S, et al. A Comparison of magnetic resonance imaging, sonography, and radiography of the hand in patients with early rheumatoid arthritis. *J Rheumatol* 2004;**31**:663-675.
22. Huang J, Stewart N, Crabbe J, et al. A 1-year follow-up study of dynamic magnetic resonance imaging in early rheumatoid arthritis reveals synovitis to be increased in shared epitope-positive patients and predictive of erosions at 1 year. *Rheumatology (Oxford)* 2000;**39**:407-416.
23. Kamishima T, Tanimura K, Shimizu M, et al. Monitoring anti-interleukin 6 receptor antibody treatment for rheumatoid arthritis by quantitative magnetic resonance

imaging of the hand and power Doppler ultrasonography of the finger. *Skeletal Radiol* 2011;**40**:745-755.

24. Kapetanovic MC, Lindqvist E, Algulin J, et al. Early changes in bone mineral density measured by digital X-ray radiogrammetry predict up to 20 years radiological outcome in rheumatoid arthritis. *Arthritis Res Ther* 2011;**13**:R31.
25. Lillegraven S, Bøyesen P, Berner Hammer H, et al. Tenosynovitis of the extensor carpi ulnaris tendon predicts erosive progression in early rheumatoid arthritis. *Ann Rheum Dis* 2011;**70**:2049-50.
26. Lindegaard HM, Vallø J, Hørslev-Petersen K, et al. Low-cost, low-field dedicated extremity magnetic resonance imaging in early rheumatoid arthritis: a 1-year follow-up study. *Ann Rheum Dis* 2006;**65**:1208-1212.
27. Markatseli TE, Voulgari PV, Alamanos Y, et al. Prognostic factors of radiological damage in rheumatoid arthritis: a 10-year retrospective study. *J Rheumatol* 2011;**38**:44–52.
28. McQueen F, Beckley V, Crabbe J, et al. Magnetic resonance imaging evidence of tendinopathy in early rheumatoid arthritis predicts tendon rupture at six years. *Arthritis Rheum* 2005;**52**:744-751.
29. McQueen FM, Benton N, Crabbe J, et al. Bone edema scored on magnetic resonance imaging scans of the dominant carpus at presentation predicts radiographic joint damage of the hands and feet six years later in patients with rheumatoid arthritis. *Arthritis Rheum* 2003;**48**:1814–1827.
30. McQueen FM, Benton N, Crabbe J, et al. What is the fate of erosions in early rheumatoid arthritis? Tracking individual lesions using χ rays and magnetic resonance imaging over the first two years of disease. *Ann Rheum Dis* 2001;**60**:859-868.
31. McQueen FM, Stewart N, Crabbe J, et al. Magnetic resonance imaging of the wrist in

early rheumatoid arthritis reveals progression of erosions despite clinical improvement. *Ann Rheum Dis* 1999;**8**:156-163.

32. Möttönen TT, Hannonen P, Toivanen J, et al. Value of joint scintigraphy in the prediction of erosiveness in early rheumatoid arthritis. *Ann Rheum Dis* 1988;**47**:183-189.
33. Mundwiler ML, Maranian P, Brown DH, et al. The utility of MRI in predicting radiographic erosions in the metatarsophalangeal joints of the rheumatoid foot: a prospective longitudinal cohort study. *Arthritis Res Ther* 2009;**11**:R94.
34. Naredo E, Möller I, Cruz A, et al. Power Doppler ultrasonographic monitoring of response to anti-tumor necrosis factor therapy in patients with rheumatoid arthritis. *Arthritis Rheum* 2008;**58**:2248-2256.
35. Naredo E, Collado P, Cruz A, et al. Longitudinal power doppler ultrasonographic assessment of joint inflammatory activity in early rheumatoid arthritis: predictive value in disease activity and radiologic progression. *Arthritis Rheum* 2007;**57**:116–124.
36. Ornbjerg LM, Østergaard M, Boyesen, P, et al. Predictors of radiographic joint destruction in rheumatoid arthritis patients during TNF-inhibitor treatment in clinical practice (abstract). *Arthritis Rheum* 2009;**60 Suppl 10**:1000.
37. Østergaard M, Duer A, Nielsen H, et al. Magnetic resonance imaging for accelerated assessment of drug effect and prediction of subsequent radiographic progression in rheumatoid arthritis: a study of patients receiving combined anakinra and methotrexate treatment. *Ann Rheum Dis* 2005;**64**:1503–1506.
38. Østergaard M, Hansen M, Stoltenberg M, et al. New radiographic bone erosions in the wrists of patients with rheumatoid arthritis are detectable with magnetic resonance imaging a median of two years earlier. *Arthritis Rheum* 2003;**48**:2128-2131.
39. Østergaard M, Hansen M, Stoltenberg M, et al. Magnetic resonance imaging–

determined synovial membrane volume as a marker of disease activity and a predictor of progressive joint destruction in the wrists of patients with rheumatoid arthritis. *Arthritis Rheum* 1999;**42**:918–929.

40. Palosaari K, Vuotila J, Takalo R, et al. Bone oedema predicts erosive progression on wrist MRI in early RA - a 2-yr observational MRI and NC scintigraphy study. *Rheumatology (Oxford)* 2006;**45**:1542-1548.
41. Pascual-Ramos V, Contreras-Yañez I, Cabiedes-Contreras J, et al. Hypervascular synovitis and American College of Rheumatology classification criteria as predictors of radiographic damage in early rheumatoid arthritis. *Ultrasound Q* 2009;**25**:31-38.
42. Plant MJ, Saklatvala J, Borg, AA, et al. Measurement and prediction of radiological progression in early rheumatoid arthritis. *J Rheumatol* 1994;**21**:1808-1813.
43. Renesses S, González-Escribano MF, Fernández-Suárez A, et al. The value of HLA-DRB1 shared epitope, -308 tumor necrosis factor- α gene promoter polymorphism, rheumatoid factor, anti-citrullinated peptide antibodies, and early erosions for predicting radiological outcome in recent-onset rheumatoid arthritis. *J Rheumatol* 2009;**36**:1143–9.
44. Reynolds PPM, Heron C, Pilcher J, et al. Prediction of erosion progression using ultrasound in established rheumatoid arthritis: a 2-year follow-up study. *Skeletal Radiol* 2009;**38**:473–478.
45. Stewart A, Mackenzie LM, Black AJ, et al. Predicting erosive disease in rheumatoid arthritis. A longitudinal study of changes in bone density using digital X-ray radiogrammetry:a pilot study. *Rheumatology (Oxford)* 2004;**43**:1561–1564.
46. Tanaka N, Sakahashi H, Ishii S, et al. Synovial membrane enhancement and bone erosion by magnetic resonance imaging for prediction of radiologic progression in patients with early rheumatoid arthritis. *Rheumatol Int* 2005;**25**:103–107.

47. Taylor PC, Steuer A, Gruber J, et al. Comparison of ultrasonographic assessment of synovitis and joint vascularity with radiographic evaluation in a randomized, placebo-controlled study of infliximab therapy in early rheumatoid arthritis. *Arthritis Rheum* 2004;**50**:1107–1116.
48. Zhang J, Redden DT, McGwin G, et al. Generalized bone loss as a predictor of three-year radiographic damage in African American patients with recent-onset rheumatoid arthritis. *Arthritis Rheum* 2010;**62**:2219-2226.

Recommendation 6. Inflammation seen on imaging may be more predictive of a therapeutic response than clinical features of disease activity; imaging may be used to predict response to treatment

1. Ellegaard K, Christensen R, Torp-Pedersen S, et al. Ultrasound Doppler measurements predict success of treatment with anti-TNF- α drug in patients with rheumatoid arthritis: a prospective cohort study. *Rheumatology (Oxford)* 2011;**50**:506-512.
2. Elzinga EH, van der Laken CJ, Comans EFI, et al. ^{18}F -FDG PET as a tool to predict the clinical outcome of infliximab treatment of rheumatoid arthritis: an explorative study. *J Nucl Med* 2011;**52**:77–80.

Recommendation 7. Given the improved detection of inflammation by MRI and US than by clinical examination, they may be useful in monitoring disease activity

1. Bruyn GAW, Naredo E, Möller I, et al. Reliability of ultrasonography in detecting shoulder disease in patients with rheumatoid arthritis. *Ann Rheum Dis* 2009;**68**:357–361.
2. Calisir C, Murat Aynaci AI, Korkmaz C. The accuracy of magnetic resonance imaging of the hands and feet in the diagnosis of early rheumatoid arthritis. *Joint Bone Spine*

2007;**74**:362-7.

3. Ejbjerg BJ, Narvestad E, Jacobsen S, et al. Optimised, low cost, low field dedicated extremity MRI is highly specific and sensitive for synovitis and bone erosions in rheumatoid arthritis wrist and finger joints: Comparison with conventional high field MRI and radiography. *Ann Rheum Dis* 2005;**64**:1280-1287.
4. Freeston JE, Brown AK, Hensor EMA, et al. Extremity magnetic resonance imaging assessment of synovitis (without contrast) in rheumatoid arthritis may be less accurate than power Doppler ultrasound. *Ann Rheum Dis* 2008;**67**:1351.
5. Haavardsholm EA, Østergaard M, Ejbjerg BJ, et al. Reliability and sensitivity to change of the OMERACT rheumatoid arthritis magnetic resonance imaging score in a multireader, longitudinal setting. *Arthritis Rheum* 2005;**52**:3860-3867.
6. Haavardsholm EA, Ostergaard M, Hammer HB, et al. Monitoring anti-TNF alpha treatment in rheumatoid arthritis: responsiveness of magnetic resonance imaging and ultrasonography of the dominant wrist joint compared with conventional measures of disease activity and structural damage. *Ann Rheum Dis* 2009;**68**:1572-1579.
7. Hermann K-GA, Backhaus M, Schneider U, et al. Rheumatoid arthritis of the shoulder joint comparison of conventional radiography, ultrasound, and dynamic contrast-enhanced magnetic resonance imaging. *Arthritis Rheum* 2003;**48**:3338–3349.
8. Horikoshi M, Suzuki T, Sugihara M, et al. Comparison of low-field dedicated extremity magnetic resonance imaging with articular ultrasonography in patients with rheumatoid arthritis. *Mod Rheumatol* 2010;**20**:556-560.
9. Hoving JL, Buchbinder R, Hall S, et al. A Comparison of magnetic resonance imaging, sonography, and radiography of the hand in patients with early rheumatoid arthritis. *J Rheumatol* 2004;**31**:663-675.
10. Klauser A, Demharter J, De Marchi A, et al. Contrast enhanced gray-scale

sonography in assessment of joint vascularity in rheumatoid arthritis: Results from the IACUS study group. *Eur Radiol* 2005;**15**:2404-2410.

11. Naredo E, Möller I, Cruz A, et al. Power Doppler ultrasonographic monitoring of response to anti-tumor necrosis factor therapy in patients with rheumatoid arthritis. *Arthritis Rheum* 2008;**58**:2248-2256.
12. Palosaari K, Vuotila J, Takalo R, et al. Contrast-enhanced dynamic and static MRI correlates with quantitative $^{99}\text{Tc}^{\text{m}}$ -labelled nanocolloid scintigraphy. Study of early rheumatoid arthritis patients. *Rheumatology (Oxford)* 2004;**43**:1364-1373.
13. Scheel AK, Hermann K-GA, Kahler E, et al. A novel ultrasonographic synovitis scoring system suitable for analyzing finger joint inflammation in rheumatoid arthritis. *Arthritis Rheum* 2005;**52**:733–743.
14. Schirmer C, Scheel AK, Althoff CE, et al. Diagnostic quality and scoring of synovitis, tenosynovitis and erosions in low-field MRI of patients with rheumatoid arthritis: A comparison with conventional MRI. *Ann Rheum Dis* 2007;**66**:522-529.
15. Szkudlarek M, Court-Payen M, Strandberg C, et al. Power Doppler ultrasonography for assessment of synovitis in the metacarpophalangeal joints of patients with rheumatoid arthritis: a comparison with dynamic magnetic resonance imaging. *Arthritis Rheum* 2001;**44**:2018-2023.
16. Szkudlarek M, Narvestad E, Klarlund, M et al. Ultrasonography of the metatarsophalangeal joints in rheumatoid arthritis: Comparison with magnetic resonance imaging, conventional radiography, and clinical examination. *Arthritis Rheum* 2004;**50**:2103-2112.
17. Szkudlarek M, Jensen K, Thomsen H, et al. Ultrasonography of the metacarpophalangeal and proximal interphalangeal joints in rheumatoid arthritis: a comparison with magnetic resonance imaging, conventional radiography and clinical examination. *Arthritis Res Ther* 2006;**8**:R52.

18. Taouli B, Zaim S, Peterfy CG, et al. Rheumatoid arthritis of the hand and wrist: comparison of three imaging techniques. *AJR Am J Roentgenol* 2004;**182**:937–943.
19. Terslev L, von der Recke P, Savnik A, et al. Diagnostic sensitivity and specificity of Doppler ultrasound in rheumatoid arthritis. *J Rheumatol* 2008;**35**:49-53.
20. Wakefield RJ, O'Connor PJ, Conaghan PG, et al. Finger tendon disease in untreated early rheumatoid arthritis: a comparison of ultrasound and magnetic resonance imaging. *Arthritis Care Res* 2007;**57**:1158-1164.
21. Wakefield RJ, Freeston JE, O'Connor P, et al. The optimal assessment of the rheumatoid arthritis hindfoot: a comparative study of clinical examination, ultrasound and high field MRI. *Ann Rheum Dis* 2008;**67**:1678-1682.
22. Wamser G, Bohndorf K, Vollert K, et al. Power Doppler sonography with and without echo-enhancing contrast agent and contrast-enhanced MRI for the evaluation of rheumatoid arthritis of the shoulder joint: differentiation between synovitis and joint effusion. *Skeletal Radiol* 2003;**32**:351–359.
23. Ziswiler HR, Aeberli D, Villier PM, et al. High-resolution ultrasound confirms reduced synovial hyperplasia following rituximab treatment in rheumatoid arthritis. *Rheumatology (Oxford)* 2009;**48**:939-943.

Recommendation 8. The periodic evaluation of joint damage, usually by radiographs of the hands and feet, should be considered. MRI (and possibly US) is more responsive to change in joint damage and can be used to monitor disease progression

1. Alasaarela E, Suramo I, Tervonen O, et al. Evaluation of humeral head erosions in rheumatoid arthritis: a comparison of ultrasonography, magnetic resonance imaging, computed tomography and plain radiography. *Br J Rheumatol* 1998;**37**:1152-6.

2. Bajaj S, Lopez-Ben R, Oster R, Alarcón GS. Ultrasound detects rapid progression of erosive disease in early rheumatoid arthritis: a prospective longitudinal study. *Skeletal Radiol* 2007;**36**:123–128.
3. Beltran J, Caudill JL, Herman LA, et al. Rheumatoid Arthritis: MR imaging manifestations. *Radiology* 1987;**165**:153-157.
4. Bird P, Kirkham B, Portek I, et al. Documenting damage progression in a two-year longitudinal study of rheumatoid arthritis patients with established disease (the DAMAGE study cohort): is there an advantage in the use of magnetic resonance imaging as compared with plain radiography? *Arthritis Rheum* 2004;**50**:1383–1389.
5. Böttcher J, Pfeil A, Heinrich B, et al. Digital radiogrammetry as a new diagnostic tool for estimation of disease-related osteoporosis in rheumatoid arthritis compared with pQCT. *Rheumatol Int* 2005;**25**:457–464.
6. Böttcher J, Pfeil A, Mentzel H, et al. Peripheral bone status in rheumatoid arthritis evaluated by digital X-ray radiogrammetry and compared with multisite quantitative ultrasound. *Calcif Tissue Int* 2006;**78**:25-34.
7. Bruyn GAW, Naredo E, Möller I, et al. Reliability of ultrasonography in detecting shoulder disease in patients with rheumatoid arthritis. *Ann Rheum Dis* 2009;**68**:357–361.
8. Calisir C, Murat Aynaci AI, Korkmaz C. The accuracy of magnetic resonance imaging of the hands and feet in the diagnosis of early rheumatoid arthritis. *Joint Bone Spine* 2007;**74**:362-7.
9. Canella C, Philippe P, Pansini V, et al. Use of tomosynthesis for erosion evaluation in rheumatoid arthritic hands and wrists. *Radiology* 2010;**258**:199-205.
10. Ciechomska A, Andrysiak R, Serafin-Król M, et al. Ultrasonography, magnetic resonance imaging and conventional radiography of bone erosions in rheumatoid

arthritis - a comparative study. *Reumatologia* 2005;**43**:301-309.

11. Corvetta A, Giovagnoni A, Baldelli S, et al. MR imaging of rheumatoid hand lesions: comparison with conventional radiology in 31 patients. *Clin Exp Rheumatol* 1992;**10**:217-222.
12. Døhn UM, Ejbjerg BJ, Court-Payen M, et al. Are bone erosions detected by magnetic resonance imaging and ultrasonography true erosions? A comparison with computed tomography in rheumatoid arthritis metacarpophalangeal joints. *Arthritis Res Ther* 2006;**8**:R110.
13. Døhn UM, Ejbjerg BJ, Hasselquist M, et al. Rheumatoid arthritis bone erosion volumes on CT and MRI: reliability and correlations with erosion scores on CT, MRI and radiography. *Ann Rheum Dis* 2007;**66**:1388–1392.
14. Døhn UM, Ejbjerg BJ, Hasselquist M, et al. Detection of bone erosions in rheumatoid arthritis wrist joints with magnetic resonance imaging, computed tomography and radiography. *Arthritis Res Ther* 2008;**10**:R25.
15. Duer-Jensen A, Vestergaard A, Døhn UM, et al. Detection of rheumatoid arthritis bone erosions by two different dedicated extremity MRI units and conventional radiography. *Ann Rheum Dis* 2008;**67**:998-1003.
16. Dohn UM, Ejbjerg B, Boonen A, et al. No overall progression and occasional repair of erosions despite persistent inflammation in adalimumab-treated rheumatoid arthritis patients: Results from a longitudinal comparative MRI, ultrasonography, CT and radiography study. *Ann Rheum Dis* 2011;**70**:252-258.
17. Ejbjerg BJ, Narvestad E, Jacobsen S, et al. Optimised, low cost, low field dedicated extremity MRI is highly specific and sensitive for synovitis and bone erosions in rheumatoid arthritis wrist and finger joints: Comparison with conventional high field MRI and radiography. *Ann Rheum Dis* 2005;**64**:1280-1287.

18. Ejbjerg BJ, Vestergaard A, Jacobsen S, et al. The smallest detectable difference and sensitivity to change of magnetic resonance imaging and radiographic scoring of structural joint damage in rheumatoid arthritis finger, wrist, and toe joints a comparison of the OMERACT rheumatoid arthritis magnetic resonance imaging score applied to different joint combinations and the Sharp/van der Heijde radiographic score. *Arthritis Rheum* 2005;**52**:2300–2306.
19. Forslind K, Johanson A, Larsson EM et al. Magnetic resonance imaging of the fifth metatarsophalangeal joint compared with conventional radiography in patients with early rheumatoid arthritis. *Scand J Rheumatol* 2003;**32**:131-137.
20. Forslind K, Larsson EM, Eberhardt K, et al. Magnetic resonance imaging of the knee: a tool for prediction of joint damage in early rheumatoid arthritis? *Scand J Rheumatol* 2004;**33**:154–161.
21. Freeston JE, Conaghan PG, Dass S, et al. Does extremity-MRI improve erosion detection in severely damaged joints? A study of long-standing rheumatoid arthritis using three imaging modalities. *Ann Rheum Dis* 2007;**66**:1538-1540.
22. Gaylis NB, Needell SD, Rudensky D, et al. Comparison of in-office magnetic resonance imaging versus conventional radiography in detecting changes in erosions after one year of infliximab therapy in patients with rheumatoid arthritis. *Mod Rheumatol* 2007;**17**:273-278.
23. Gill G, Chary-Valckenaere I, Sommier J-P, et al. Is ultrasonography a useful, reproducible and relevant tool to assess erosion progression in rheumatoid arthritis? (abstract). *Arthritis Rheum* 2009;**60 Suppl 10**:1455.
24. Haavardsholm EA, Østergaard M, Ejbjerg BJ, et al. Reliability and sensitivity to change of the OMERACT rheumatoid arthritis magnetic resonance imaging score in a multireader, longitudinal setting. *Arthritis Rheum* 2005;**52**:3860-3867.

25. Haugeberg G, Green MJ, Conaghan PG, et al. Hand bone densitometry: a more sensitive standard for the assessment of early bone damage in rheumatoid arthritis. *Ann Rheum Dis* 2007;**66**:1513–1517.
26. Hermann K-GA, Backhaus M, Schneider U, et al. Rheumatoid arthritis of the shoulder joint comparison of conventional radiography, ultrasound, and dynamic contrast-enhanced magnetic resonance imaging. *Arthritis Rheum* 2003;**48**:3338–3349.
27. Hoff M, Haugeberg G, Kvien TK. Hand bone loss as an outcome measure in established rheumatoid arthritis: 2-year observational study comparing cortical and total bone loss. *Arthritis Res Ther* 2007;**9**:R81.
28. Hoving JL, Buchbinder R, Hall S, et al. A Comparison of magnetic resonance imaging, sonography, and radiography of the hand in patients with early rheumatoid arthritis. *J Rheumatol* 2004;**31**:663-675.
29. Jensen T, Klarlund M, Hansen M, et al. Bone loss in unclassified polyarthritis and early rheumatoid arthritis is better detected by digital x ray radiogrammetry than dual x ray absorptiometry: relationship with disease activity and radiographic outcome. *Ann Rheum Dis* 2004;**63**:15-22.
30. Jensen T, Hansen M, Jensen KE, et al. Comparison of dual X-ray absorptiometry (DXA), digital X-ray radiogrammetry (DXR), and conventional radiographs in the evaluation of osteoporosis and bone erosions in patients with rheumatoid arthritis. *Scand J Rheumatol* 2005;**34**:27–33.
31. Klocke R, Glew D, Cox N, et al. Sonographic erosions of the rheumatoid little toe. *Ann Rheum Dis* 2001;**60**:896.
32. Klarlund M, Østergaard M, Gideon P, et al. Wrist and finger joint MR imaging in rheumatoid arthritis. *Acta Radiol* 1999;**40**:400-409.
33. Lerch K, Borisch N, Paetzel C, et al. Sonographic evaluation of the elbow in

rheumatoid arthritis: a classification of joint destruction. *Ultrasound Med Biol* 2003;**29**:1131–1135.

34. Lillegraven S, Boyesen P, Østergaard M, et al. MRI and X-Ray measured changes in joint space narrowing are closely associated in early RA patients: a pilot study (abstract). *Arthritis Rheum* 2010;**62 Suppl 10**:132.
35. Lindqvist E, Jonsson K, Saxne T et al. Course of radiographic damage over 10 years in a cohort with early rheumatoid arthritis. *Ann Rheum Dis* 2003;**62**:611–616.
36. Lopez-Ben R, Bernreuter WK, Moreland LW, et al. Ultrasound detection of bone erosions in rheumatoid arthritis: a comparison to routine radiographs of the hands and feet. *Skeletal Radiol* 2004;**33**:80–84.
37. Magnani M, Salizzoni E, Mulè R, et al. Ultrasonography detection of early bone erosions in the metacarpophalangeal joints of patients with rheumatoid arthritis. *Clin Exp Rheumatol* 2004;**22**:743-748.
38. McQueen FM, Stewart N, Crabbe J, et al. Magnetic resonance imaging of the wrist in early rheumatoid arthritis reveals a high prevalence of erosions at four months after symptom onset. *Ann Rheum Dis* 1998;**57**:350-356.
39. Østergaard M, Hansen M, Stoltenberg M, et al. New radiographic bone erosions in the wrists of patients with rheumatoid arthritis are detectable with magnetic resonance imaging a median of two years earlier. *Arthritis Rheum* 2003;**48**:2128-2131.
40. Østergaard M, Døhn UM, Duer-Jensen A, et al. Patterns of magnetic resonance imaging bone erosion in rheumatoid arthritis — which bones are most frequently involved and show the most change? *J Rheumatol* 2011;**38**:2014–17.
41. Paimela L, Laasonen L, Helve T, et al. Comparison of the original and the modified Larsen methods and the sharp method in scoring radiographic progression in early rheumatoid arthritis. *J Rheumatol* 1998;**25**:1063-1066.

42. Perry D, Stewart N, Benton N, et al. detection of erosions in the rheumatoid hand; a comparative study of multidetector computerized tomography versus magnetic resonance scanning. *J Rheumatol* 2005;**32**:256–67.
43. Poleksic L, Zdravkovic D, Jablanovic D, et al. Magnetic resonance imaging of bone destruction in rheumatoid arthritis: comparison with radiography. *Skeletal Radiol* 1993;**22**:577-580.
44. Rahmani M, Chegini H, Najafizadeh SR, et al. Detection of bone erosion in early rheumatoid arthritis: Ultrasonography and conventional radiography versus non-contrast magnetic resonance imaging. *Clinical Rheumatol* 2010;**29**:883-891.
45. Scheel AK, Hermann K-GA, Ohrndorf S, et al. Prospective 7 year follow up imaging study comparing radiography, ultrasonography, and magnetic resonance imaging in rheumatoid arthritis finger joints. *Ann Rheum Dis* 2006;**65**:595-600.
46. Schirmer C, Scheel AK, Althoff CE, et al. Diagnostic quality and scoring of synovitis, tenosynovitis and erosions in low-field MRI of patients with rheumatoid arthritis: A comparison with conventional MRI. *Ann Rheum Dis* 2007;**66**:522-529.
47. Sheane BJ, Beddy P, O'Connor M, et al. Targeted ultrasound of the fifth metatarsophalangeal joint in an early inflammatory arthritis cohort. *Arthritis Care Res* 2009;**61**:1004-1008.
48. Szkudlarek M, Narvestad E, Klarlund, M et al. Ultrasonography of the metatarsophalangeal joints in rheumatoid arthritis: Comparison with magnetic resonance imaging, conventional radiography, and clinical examination. *Arthritis Rheum* 2004;**50**:2103-2112.
49. Szkudlarek M, Jensen K, Thomsen H, et al. Ultrasonography of the metacarpophalangeal and proximal interphalangeal joints in rheumatoid arthritis: a comparison with magnetic resonance imaging, conventional radiography and clinical examination. *Arthritis Res Ther* 2006;**8**:R52.

50. Swen WAA, Jacobs JWG, Hubach, PCG, et al. Comparison of sonography and magnetic resonance imaging for the diagnosis of partial tears of finger extensor tendons in rheumatoid arthritis. *Rheumatology (Oxford)* 2000;**39**:55-62.
51. Taouli B, Zaim S, Peterfy CG, et al. Rheumatoid arthritis of the hand and wrist: comparison of three imaging techniques. *AJR Am J Roentgenol* 2004;**182**:937–943.
52. Tonolli-Serabian I, Poet JL, Dufour M, et al. Magnetic resonance imaging of the wrist in rheumatoid arthritis: comparison with other inflammatory joint diseases and control subjects. *Clin Rheumatol* 1996;**15**:137-142.
53. Wakefield RJ, Gibbon WW, Conaghan PG, et al. The value of sonography in the detection of bone erosions in patients with rheumatoid arthritis: A comparison with conventional radiography. *Arthritis Rheum* 2000;**43**:2762-2770.
54. Weidekamm C, Køller M, Weber M, et al. Diagnostic value of high-resolution B-mode and Doppler sonography for imaging of hand and finger joints in rheumatoid arthritis. *Arthritis Rheum* 2003;**48**:325-333.

Recommendation 9. Monitoring of functional instability of the cervical spine by lateral radiograph obtained in flexion and neutral should be performed in patients with clinical suspicion of cervical involvement. When the radiograph is positive or specific neurological symptoms and signs are present, MRI should be performed

1. Fezoulidis I, Neuhold A, Wicke L, et al. Diagnostic imaging of the occipito-cervical junction in a patients with rheumatoid arthritis. *Eur J Radiol* 1989;**9**:5-11.
2. Jacobsen EA, Riise T. MRI of cervical spine with flexion and extension used in patients with rheumatoid arthritis. *Scand J Rheumatol* 2000;**29**:249-54.
3. Karhu JO, Parkkola RK, Koskinen SK. Evaluation of flexion/extension of the upper cervical spine in patients with rheumatoid arthritis: an MRI study with a dedicated

- positioning device compared to conventional radiographs. *Acta Radiol* 2005;**46**:55-66.
4. Kauppi M, Neva MH. Sensitivity of lateral view cervical spine radiographs taken in the neutral position in atlantoaxial subluxation in rheumatic diseases. *Clin Rheumatol* 1998;**17**:511-514.
 5. Oostveen JCM, Roozeboom AR, van de Laar MAFJ, et al. Functional turbo spin echo magnetic resonance imaging versus tomography for evaluating cervical spine involvement in rheumatoid arthritis. *Spine* 1998;**23**:1237-1244.
 6. Reijnierse M, Breedveld FC, Kroon HM, et al. Are magnetic resonance flexion views useful in evaluating the cervical spine of patients with rheumatoid arthritis? *Skeletal Radiol* 2000;**29**:85–89.
 7. Richards JS, Kerr GS, Nashel DJ. Odontoid erosions in rheumatoid arthritis: utility of the open mouth view. *J Clin Rheumatol* 2000;**6**:309-312.
 8. Shimada H, Abematsu M, Ishiso Y, et al. Classification of odontoid destruction in patients with rheumatoid arthritis using reconstructed computed tomography: reference to vertical migration. *J Rheumatol* 2011;**38**:863–867.
 9. Stiskal MA, Neuhold A, Szolar OH, et al. Rheumatoid arthritis of the craniocervical region by MR imaging: detection and characterization. *AJR Am J Roentgenol* 1995;**165**:585-592.
 10. Younes M, Belghali S, Kriâa S, et al. Compared imaging of the rheumatoid cervical spine: prevalence study and associated factors. *Joint Bone Spine* 2009;**76**:361-368.
 11. Yurube T, Sumi M, Nishida K, et al. Progression of cervical spine instabilities in rheumatoid arthritis: a prospective cohort study of outpatients over 5 years. *Spine* 2011;**36**:647–653.
 12. Aisen AM, Martel W, Ellis JH, et al. Cervical spine involvement in rheumatoid arthritis: MR imaging. *Radiology* 1987;**165**:159-163.

13. Reijnierse M, Dijkmans BA, Hansen B, et al. Neurologic dysfunction in patients with rheumatoid arthritis of the cervical spine. Predictive value of clinical, radiographic and MR imaging parameters. *Eur Radiol* 2001;**11**:467-73.

Recommendation 10. MRI and US can detect inflammation that predicts subsequent joint damage, even when clinical remission is present and can be used to assess persistent inflammation

1. Brown AK, Quinn MA, Karim Z, et al. Presence of significant synovitis in rheumatoid arthritis patients with disease-modifying antirheumatic drug-induced clinical remission: evidence from an imaging study may explain structural progression. *Arthritis Rheum* 2006;**54**:3761–3773.
2. Brown AK, Conaghan PG, Karim Z, et al. An explanation for the apparent dissociation between clinical remission and continued structural deterioration in rheumatoid arthritis. *Arthritis Rheum* 2008;**58**:2958–2967.
3. Cimmino MA, Innocenti S, Livrone F, et al. Dynamic gadolinium-enhanced magnetic resonance imaging of the wrist in patients with rheumatoid arthritis can discriminate active from inactive disease. *Arthritis Rheum* 2003;**48**:1207–1213.
4. Gandjbakhch F, Conaghan PG, Ejbjerg B, et al. Synovitis and osteitis are very frequent in rheumatoid arthritis clinical remission: results from an MRI study of 294 patients in clinical remission or low disease activity state. *J Rheumatol* 2011;**38**:2039–44.
5. Lillegraven S, Prince FHM, Shadick NA, et al. Remission and radiographic outcome in rheumatoid arthritis: application of the 2011 ACR/EULAR remission criteria in an observational cohort. *Ann Rheum Dis* 2012;**71**:681-6.
6. Mäkinen H, Kautiainen H, Hannonen P, et al. Sustained remission and reduced radiographic progression with combination disease modifying antirheumatic drugs in early rheumatoid arthritis. *J Rheumatol* 2007;**34**:316–21.

7. Molenaar ETH, Voskuyl AE, Dinant HJ, et al. Progression of radiologic damage in patients with rheumatoid arthritis in clinical remission. *Arthritis Rheum* 2004;**50**:36–42.
8. Ozgocmen S, Ozdemir H, Kiris A, et al. Clinical evaluation and power Doppler sonography in rheumatoid arthritis: evidence for ongoing synovial inflammation in clinical remission. *South Med J* 2008;**101**:240-245.
9. Peluso G, Michelutti A, Bosello S, et al. Clinical and ultrasonographic remission determines different chances of relapse in early and long standing rheumatoid arthritis. *Ann Rheum Dis* 2011;**70**:172–175.
10. Saleem B, Brown AK, Keen H, et al. Should imaging be a component of rheumatoid arthritis remission criteria? A comparison between traditional and modified composite remission scores and imaging assessments. *Ann Rheum Dis* 2011;**70**:792–798.
11. Scirè CA, Montecucco C, Codullo V, et al. Ultrasonographic evaluation of joint involvement in early rheumatoid arthritis in clinical remission: power Doppler signal predicts short-term relapse. *Rheumatology (Oxford)* 2009;**48**:1092–1097.
12. Tishler M, Lysy O, Levy O, et al. ^{99m}Tc-albumin nanocolloid joint scintigraphy in rheumatoid arthritis patients who are in clinical remission – is remission real? *Clin Exp Rheumatol* 2010;**28**:360-364.
13. Varsamidis K, Varsamidou E, Tjetjis V, et al. Doppler sonography in assessing disease activity in rheumatoid arthritis. *Ultrasound Med Biol* 2005;**31**:739–743.
14. Wakefield RJ, Freeston JE, Hensor EMA, et al. Delay in imaging versus clinical response: a rationale for prolonged treatment with anti-tumor necrosis factor medication in early rheumatoid arthritis. *Arthritis Rheum* 2007;**57**:1564–1567.