

I. Characteristics of radio-isotopes and considerations involved in their use

CHAIRMAN: DR. NORMAN VEALL

Early studies of ^{198}Au in the treatment of synovitis of the knee

B. M. ANSELL

Medical Research Council Rheumatism Research Unit, Canadian Red Cross Memorial Hospital, Taplow, Berks.

The possibility of treating persistent knee effusion by radiation synovectomy was first considered in 1958. It was thought that colloidal gold ^{198}Au , when injected into the knee joint, would behave like other particles and localize in the synovial membrane, and that having a half life of 2.7 days and a range of approximately 1 mm. it could destroy the superficial layers of the synovium. An initial pilot study, undertaken to ascertain that the ^{198}Au would diffuse satisfactorily through the knee, showed that at 48 hours there was very little radioactivity in the synovial fluid and that an autoradiograph of a needle biopsy showed satisfactory localization of gold in the surface cells. Tracer doses put into knees before synovectomy and the synovial tissue collected at surgery showed that approximately 80 per cent. of the injected dose could be subsequently detected in the tissue removed. Using a 50 μCi . dose, no wide spread into the lymph glands, etc., was detected. The first therapeutic study began with attempts to make a rough estimate of the volume of the effusion by measuring the circumference of the knee and then aspirating to dryness; this also allowed an assessment of the severity of the soft tissue swelling. When the knee had returned to approximately the same circumference, the dose of radioactive gold, individually estimated to give a dose of 600 to 800 r to the expected surface of that volume, was injected. This method was cumbersome and probably quite inaccurate because of villus formation, so that a standard dosage was later used. In general, those patients with a marked effusion and only relatively little soft tissue swelling did best (Ansell, Crook, Mallard, and Bywaters, 1963).

A comparison of bilateral knee effusions 1 year after treatment, when one knee only had received the active preparation and the other a placebo, showed that there had been a better clinical effect on the treated side (Table).

Table State of bilateral knee effusions 1 year after ^{198}Au was injected into one

Knee	Effusion		
	None	Smaller	No change
Treated	10	1	3
Control	4	2	8

One patient who had had an excellent result from an injection of radioactive gold just over 1 year before and was awaiting treatment for the other knee died from a massive cardiac infarction. The untreated knee was compared histologically with the treated knee (Figs 1 and 2, overleaf). There was reduction in thickness in the synovial membrane, loss of inflammatory cells, and fibrosis affecting the blood vessels on the treated side. This pattern was noted in serial needle biopsies in other patients who had had a good clinical result.

It is 10 years since our work was published and there have since been many changes, especially in the availability of radiocolloids for intra-articular therapy.

The purpose of today's Symposium is to share our knowledge and to examine methods of minimizing the potential hazards of this treatment.

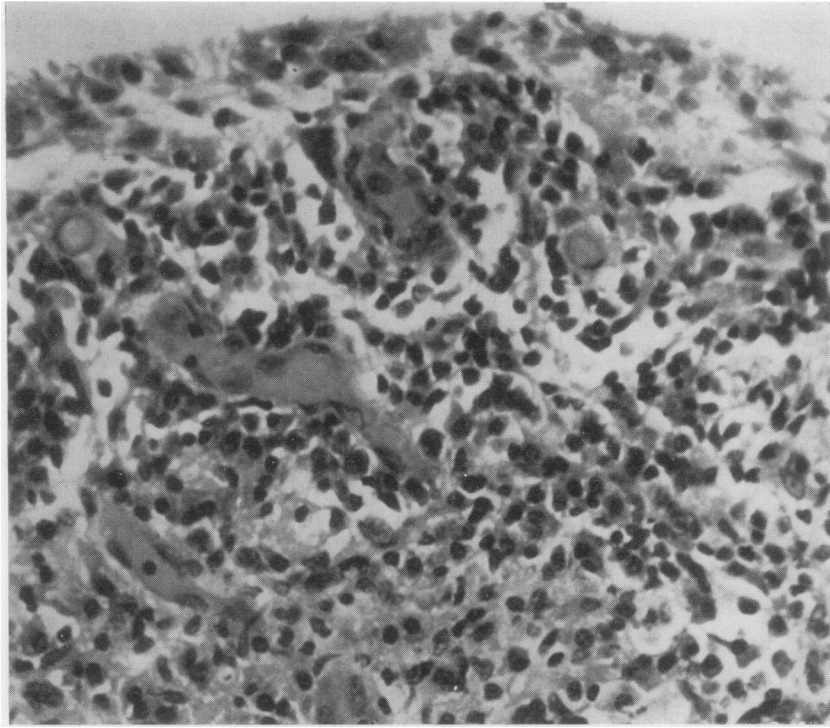


FIG. 1 *Untreated knee. Active synovitis. Many inflammatory cells and general hyperaemia. ×400*

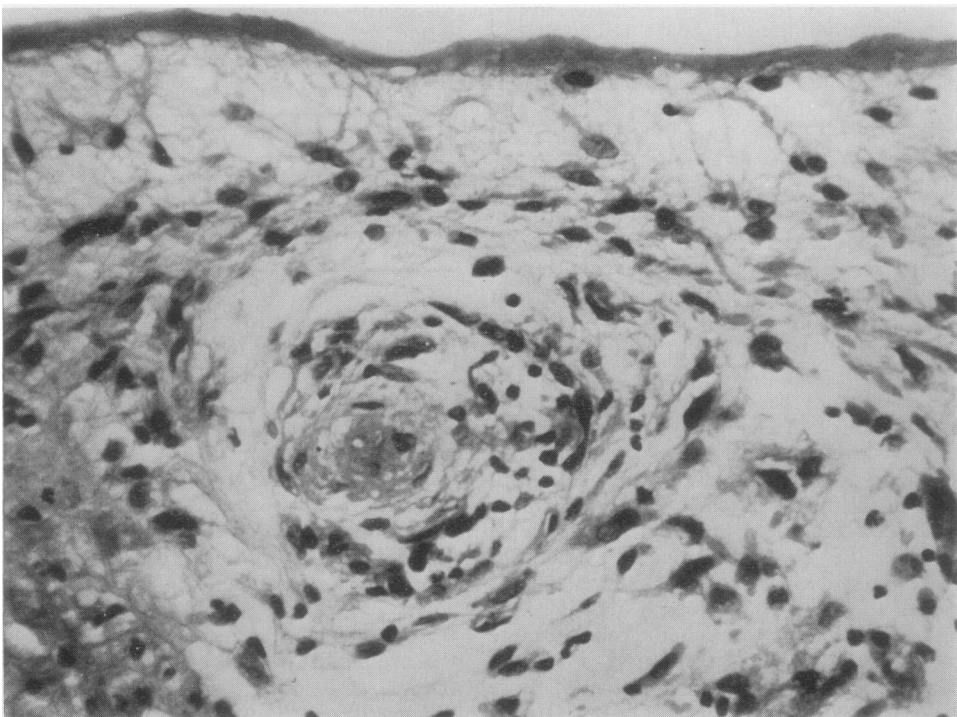


FIG. 2 *Treated knee after just over one year. Loss of inflammatory cells. Obliteration of blood vessel with surrounding fibrosis, thinning, and consolidation of surface layer. ×400*